



## Current Concepts Review

## Rebranding the ‘anatomic’ ACL reconstruction: Current concepts

Kyle A. Borque<sup>a,\*</sup>, Mitzi S. Laughlin<sup>b</sup>, Vítor Hugo Pinheiro<sup>c</sup>, Mary Jones<sup>d</sup>, Andy Williams<sup>d</sup><sup>a</sup> Houston Methodist Hospital, Houston, TX, 77479, USA<sup>b</sup> Houston Methodist Research Institute, Houston, TX, 77030, USA<sup>c</sup> Centro Hospitalar e Universitário de Coimbra, Coimbra, 3004-561, Portugal<sup>d</sup> Fortius Clinic, FIFA Medical Centre of Excellence, London, W1H 6EQ, UK

## ARTICLE INFO

## Keywords:

Anterior cruciate ligament reconstruction

ACL

Anatomic ACL reconstruction

## ABSTRACT

The anterior cruciate ligament (ACL) is a complex ribbon-like structure, which is approximately 3.5 times larger at the tibial and femoral insertions than at the midpoint. Accordingly, it is impossible to recreate with a single cylindrical graft. However, this has not stopped surgeons from using the term “anatomic” to describe multiple ACL reconstruction techniques inserting at a number of different locations within the original ACL footprint, causing confusion. The term “anatomic” should be discarded and replaced by an anatomic description of the tunnel placements on the tibia and femur. Current ACL reconstruction techniques cite anatomical studies that identified “direct and indirect fibres” of the ACL. The “direct fibres” bear 85–95% of the load and provide the main resistance to both anterior tibial translation and internal rotation/pivot shift. On the femur, these fibres insert in a line just posterior to the intercondylar ridge and comprise the portion of the ACL that surgeons should strive to restore. Placement of the graft just posterior to the intercondylar ridge creates a line of placement options from the anteromedial bundle to the “central” position and finally to the posterolateral bundle position. The authors prefer placing the femoral tunnel in the isometric anteromedial position and addressing a high-grade pivot shift at the IT-band with a lateral extra-articular tenodesis. As with the femoral tunnel, the native ACL footprint on the tibia is much larger than the ACL graft and thus can be placed in multiple “anatomic” locations. The authors prefer placement of the tibial tunnel in the anterior most position of the native footprint that does not cause impingement in the femoral notch. Additional research is needed to determine the ideal tunnel positions on the femur and tibia and validating the technique with patient outcomes. However, this cannot be accomplished without describing tunnel placement with specific anatomical locations so other surgeons can replicate the technique.

## Current concepts

- In the last 100 years, multiple reconstruction constructs have been proposed in an effort to mimic the complex ribbon-like structure of the anterior cruciate ligament (ACL).
- Many of these ACL reconstruction techniques have been termed “anatomic”, in an effort to imply superiority to other techniques, while ignoring the impossibility of recreating a structure that is 3.5 times wider at its bony insertions than its centre with a single strand graft.
- Using the term “anatomic” is vague, as any graft placed within the tibial and femoral footprints could be considered “anatomic”, and should be avoided in favor of more specific description of tunnel placement. This will allow for more accurate reproduction and evaluation of the technique by other surgeons.
- The authors prefer placing the femoral tunnel in the anteromedial bundle position (which is both anatomic and

isometric) and the tibial tunnel in the centre of the native footprint. They choose to address a high-grade pivot shift at the location of the pathology (the ITB) with a lateral extra-articular tenodesis.

## Future perspectives

- Descriptions of ACL reconstruction techniques should not be simply described as “anatomic” rather the surgeons should identify specific anatomical locations for the placement of the tibial and femoral tunnels in sufficient detail to replicate the technique by another surgeon.
- Future studies should validate tunnel placement with patient outcome measures as well as return to play and performance metrics.

\* Corresponding author. Houston Methodist Orthopedics, 16811 Southwest Freeway Sugar Land, TX 77479, USA. Tel.: 1+ 346-371-3550.

E-mail address: [kaborque@gmail.com](mailto:kaborque@gmail.com) (K.A. Borque).

## Introduction

The first described surgical treatment of an anterior cruciate ligament (ACL) injury was an anatomic repair performed in 1895 by Mayo-Robson of Leeds, UK [1]. In 1917, Hey Groves of Bristol, UK, performed the first anterior cruciate ligament reconstruction (ACLR) [2] and since then surgeons have used a variety of intra-articular and extra-articular procedures in an attempt to restore stability to the injured knee [1]. Over this time, debate has revolved around the ideal graft choice, open versus arthroscopic, tunnel placement, graft fixation method, and more recently extra-articular augmentation [3–5] of an intra-articular graft [6,7].

Multiple constructs have been proposed in an effort to mimic the complex ribbon-like structure of the ACL [8]. However, it is impossible to truly recreate a ligament that is 3.5 times larger at its tibial and femoral insertions than its midpoint with a single cylindrical graft [9, 10]. In addition, reconstruction does not restore the intra-articular attachments of the native ACL. Unfortunately, this has not stopped surgeons from using the term “anatomic” to describe their ACLR techniques. Not only is the term “anatomic” inaccurate, but it also suggests the optimal reconstruction and thereby superiority to other techniques. Furthermore, multiple techniques have been described as “anatomic,” thus causing confusion when attempting to interpret outcomes [11–16]. It is for these reasons that the authors feel the term “anatomic” should be avoided in the literature and replaced by an accurate description of the tunnel positions and fixation methods utilized.

## Anatomical reference terms

It is important in all studies to define the terms used to describe the tunnel positions. With the knee flexed approximately 90° for arthroscopy (Fig. 1) and regarding the intercondylar notch, the term “deep” is “proximal” according to anatomical nomenclature and “high” is “anterior” and “low” is “posterior.” To help guide tunnel placement, the “clock-face” concept was popularised with 12 o'clock being the highest/most anterior position in the intercondylar notch, which corresponds to where the vertically aligned lateral edge of the PCL attaches (Fig. 2). While useful, the clock-face concept has been criticised since being two-dimensional it gives no guidance regarding depth (proximo-distal) position of the femoral tunnel [17].

## Relevant history

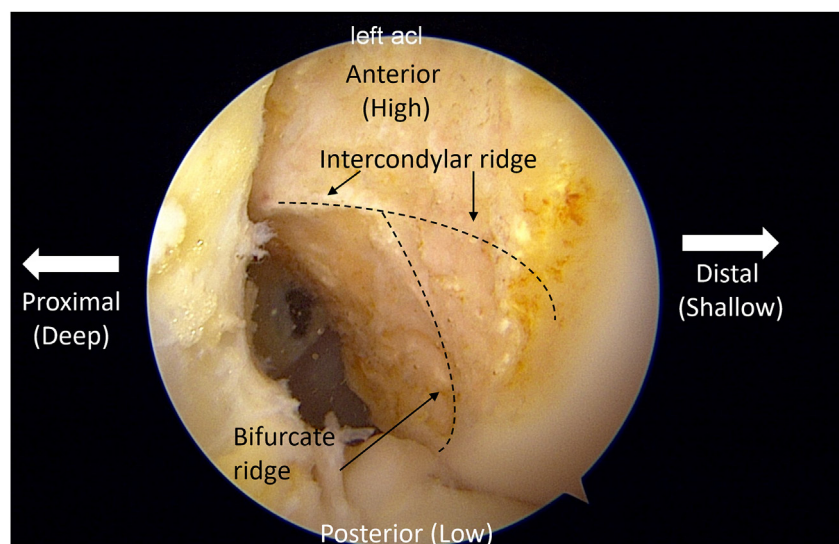
Early arthroscopic ACL reconstruction techniques relied on drill guides positioned to place a guide wire in the tibia in a site that could be “rail-roaded” proximally into the femur so that both tibial and femoral tunnels could be drilled sequentially over the same wire (the transtibial technique). It was thought that with the wire angled 40° to the sagittal tibial slope two well-placed tunnels would result [18,19]. Unfortunately, since the femoral tunnel position was determined by the tibial tunnel position and inclination, it frequently ended up more anterior (higher in the notch) than the native femoral ACL footprint, resulting in compromised rotational stability and increased subsequent medial meniscus injury [19–23].

In the early 2000's fuelled by the improvements in soft tissue knee surgery that had accompanied better understanding of anatomy and the trend to mimic anatomic structures, double-bundle ACL reconstruction techniques were promoted [24–26]. The belief was that the anteromedial bundle (AMB) graft would resist anterior tibial translation (ATT) and the posterolateral bundle (PLB) would resist internal rotation with its bigger lever arm [23,27–29]. Although cadaveric studies suggested a biomechanical advantage [30–35], multiple clinical studies showed a lack of superiority in patient-reported outcomes, pivot shift, or return to play measures [36–40], which prevented the technique from gaining widespread use.

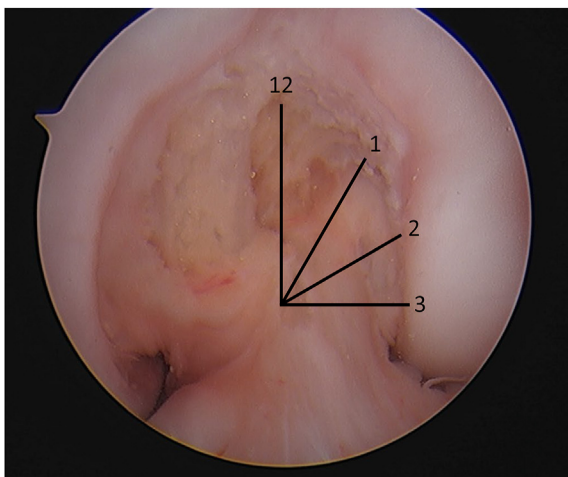
Promoters of the double bundle construct concept then compromised by placing the femoral tunnel for a single bundle construct at the centre of the femoral footprint and termed it “anatomic” or “anatomical” ACL reconstruction [9,41]. The term “anatomic” ACL reconstruction has since been commonly used, frequently without an accompanying technical or anatomical description. Multiple authors have used the term, without clarification, in describing different tunnel locations and even different surgical techniques [42].

## What is “anatomic” on the femur?

The femoral ACL insertion covers a large portion of the lateral wall of the intercondylar notch [43–45], extending posteriorly from the intercondylar ridge to the articular surface. Surgeons must decide where in this large area to place a typical 8–10 mm tunnel in an attempt to restore stability to the knee [46]. This decision can be broken down into two axes referenced by the lateral intercondylar ridge: how far anterior or posterior to the intercondylar ridge and proximal or distal along the ridge [8,



**Fig. 1.** Arthroscopic view of the lateral wall of the intercondylar notch of a left knee as viewed from the anteromedial portal. The lateral intercondylar ridge and lateral bifurcate ridge are denoted by a dashed line. Anterior (high), posterior (low), distal (shallow), and proximal (deep) locations are noted.



**Fig. 2.** Arthroscopic view of the lateral wall of the intercondylar notch of a left knee with overlaid clock face. The native ACL can be seen inserting between 1 and 3 o'clock.

47]. While placing a graft in the centre of the femoral ACL “footprint” may seem logical, it must be acknowledged that this does not recreate the complex native anatomy of the ACL [8–10]. In addition, it is important to note that all tunnel positions that fall within the large footprint of the native ACL could be considered anatomic [11].

Over time, there has been an evolution regarding the ideal position of the femoral tunnel on the clock-face. Original arthroscopic transtibial techniques yielded a femoral tunnel high in the notch resulting in poor rotational control and increased subsequent medial meniscus injuries. This was followed by grafts placed very low (posterior) in the notch, near the articular surface, in an effort to better control rotation. However, this was found to increase the forces on the graft and result in a graft that loosened in flexion and tightened in extension. Multiple recent studies have identified that while the ACL inserts over a large footprint, it does so through two distinct groups of fibres: direct and indirect. The “direct fibres” of the ACL, which insert in a line just posterior to the intercondylar ridge (Fig. 3), bear 85–95% of the load and provide the main resistance to both ATT and the internal rotation/pivot shift [47–50]. This area correlates with the greatest density of collagen fibres as well as the highest tensile strength [51–53]. It is therefore reasonable to conclude

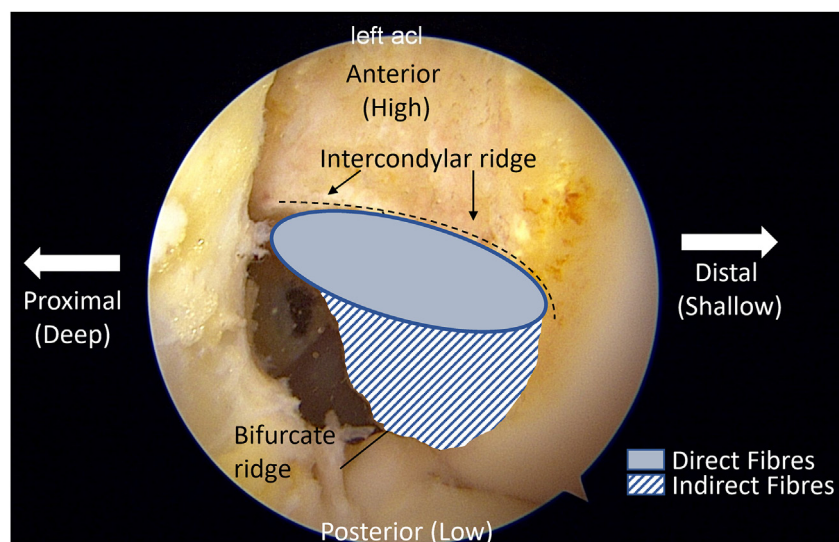
that these direct fibres comprise the portion of the ACL that surgeons should strive to restore.

Acknowledging that the graft should be placed just posterior to the intercondylar ridge leaves a line of possibilities as to where to place the graft: beginning anteriorly and proximally with the AMB position, moving distally and posteriorly to the “central” position and further in the same direction to the PLB position (Fig. 4) [54]. Proponents of the central tunnel position aim to use one cylindrical graft to replicate the complex ribbon-like structure of the native ACL’s anteromedial and PLBs [8].

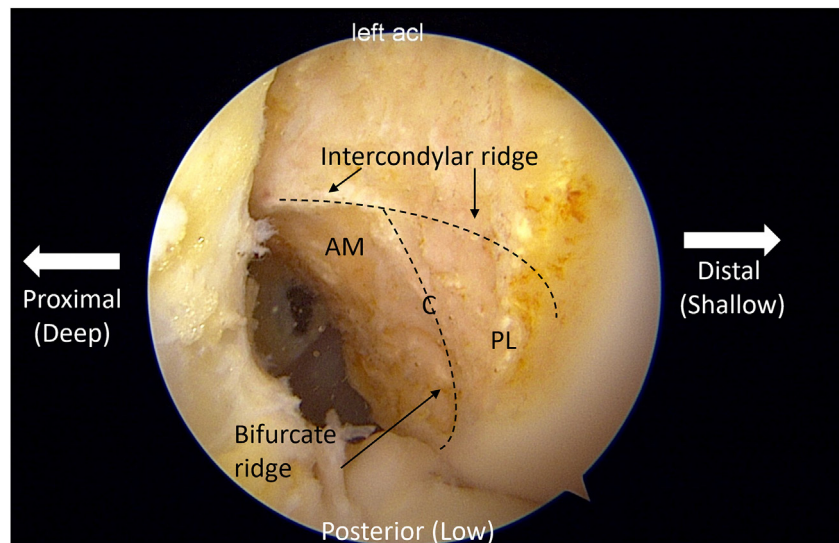
However, some of these same surgeons have shown no difference in time zero stability between the single-bundle AMB position and single-bundle central position [11,55]. Furthermore, Nawabi et al. confirmed prior studies that the direct fibres in the AMB position represent the most isometric fibres of the native ACL [47,48,56–58]. Clinically, there are three reports of an increase in re-rupture rate following a move from an AMB to a central femoral position [3,8,59]. While some may suggest that this is a result of the graft more effectively resisting instability (personal communication with Freddie Fu), another explanation could be the lack of isometry and increased loads of a graft placed in the central position [47]. Finally, surgeons should remember that while the ACL is the primary restraint to ATT throughout range of motion, it is the fibres of the iliotibial band that offer the most resistance to tibial internal rotation and the pivot shift [60], with the ACL only being important in full extension. For these reasons, the authors prefer placing the femoral tunnel in the isometric AMB position [61] (which is anatomic and isometric) choosing to address a high-grade pivot shift at the location of the pathology (the iliotibial band (ITB)) with a lateral extra-articular tenodesis [5].

### What about the tibial tunnel?

While significant attention has been paid to finding the correct femoral tunnel position, the importance of tibial tunnel position is frequently overlooked. Authors frequently report “anatomic” tibial tunnel placement, ignoring the impossibility of recreating the native ACL’s C-shaped insertion around the lateral meniscus anterior root with a single cylindrical tunnel [8,9]. Original transtibial techniques utilized a more posterior tunnel placement, usually at the tibial insertion of the native PLB, to allow access to a more anatomic femoral position [62–64]. This graft alignment (PLB on the tibia to AMB on the femur) was shown to result in a graft 10° more vertical in both the coronal and sagittal plane than the native ACL, compromising both translational and rotational stability [65,66]. With the tibial tunnel placed in the PLB position, it was



**Fig. 3.** Arthroscopic view of the lateral wall of the intercondylar notch of a left knee viewed from the anteromedial portal. Location of the deep fibres is denoted with a solid pattern while the indirect fibres are noted with a diagonal stripe pattern.



**Fig. 4.** Arthroscopic view of the lateral wall of the intercondylar notch of a right knee viewed from the anteromedial portal. The anteromedial bundle position (AM), central position (C), and posterolateral bundle position (PL) are noted.

found that stability was not able to be restored, regardless of the placement of the femoral tunnel. Following this, Bedi et al. showed that a more anteriorly placed tibial tunnel resulted in better control of the Lachman and pivot shift manoeuvres but was careful to note that it carried greater risk of impingement on the femoral notch if placed excessively anterior [63,67–69], which in the clinical setting can block extension or lead to failure of the ACL graft. Recently, Lord et al. confirmed that the native ACL fibres inserting at the tibial AMB position were the primary restraint to ATT, tibial internal rotation, and pivot shift [70]. In the acute setting, the tibial stump is frequently easily identifiable as a guide for placement of the tibial tunnel while anatomic landmarks such as the lateral meniscus or PCL and fluoroscopy can be used in the revision setting or a chronic ACL injury [71–75]. Variation exists among patients, the centre of the tibial tunnel is on average 38–40% posterior to the anterior border of the tibial plateau, with a recent study showing improved stability when the graft was placed anterior to the 40% line [73,76–79].

Consequently, the authors prefer placement of the tibial tunnel in the centre of the native footprint, which does not result in impingement. The effects of varying the tibial tunnel among different “anatomic” positions again highlights the importance of authors providing exact descriptions of their tunnel positions rather than just terming the technique “anatomic.”

#### Peripheral lesions associated with ACL rupture

It has become increasingly evident that the ideal ACL reconstruction is not just about the ACL graft position, fixation, and graft type. At one time undiagnosed posterolateral corner injuries, which increase forces on the ACL graft, were cited as the number one reason for ACL graft failure [80]. Over the past decade, the incidence of anterolateral complex injury in the setting of ACL injury has been shown to be as high as 90% [81–84]. In the setting of combined ACL and anterolateral injury, many cadaveric biomechanical studies have found that ACLR alone cannot restore normal control of the pivot shift [60,85]. These studies concluded that only in full extension is the ACL the primary restraint to internal rotation and the pivot shift, whereas in the flexed knee, it is the deep capsule-osseous layer of the ITB that prevents internal rotation and the pivot shift. Anterolateral procedures such as lateral extra-articular tenodesis and anterolateral ligament reconstruction have shown to be critical in off-loading the ACL graft and restoring rotational stability to the knee [5, 85–89]. More recently, a high incidence of injuries to the medial ligament complex, namely the superficial and deep MCL, has been noted in

the setting of previously assumed “isolated” ACL injuries [90]. Clinical and biomechanical studies have highlighted the importance of addressing these injuries at the time of ACLR [91–93]. Due to this, surgeons must learn to identify and treat many pathologies associated with ACL injury in an attempt to attain the most “anatomic” result.

#### Conclusion

Using the word anatomic to describe an ACL reconstruction technique is vague at best and misleading at worst. The term implies superiority to other “non-anatomic” techniques, while ignoring the fact that no current reconstruction techniques truly recreate the complex anatomy of the ACL. In reality, any graft placed within the large native femoral and tibial footprints could be considered anatomic, thus highlighting the danger of using this term without accurate description on the placement of both the femoral and tibial tunnels.

#### Funding

This research did not receive any specific grant from funding agencies in the public, commercial, or not-for-profit sectors.

#### Declaration of competing interest

The authors declare the following financial interests/personal relationships which may be considered as potential competing interests: Andy Williams reports a relationship with Smith and Nephew Inc that includes: funding grants and non-financial support. Andy Williams reports a relationship with DocComm Inc that includes: equity or stocks. Andy Williams reports a relationship with Innovate that includes: equity or stocks. Kyle Borque reports a relationship with Xiros Ltd that includes: consulting or advisory.

#### References

- [1] Schindler OS. Surgery for anterior cruciate ligament deficiency: a historical perspective. *Knee Surg Sports Traumatol Arthrosc* 2012;20:5–47. <https://doi.org/10.1007/s00167-011-1756-x>.
- [2] Hey-Groves EW. Operation for the repair of crucial ligaments. *Lancet* 1917;190: 674–5. [https://doi.org/10.1016/S0140-6736\(01\)52502-7](https://doi.org/10.1016/S0140-6736(01)52502-7).
- [3] Balendra G, Jones M, Borque KA, Willinger L, Pinheiro VH, Williams A. Factors affecting return to play and graft re-rupture after primary ACL reconstruction in professional footballers. *Knee Surg Sports Traumatol Arthrosc* 2022;30(7):2200–8. <https://doi.org/10.1007/s00167-021-06765-8>.

- [4] Inderhaug E, Williams A. Do we need extra-articular reconstructive surgery? *Clin Sports Med* 2018;37:61–73. <https://doi.org/10.1016/j.csm.2017.07.008>.
- [5] Inderhaug E, Stephen JM, Williams A, Amis AA. Anterolateral tenodesis or anterolateral ligament complex reconstruction: effect of flexion angle at graft fixation when combined with ACL reconstruction. *Am J Sports Med* 2017;45:3089–97. <https://doi.org/10.1177/0363546517724422>.
- [6] Getgood AMJ, Bryant DM, Litchfield R, Heard M, McCormack RG, Rezanoff A, et al. Lateral extra-articular tenodesis reduces failure of hamstring tendon autograft anterior cruciate ligament reconstruction: 2-year outcomes from the STABILITY Study randomized clinical trial. *Am J Sports Med* 2020;48:285–97. <https://doi.org/10.1177/0363546519896333>.
- [7] Getgood A, Spalding T. The evolution of anatomic anterior cruciate ligament reconstruction. *Open Orthop J* 2012;6:287–94. <https://doi.org/10.2174/1874325001206010287>.
- [8] Śmigielski R, Zdanowicz U, Drwi ga M, Ciszek B, Williams A. The anatomy of the anterior cruciate ligament and its relevance to the technique of reconstruction. *Bone Joint J* 2016;98-B:1020–6. <https://doi.org/10.1302/0301-620X.98B8.37117>.
- [9] Harner C, Baek G, Vogrin T, Carlin G, Kashiwaguchi S, Woo S. Quantitative analysis of human cruciate ligament insertions. *Arthroscopy* 1999;15:741–9.
- [10] Thein R, Spitzer E, Doyle J, Khamaisy S, Nawabi DH, Chawla H, et al. The ACL graft has different cross-sectional dimensions compared with the native ACL. *Am J Sports Med* 2016;44:2097–105. <https://doi.org/10.1177/0363546516645531>.
- [11] Cross M, Musahl V, Bedi A, O'Loughlin P, Hammoud S, Suero E, et al. Anteromedial versus central single-bundle graft position: which anatomic graft position to choose? *Knee Surg Sports Traumatol Arthrosc* 2012;20:1276–81. <https://doi.org/10.1007/s00167-011-1737-0>.
- [12] Silva A, Sampaio R, Pinto E. Femoral tunnel enlargement after anatomic ACL reconstruction: a biological problem? *Knee Surg Sports Traumatol Arthrosc* 2010;18:1189–94. <https://doi.org/10.1007/s00167-010-1046-z>.
- [13] van Eck CF, Lesniak BP, Schreiber VM, Fu FH. Anatomic single- and double-bundle anterior cruciate ligament reconstruction flowchart. *Arthroscopy* 2010;26:258–68. <https://doi.org/10.1016/j.arthro.2009.07.027>.
- [14] Pedneault C, Laverdière C, Hart A, Boily M, Burman M, Martineau PA. Evaluating the accuracy of tibial tunnel placement after anatomic single-bundle anterior cruciate ligament reconstruction. *Am J Sports Med* 2019;47:3187–94. <https://doi.org/10.1177/0363546519873633>.
- [15] Hart A, Sivakumaran T, Burman M, Powell T, Martineau PA. A prospective evaluation of femoral tunnel placement for anatomic anterior cruciate ligament reconstruction using 3-dimensional magnetic resonance imaging. *Am J Sports Med* 2018;46:192–9. <https://doi.org/10.1177/0363546517730577>.
- [16] Gabler CM, Jacobs CA, Howard JS, Mattacola CG, Johnson DL. Comparison of graft failure rate between autografts placed via an anatomic anterior cruciate ligament reconstruction technique. *Am J Sports Med* 2016;44:1069–79. <https://doi.org/10.1177/0363546515584043>.
- [17] Azzam M, Lenarz C, Farrow L, Israel H, Kieffer D, SG K. Inter- and intraobserver reliability of the clock face representation as used to describe the femoral intercondylar notch. *Knee Surg Sports Traumatol Arthrosc* 2011;19:1265–70. <https://doi.org/10.1007/s00167-010-1389-5>.
- [18] Kopf S, Forsythe B, Wong AK, Tashman S, Irrgang JJ, Fu FH. Transtibial ACL reconstruction technique fails to position drill tunnels anatomically in vivo 3D CT study. *Knee Surg Sports Traumatol Arthrosc* 2012;20:2200–7. <https://doi.org/10.1007/s00167-011-1851-z>.
- [19] Strauss EJ, Barker JU, McGill K, Cole BJ, Bach BR, Verma NN. Can anatomic femoral tunnel placement be achieved using a transtibial technique for hamstring anterior cruciate ligament reconstruction? *Am J Sports Med* 2011;39:1263–9. <https://doi.org/10.1177/0363546510395488>.
- [20] Lee MC, Seong SC, Lee S, Chang CB, Park YK, Jo H, et al. Vertical femoral tunnel placement results in rotational knee laxity after anterior cruciate ligament reconstruction. *Arthroscopy* 2007;23:771–8. <https://doi.org/10.1016/j.arthro.2007.04.016>.
- [21] Abebe ES, Moorman CT, Dziedzic TS, Spritzer CE, Cothran RL, Taylor DC, et al. Femoral tunnel placement during anterior cruciate ligament reconstruction: an in vivo imaging analysis comparing transtibial and 2-incision tibial tunnel-independent techniques. *Am J Sports Med* 2009;37:1904–11. <https://doi.org/10.1177/0363546509340768>.
- [22] Shin YS, Ro KH, Lee JH, Lee DH. Location of the femoral tunnel aperture in single-bundle anterior cruciate ligament reconstruction: comparison of the transtibial, anteromedial portal, and outside-in techniques. *Am J Sports Med* 2013;41:2533–9. <https://doi.org/10.1177/0363546513500764>.
- [23] Woo SL-Y, Kanamori A, Zeminski J, Yagi M, Papageorgiou C, Fu FH. The effectiveness of reconstruction of the anterior cruciate ligament with hamstrings and patellar tendon. A cadaveric study comparing anterior tibial and rotational loads. *J Bone Joint Surg Am* 2002;84(6):907–14. <https://doi.org/10.2106/00004623-200206000-00003>.
- [24] Zelle BA, Brucker PU, Feng MT, Fu FH. Anatomical double-bundle anterior cruciate ligament reconstruction. *Sports Med* 2006;36:99–108. <https://doi.org/10.2165/00007256-200636020-00001>.
- [25] Yasuda K, Kondo E, Ichihama H, Kitamura N, Tanabe Y, Tohyama H, et al. Anatomic reconstruction of the anteromedial and posterolateral bundles of the anterior cruciate ligament using hamstring tendon grafts. *Arthroscopy* 2004;20:1015–25. <https://doi.org/10.1016/j.arthro.2004.08.010>.
- [26] Pombo MW, Shen W, Fu FH. Anatomic double-bundle anterior cruciate ligament reconstruction: where are we today? *Arthroscopy* 2008;24:1168–77. <https://doi.org/10.1016/j.arthro.2008.05.021>.
- [27] Yagi M, Wong EK, Kanamori A, Debski RE, Fu FH, Woo SLY. Biomechanical analysis of an anatomic anterior cruciate ligament reconstruction. *Am J Sports Med* 2002;30:660–6. <https://doi.org/10.1177/03635465020300050501>.
- [28] Loh JC, Fukuda Y, Tsuda E, Steadman RJ, Fu FH, Woo SLY. Knee stability and graft function following anterior cruciate ligament reconstruction: comparison between 11 o'clock and 10 o'clock femoral tunnel placement. *Arthroscopy* 2003;19:297–304. <https://doi.org/10.1053/jars.2003.50084>.
- [29] Zantop T, Herbort M, Raschke MJ, Fu FH, Petersen W. The role of the anteromedial and posterolateral bundles of the anterior cruciate ligament in anterior tibial translation and internal rotation. *Am J Sports Med* 2007;35:223–7. <https://doi.org/10.1177/0363546506294571>.
- [30] Desai N, Björnsson H, Musahl V, Bhandari M, Petzold M, Fu FH, et al. Anatomic single-versus double-bundle ACL reconstruction: a meta-analysis. *Knee Surg Sports Traumatol Arthrosc* 2014;22:1009–23.
- [31] Kongtharvonskul J, Attia J, Thamakaisan S, Kijjunasathian C, Woratanarat P, Thakintian A. Clinical outcomes of double- vs single-bundle anterior cruciate ligament reconstruction: a systematic review of randomized control trials. *Scand J Med Sci Sports* 2013;23:1–14. <https://doi.org/10.1111/j.1600-0838.2011.01439.x>.
- [32] Lamsam C, Kaewpornsawan K, Luangsa-Ard J, Thephamongkhon K, Vanadurongwan B, Soparat K. Single-bundle versus double-bundle anterior cruciate ligament reconstruction: a meta-analysis. *J Med Assoc Thai* 2012;95:114–21.
- [33] Li YL, Ning GZ, Wu Q, Wu QL, Li Y, Hao Y, et al. Single-bundle or double-bundle for anterior cruciate ligament reconstruction: a meta-analysis. *Knee* 2014;21:28–37. <https://doi.org/10.1016/j.knee.2012.12.004>.
- [34] Mascarenhas R, Cvetanovich GL, Sayegh ET, Verma NN, Cole BJ, Bush-Joseph C, et al. Does double-bundle anterior cruciate ligament reconstruction improve postoperative knee stability compared with single-bundle techniques? A systematic review of overlapping meta-analyses. *Arthroscopy* 2015;31:1185–96. <https://doi.org/10.1016/j.arthro.2014.11.014>.
- [35] Xu M, Gao S, Zeng C, Han R, Sun J, Li H, et al. Outcomes of anterior cruciate ligament reconstruction using single-bundle versus double-bundle technique: meta-analysis of 19 randomized controlled trials. *Arthroscopy* 2013;29:357–65. <https://doi.org/10.1016/j.arthro.2012.08.024>.
- [36] Ahldén M, Sernert N, Karlsson J, Kartus J. A prospective randomized study comparing double- and single-bundle techniques for anterior cruciate ligament reconstruction. *Am J Sports Med* 2013;41:2484–91. <https://doi.org/10.1177/0363546513497926>.
- [37] Liu Y, Cui G, Yan H, Yang Y, Ao Y. Comparison between single- and double-bundle anterior cruciate ligament reconstruction with 6- to 8-stranded hamstring autograft: a prospective, randomized clinical trial. *Am J Sports Med* 2016;44:2314–22. <https://doi.org/10.1177/0363546516650876>.
- [38] Li X, Xu CP, Song JQ, Jiang N, Yu B. Single-bundle versus double-bundle anterior cruciate ligament reconstruction: an up-to-date meta-analysis. *Int Orthop* 2013;37:213–26. <https://doi.org/10.1007/s00264-012-1651-1>.
- [39] Irrgang JJ, Tashman S, Patterson CG, Musahl V, West R, Oostdyk A, et al. Anatomic single vs. double-bundle ACL reconstruction: a randomized clinical trial—Part 1: clinical outcomes. *Knee Surg Sports Traumatol Arthrosc* 2021;29:2665–75. <https://doi.org/10.1007/s00167-021-06585-w>.
- [40] Aga C, Risberg MA, Fagerland MW, Johansen S, Trøan I, Heir S, et al. No difference in the KOOS quality of life subscore between anatomic double-bundle and anatomic single-bundle anterior cruciate ligament reconstruction of the knee: a prospective randomized controlled trial with 2 years' follow-up. *Am J Sports Med* 2018;46:2341–54. <https://doi.org/10.1177/0363546518782454>.
- [41] Fu FH, Karlsson J. A long journey to be anatomic. *Knee Surg Sports Traumatol Arthrosc* 2010;18:1151–3. <https://doi.org/10.1007/s00167-010-1222-1>.
- [42] van Eck CF, Schreiber VM, Mejia HA, Samuelsson K, Van Dijk CN, Karlsson J, et al. Anatomic anterior cruciate ligament reconstruction: a systematic review of surgical techniques and reporting of surgical data. *Arthroscopy* 2010;26:S2–12. <https://doi.org/10.1016/j.arthro.2010.03.005>.
- [43] Kopf S, Musahl V, Tashman S, Szczodry M, Shen W, Fu FH. A systematic review of the femoral origin and tibial insertion morphology of the ACL. *Knee Surg Sports Traumatol Arthrosc* 2009;17:213–9.
- [44] Ferretti M, Ekdahl M, Shen W, Fu FH. Osseous landmarks of the femoral attachment of the anterior cruciate ligament: an anatomic study. *Arthroscopy* 2007;23:1218–25. <https://doi.org/10.1016/j.arthro.2007.09.008>.
- [45] Colombet P, Robinson J, Christel P, Franceschi JP, Djian P, Bellier G, et al. Morphology of anterior cruciate ligament attachments for anatomic reconstruction: a cadaveric dissection and radiographic study. *Arthroscopy* 2006;22:984–92. <https://doi.org/10.1016/j.arthro.2006.04.102>.
- [46] Zavras TD, Race A, Amis AA. The effect of femoral attachment location on anterior cruciate ligament reconstruction: graft tension patterns and restoration of normal anterior-posterior laxity patterns. *Knee Surg Sports Traumatol Arthrosc* 2005;13:92–100.
- [47] Nawabi DH, Tucker S, Schafer KA, Zuiderbaan HA, Nguyen JT, Wickiewicz TL, et al. ACL fibers near the lateral intercondylar ridge are the most load bearing during stability examinations and isometric through passive flexion. *Am J Sports Med* 2016;44:2563–71. <https://doi.org/10.1177/0363546516652876>.
- [48] Kawaguchi Y, Kondo E, Takeda R, Akita K, Yasuda K, Amis AA. The role of fibers in the femoral attachment of the anterior cruciate ligament in resisting tibial displacement. *Arthroscopy* 2015;31:435–44. <https://doi.org/10.1016/j.arthro.2014.08.033>.
- [49] Farrow LD, Chen MR, Cooperman DR, Victoroff BN, Goodfellow DB. Morphology of the femoral intercondylar notch. *J Bone Joint Surg* 2007;89:A2150–5. <https://doi.org/10.2106/JBJS.F.01191>.

- [50] Sasaki N, Ishibashi Y, Tsuda E, Yamamoto Y, Maeda S, Mizukami H, et al. The femoral insertion of the anterior cruciate ligament: discrepancy between macroscopic and histological observations. *Arthroscopy* 2012;28:1135–46. <https://doi.org/10.1016/j.arthro.2011.12.021>.
- [51] Mommersteeg T, Blankevoort L, Kooloos J, Hendriks J, Kauer J, R H. Nonuniform distribution of collagen density in human knee ligaments. *J Orthop Res* 1994;12:238–45. <https://doi.org/10.1002/jor.1100120213>.
- [52] Petersen W, Tillmann B. Structure and vascularization of the cruciate ligaments of the human knee joint. *Anat Embryol* 1999;200:325–34. <https://doi.org/10.1007/s004290050283>.
- [53] Butler D, Guan Y, Kay M, Cummings J, Feder S, Levy M. Location-dependent variations in the material properties of the anterior cruciate ligament. *J Biomech* 1992;25:511–8. [https://doi.org/10.1016/0021-9290\(92\)90091-e](https://doi.org/10.1016/0021-9290(92)90091-e).
- [54] Zantop T, Wellmann M, Fu FH, Petersen W. Tunnel positioning of anteromedial and posterolateral bundles in anatomic anterior cruciate ligament reconstruction: anatomic and radiographic findings. *Am J Sports Med* 2008;36:65–72. <https://doi.org/10.1177/0363546507308361>.
- [55] Markolf KL, Jackson SR, McAllister DR. A Comparison of 11 o'clock versus oblique femoral tunnels in the anterior cruciate ligament-reconstructed knee: knee kinematics during a simulated pivot Test. *Am J Sports Med* 2010;38:912–7. <https://doi.org/10.1177/0363546509358321>.
- [56] Amis A, Dawkins G. Functional anatomy of the anterior cruciate ligament. Fibre bundle actions related to ligament replacements and injuries. *J Bone Joint Surg Br* 1991;73:260–7. <https://doi.org/10.1302/0301-620X.73B2.2005151>.
- [57] Hefzy M, Grood E, Noyes F. Factors affecting the region of most isometric femoral attachments. Part II: the anterior cruciate ligament. *Am J Sports Med* 1989;17:208–16. <https://doi.org/10.1177/036354658901700210>.
- [58] Siddles J, Larson R, Garbini J, Downey D, Matsen F. Ligament length relationships in the moving knee. *J Orthop Res* 1988;6:593–610. <https://doi.org/10.1002/jor.1100060418>.
- [59] Clatworthy M, Pearle A, Williams A, Lind M. Femoral tunnel placement in ACL reconstruction: central footprint versus AM bundle. *ISAKOS News* 2015;2:24–31.
- [60] Kittl C, El-Daou H, Athwal KK, Gupta CM, Weiler A, Williams A, et al. The role of the anterolateral structures and the ACL in controlling laxity of the intact and ACL-deficient knee. *Am J Sports Med* 2016;44:345–54. <https://doi.org/10.1177/0363546515614312>.
- [61] Pearle AD, McAllister D, Howell SM. Rationale for strategic graft placement in anterior cruciate ligament reconstruction: I.D.E.A.L. femoral tunnel position. *Am J Orthopedics* 2015;44:253–8.
- [62] O'Neill DB. Arthroscopically assisted reconstruction of the anterior cruciate ligament: a follow-up report. *J Bone Joint Surg* 2001;83(9):1329–32. <https://doi.org/10.2106/00004623-200109000-00006>.
- [63] Bedi A, Maak T, Musahl V, Citak M, O'Loughlin PF, Choi D, et al. Effect of tibial tunnel position on stability of the knee after anterior cruciate ligament reconstruction: is the tibial tunnel position most important? *Am J Sports Med* 2011;39:366–73. <https://doi.org/10.1177/0363546510388157>.
- [64] Brophy RH, Voos JE, Shannon FJ, Granchi CC, Wickiewicz TL, Warren RF, et al. Changes in the length of virtual anterior cruciate ligament fibers during stability testing: a comparison of conventional single-bundle reconstruction and native anterior cruciate ligament. *Am J Sports Med* 2008;36:2196–203. <https://doi.org/10.1177/0363546508320764>.
- [65] Ayerza MA, Músculo DL, Costa-Paz M, Makino A, Rondón L. Comparison of sagittal obliquity of the reconstructed anterior cruciate ligament with native anterior cruciate ligament using magnetic resonance imaging. *Arthroscopy* 2003;19:257–61. <https://doi.org/10.1053/jars.2003.50066>.
- [66] Stanford FC, Kendoff D, Warren RF, Pearle AD. Native anterior cruciate ligament obliquity versus anterior cruciate ligament graft obliquity: an observational study using navigated measurements. *Am J Sports Med* 2009;37:114–9. <https://doi.org/10.1177/0363546508323257>.
- [67] Iriuchishima T, Tajima G, McNeill Ingham SJ, Shen Wei, Smolinski P, Fu FH. Impingement pressure in the anatomical and nonanatomical anterior cruciate ligament reconstruction: a cadaver study. *Am J Sports Med* 2010;38:1611–7. <https://doi.org/10.1177/0363546510363461>.
- [68] Howell S. Principles for placing the tibial tunnel and avoiding roof impingement during reconstruction of a torn anterior cruciate ligament. *Knee Surg Sports Traumatol Arthrosc* 1998;6:49–55. <https://doi.org/10.1007/s001670050223>.
- [69] Howell SM, Taylor MA. Failure of reconstruction of the anterior cruciate ligament due to impingement by the intercondylar roof. *J Bone Joint Surg Am* 1993;75(7):1044–55. <https://doi.org/10.2106/00004623-199307000-00011>.
- [70] Lord BR, El-Daou H, Zdanowicz U, Śmigielski R, Amis AA. The role of fibers within the tibial attachment of the anterior cruciate ligament in restraining tibial displacement. *Arthroscopy* 2019;35:2101–11. <https://doi.org/10.1016/j.arthro.2019.01.058>.
- [71] Amis AA, Jakob RP. Anterior cruciate ligament graft positioning, tensioning and twisting. *Knee Surg Sports Traumatol Arthrosc* 1998;6(Suppl 1):S2–12. <https://doi.org/10.1007/s001670050215>.
- [72] Colombet P, Robinson J, Christel P, Franceschi JP, Djian P, Bellier G, et al. Morphology of anterior cruciate ligament attachments for anatomic reconstruction: a cadaveric dissection and radiographic study. *Arthroscopy* 2006;22:984–92. <https://doi.org/10.1016/j.arthro.2006.04.102>.
- [73] Iriuchishima T, Ingham S, Tajima G, Horaguchi T, Saito A, Tokuhashi Y, et al. Evaluation of the tunnel placement in the anatomical double-bundle ACL reconstruction: a cadaver study. *Knee Surg Sports Traumatol Arthrosc* 2010;18:1226–31. <https://doi.org/10.1007/s00167-010-1128-y>.
- [74] Kasten P, Szczodry M, Irrgang JJ, Kropf E, Costello J, Fu FH. What is the role of intra-operative fluoroscopic measurements to determine tibial tunnel placement in anatomical anterior cruciate ligament reconstruction? *Knee Surg Sports Traumatol Arthrosc* 2010;18:1169–75. <https://doi.org/10.1007/s00167-010-1082-8>.
- [75] Parker AP, Adriaensens MEAPM, Vindfeld S, Solheim E. The anatomic centers of the femoral and tibial insertions of the anterior cruciate ligament: a systematic review of imaging and cadaveric studies reporting normal center locations. *Am J Sports Med* 2017;45:2180–8. <https://doi.org/10.1177/0363546516673984>.
- [76] Büyükdogan K, Laidlaw M, Fox MA, Kew ME, Miller MD. Effect of tibial tunnel placement using the lateral meniscus as a landmark on clinical outcomes of anatomic single-bundle anterior cruciate ligament reconstruction. *Am J Sports Med* 2021;49:1451–9. <https://doi.org/10.1177/0363546521999672>.
- [77] Zantop T, Wellmann M, Fu FH, Petersen W. Tunnel positioning of anteromedial and posterolateral bundles in anatomic anterior cruciate ligament reconstruction: anatomic and radiographic findings. *Am J Sports Med* 2008;36:65–72. <https://doi.org/10.1177/0363546507308361>.
- [78] Parkinson B, Gonga R, Robb C, Thompson P, Spalding T. Anatomic ACL reconstruction: the normal central tibial footprint position and a standardised technique for measuring tibial tunnel location on 3D CT. *Knee Surg Sports Traumatol Arthrosc* 2017;25:1568–75. <https://doi.org/10.1007/s00167-015-3683-8>.
- [79] Lee JK, Lee S, Seong SC, Lee MC. Anatomy of the anterior cruciate ligament insertion sites: comparison of plain radiography and three-dimensional computed tomographic imaging to anatomic dissection. *Knee Surg Sports Traumatol Arthrosc* 2015;23:2297–305. <https://doi.org/10.1007/s00167-014-3041-2>.
- [80] O'Brien SJ, Warren RF, Pavlov H, Panariello R, Wickiewicz TL. Reconstruction of the chronically insufficient anterior cruciate ligament with the central third of the patellar ligament. *J Bone Joint Surg* 1991;73:278–86.
- [81] Van Dyck P, De Smet E, Roelant E, Parizel PM, Heusdens CHW. Assessment of anterolateral complex injuries by magnetic resonance imaging in patients with acute rupture of the anterior cruciate ligament. *Arthroscopy* 2019;35:521–7. <https://doi.org/10.1016/j.arthro.2018.08.032>.
- [82] Saithna A, Monaco E, Muramatsu K, Helito CP, Redler A, Sonnery-Cottet B, et al. Regarding "Identification of normal and injured anterolateral ligaments of the knee: a systematic review of magnetic resonance imaging studies. *Arthroscopy* 2019;35:2257–8. <https://doi.org/10.1016/j.arthro.2019.05.042>.
- [83] Muramatsu K, Saithna A, Watanabe H, Sasaki K, Yokosawa K, Hachiya Y, et al. Three-dimensional magnetic resonance imaging of the anterolateral ligament of the knee: an evaluation of intact and anterior cruciate ligament-deficient knees from the Scientific Anterior Cruciate Ligament Network International (SANTI) Study Group. *Arthroscopy* 2018;34:2207–17. <https://doi.org/10.1016/j.arthro.2018.02.014>.
- [84] Monaco E, Helito CP, Redler A, Argento G, De Carli A, Saithna A, et al. Correlation between magnetic resonance imaging and surgical exploration of the anterolateral structures of the acute anterior cruciate ligament-injured knee. *Am J Sports Med* 2019;47:1186–93. <https://doi.org/10.1177/0363546519831686>.
- [85] Inderhaug E, Stephen JM, Williams A, Amis AA. Biomechanical comparison of anterolateral procedures combined with anterior cruciate ligament reconstruction. *Am J Sports Med* 2017;45:347–54. <https://doi.org/10.1177/0363546516681555>.
- [86] Hewison CE, Tran MN, Kaniki N, Remtulla A, Bryant D, Getgood AM. Lateral extra-articular tenodesis reduces rotational laxity when combined with anterior cruciate ligament reconstruction: a systematic review of the literature. *Arthroscopy* 2015;31:2022–34. <https://doi.org/10.1016/j.arthro.2015.04.089>.
- [87] Devitt BM, Bell SW, Ardern CL, Hartwig T, Porter TJ, Feller JA, et al. The role of lateral extra-articular tenodesis in primary anterior cruciate ligament reconstruction: a systematic review with meta-analysis and best-evidence synthesis. *Orthop J Sports Med* 2017;5:1–12. <https://doi.org/10.1177/2325967117731767>.
- [88] Sonnery-Cottet B, Saithna A, Cavalier M, Kajetanek C, Temponi EF, Daggett M, et al. Anterolateral ligament reconstruction is associated with significantly reduced ACL graft rupture rates at a minimum follow-up of 2 years: a prospective comparative study of 502 patients from the SANTI Study Group. *Am J Sports Med* 2017;45:1547–57. <https://doi.org/10.1177/0363546516686057>.
- [89] Sobrado MF, Giglio PN, Bonadio MB, Helito PVP, Guimarães TM, Pécora JR, et al. Outcomes after isolated acute anterior cruciate ligament reconstruction are inferior in patients with an associated anterolateral ligament injury. *Am J Sports Med* 2020;48:3177–82. <https://doi.org/10.1177/0363546520956266>.
- [90] Willinger L, Balendra G, Pai V, Lee J, Mitchell A, Jones M, et al. High incidence of superficial and deep medial collateral ligament injuries in "isolated" anterior cruciate ligament ruptures: a long overlooked injury. *Knee Surg Sports Traumatol Arthrosc* 2022;30(1):167–75. <https://doi.org/10.1007/s00167-021-06514-x>.
- [91] Svantesson E, Hamrin Senorski E, Alentorn-Geli E, Westin O, Sundemo D, Grassi A, et al. Increased risk of ACL revision with non-surgical treatment of a concomitant medial collateral ligament injury: a study on 19,457 patients from the Swedish National Knee Ligament Registry. *Knee Surg Sports Traumatol Arthrosc* 2019;27:2450–9. <https://doi.org/10.1007/s00167-018-5237-3>.
- [92] Borque K, Jones M, Williams A. Management of the medial collateral ligament in the combined ligament injured knee. *Asian J Arthrosc* 2020;5:36–42. <https://doi.org/10.13107/aja.2020.v05i01.007>.
- [93] Ball S, Stephen JM, El-Daou H, Williams A, Amis AA. The medial ligaments and the ACL restrain anteromedial laxity of the knee. *Knee Surg Sports Traumatol Arthrosc* 2020;28:3700–8. <https://doi.org/10.1007/s00167-020-06084-4>.