

Lateral Extra-articular Tenodesis: A Technique With an Iliotibial Band Strand Without Implants



Sebastian Abusleme, M.D., Lars Strömbäck, M.D., Gaston Caracciolo, M.D., Hector Zamorano, M.D., Jorge Cheyre, M.D., Francisco Vergara, M.D., and Roberto Yañez, M.D.

Abstract: The main goal in anterior cruciate ligament reconstruction (ACLR) should be to restore normal knee biomechanics so the chances of failure decrease. The persistence of knee instability after ACLR goes from 0.7% to 20%. Several factors have been identified and studied, but there are some selected cases in which it seems that without adding lateral extra-articular tenodesis (LET) it is not possible to control rotational instability. Data exist supporting that LET could reduce pivot shift (PS), without losing flexion/extension range of motion nor adding risk of osteoarthritis. Recently, LET has been used in addition to ACLR to add restriction to internal tibial rotation forces, and different authors have shown their techniques to achieve this task. Also, biomechanical studies have compared different techniques for LET procedures. This article aims to describe our technique performing a modified Macintosh LET as an addition to ACLR in selected patients who require extra internal tibial rotation control. This is a reproducible, easy to learn, and inexpensive procedure in terms that only a high resistance suture is needed and not any other implant, such as a stapler, anchors, or screws, reducing the risk of tunnel coalition.

The main goal in anterior cruciate ligament reconstruction (ACLR) should be to restore normal knee biomechanics so the chances of failure decrease. The persistence of knee instability after ACLR ranges from 0.7% to 20%.¹ Several factors have been identified and studied, but there are some selected cases in which it seems that without adding lateral extra-articular tenodesis (LET), it is not possible to control rotational instability.² There are data supporting that LET could reduce pivot shift (PS) without losing flexion/extension range of motion³ nor adding the risk of osteoarthritis.⁴

Recently, LET has been used in addition to ACLR to add restriction to internal tibial rotation forces,⁴ and different authors have shown their techniques to

achieve this task.⁵⁻⁹ Also, biomechanical studies have compared different techniques for LET procedures.¹⁰

This article aims to describe our technique performing a modified Macintosh LET as an addition to ACLR in

Table 1. Pearls and Pitfalls

Pearls	Pitfalls
Always look for other potential rotation instability contributors and solve them. LET is not the solution to everything.	Overconstrained or non-neutral rotation may lead to altered biomechanics with bad results.
It is not necessary to obtain big incisions; with your assistant having good separation techniques, a 7-cm skin incision should be enough.	Going too anterior or too posterior in ITB dissection will make it difficult to close and might have an excess of tension when doing it.
Have special careful in tibial rotation when performing an LET. Always do it in neutral rotation. (spaces between sentences are not symmetric, in this table and in table number 2)	When suturing the free portion of the ITB make sure it gets thin enough to pass deep the FCL and the intermuscular septum.
Remember to close the ITB. It will prevent muscular herniation. Using a continuous knotless suture makes it easier to close the most proximal aspect	

FCL, fibular collateral ligament; ITB, iliotibial band; LET, lateral extra-articular tenodesis.

From Clínica MEDS, Santiago de Chile.
The authors report that they have no conflicts of interest in the authorship and publication of this article. Full ICMJE author disclosure forms are available for this article online, as [supplementary material](#).

Received June 25, 2020; accepted September 15, 2020.

Address correspondence to Sebastian Abusleme Demián, Clínica MEDS, Santiago de Chile. E-mail: sebastian.abusleme@meds.cl

© 2020 by the Arthroscopy Association of North America. Published by Elsevier. This is an open access article under the CC BY-NC-ND license (<http://creativecommons.org/licenses/by-nc-nd/4.0/>).

2212-6287/201114

<https://doi.org/10.1016/j.eats.2020.09.029>

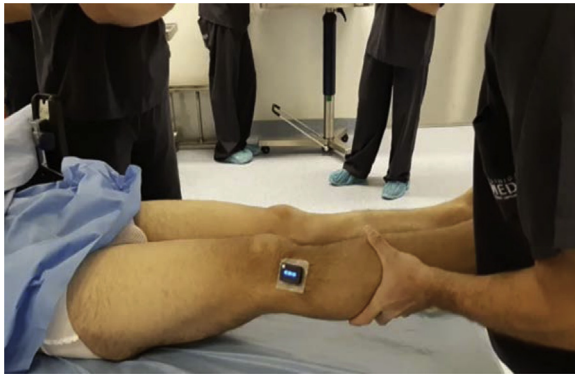


Fig 1. Patient is in the supine position. Lateral view of a right knee. With inertial sensors installed in the middle point between the patient's Gerdy's tubercle and the tibial tuberosity, the surgeon performs a pivot shift test to have an accurate digital result of the internal rotation of the tibia.

selected patients who require extra internal tibial rotation control.

Surgical Technique (With Video Illustration)

A video of this technique is available ([Video 1](#)). Pearls and pitfalls are shown on [Table 1](#).

Patient Positioning, Examination With and Without Anesthesia

The patient is placed in supine position on the surgery table. Before anesthesia is administered, a bilateral knee examination is performed to evaluate any instability. With inertial sensors installed in the middle point between the patient's Gerdy's tubercle and the tibial tuberosity, the surgeon performs a PS test to have an accurate digital result of the internal rotation of the tibia ([Fig 1](#)). When the examination is completed, general or spinal anesthesia is performed and when motor block is ready and confirmed the examination is repeated, to

address the real PS without muscle reaction and pain. An explosive grade III PS shown with the inertial sensors alerts of the need to reinforce the ACLR with a LET. A padded high tourniquet is installed on the operating side thigh and placed in a semicircular leg holder so the knee gets to 90° of flexion.

Surgical Approach

Before starting with the LET procedure, arthroscopy is performed. It is crucial to assess all injuries that could contribute to rotational instability, such as meniscus or meniscal root tears. **We prefer to do the ACLR reconstruction before the LET procedure because it gives the surgeon an idea about how the joint is going to behave with the ACLR.** Another important measure that encourages adding an LET is the closure of the lateral tibiofemoral joint space after ACLR. If the space after ACLR is more than 5 mm, we perform the LET ([Fig 2](#)). We are looking forward to publishing this measure.

A 6- to 8-cm skin incision is made in the lateral aspect of the thigh, proximal to Gerdy's tubercle ([Fig 3](#)). Dissection is performed to **expose the iliotibial band (ITB).** It is important to recognize the posterior and anterior limits of the ITB. **To obtain a 1-cm wide ITB strand, an incision is made in the middle third to begin harvesting keeping the distal attachment on Gerdy's tubercle ([Fig 4](#)).** **The harvest is extended proximal to complete 8-12 cm in length ([Fig 5](#)).** We recommend starting the incision with a scalpel and **continuing with Metzenbaum scissors, taking care not to damage deep structures such as fibular collateral ligament (FCL).** As you get to the more proximal aspect, skin separation is needed to have a complete view of the ITB. If you need to tension the skin in excess, then it is preferred to extend the skin incision.

After you obtain a clean 8- to 12-cm length and 1-cm wide strand of ITB with its distal attachment in Gerdy's

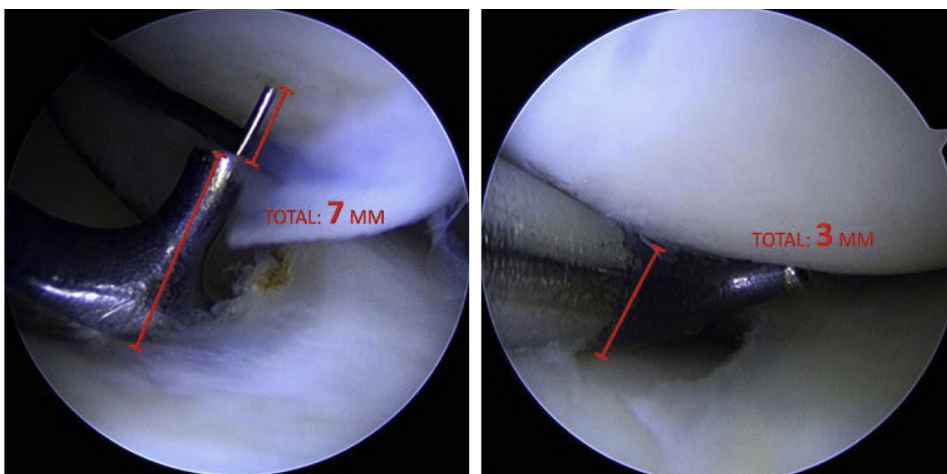


Fig 2. Arthroscopic view of the lateral tibiofemoral space. Another important measure that encourages adding an LET is the closure of the lateral tibiofemoral joint space after ACLR. If the space after ACLR is more than 5 mm, we perform the LET. (ACLR, anterior cruciate ligament reconstruction; LET, lateral extra-articular tenodesis.)

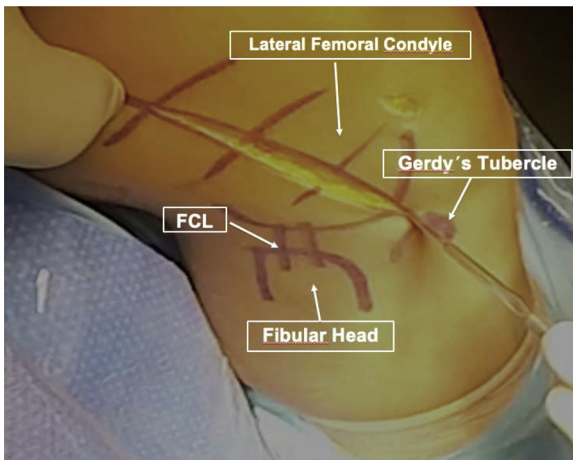


Fig 3. Patient is in the supine position, knee at 90° of flexion. Lateral view of a right knee. A 6- to 8-cm skin incision is made in the lateral aspect of the thigh, proximal to Gerdy's tubercle. (FCL, fibular collateral ligament.)

tubercle, a no. 2.0 VICRYL suture (Ethicon-Johnson & Johnson, Somerville, NJ) is passed in the free end with a Krakow-like fashion for 1 cm approximately (Fig 6).

With the free end prepared, the ITB strand is passed from distal to proximal and the most important aspect to get the biomechanics as expected, is to pass deep to the FCL (Fig 7). Having passed it under the FCL the intermuscular septum is identified and the sutures are passed deep to it (Fig 8). This is easier to do with a vascular clamp. When the ITB strand is passed deep the septum, make a loop so you return heading distal again (Fig 9). Now you are ready to suture the band onto itself. For this, 30° of flexion is recommended and neutral rotation of the tibia is a must. Fixation is done with 5 independent high-resistance stitches (FiberWire; Arthrex, Naples, FL) of the band onto itself (Fig 10).

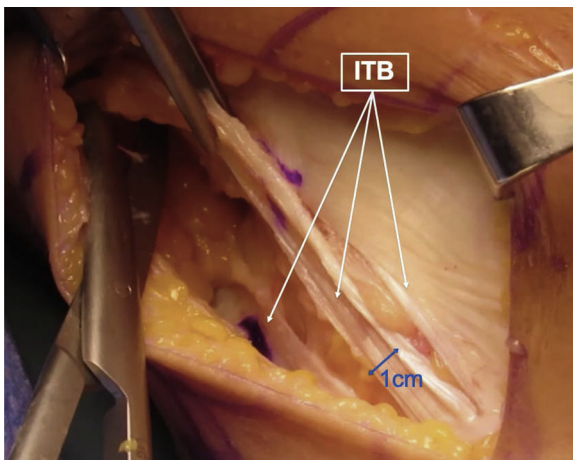


Fig 4. Patient in supine, knee at 90° of flexion. Lateral view of a right knee. To obtain a 1-cm wide ITB strand, an incision is made in the middle third to begin harvesting keeping the distal attachment on Gerdy's tubercle. (ITB, iliotibial band.)

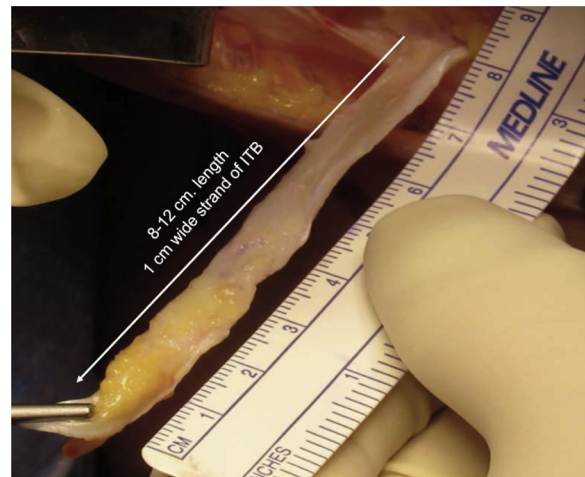


Fig 5. Patient is in the supine position, knee at 90° of flexion. Proximally detached ITB strand seen from lateral. The ITB harvest is extended proximally to a complete 8- to 12-cm length. (ITB, iliotibial band.)

A key point here is not to overconstrain, so it is important not to apply too much tension and to always check that full range of motion is permitted. Before closure, careful hemostasia is performed so the eventual risk of lateral hematoma is decreased. For closure, anterior and posterior lips of the ITB are sutured with continuous knotless suture (STRATAFIX; Johnson & Johnson) to make it easier and to avoid the risk of muscular herniation (Fig 11). The subcutaneous layer is closed using no 3.0 VICRYL suture (Ethicon-Johnson & Johnson), and the skin closure is up to surgeon's preferences; staples or intradermic sutures can be used.

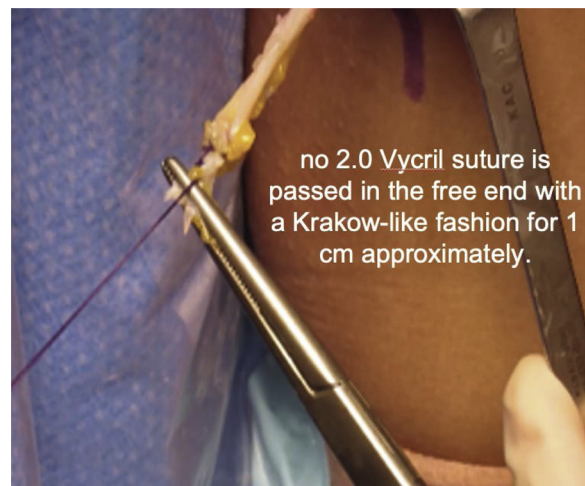

Fig 6. Patient is in the supine position, knee at 90° of flexion. Free end of ITB harvest seen laterally. After you obtain a clean 8- to 12-cm length and 1-cm wide strand of ITB with its distal attachment in Gerdy's tubercle, a no. 2.0 VICRYL suture is passed in the free end with a Krakow-like fashion for 1 cm approximately. (ITB, iliotibial band.)

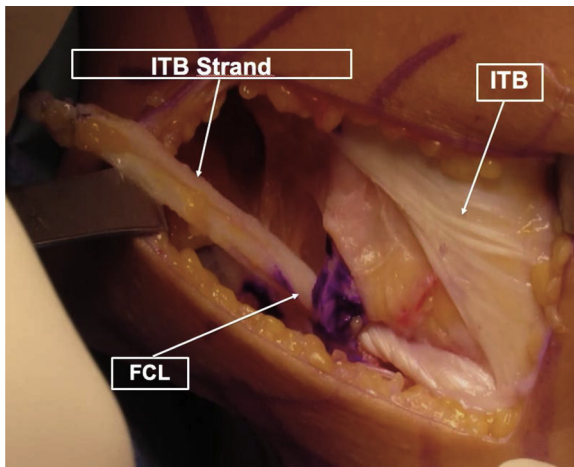


Fig 7. Patient is in the supine position, knee at 90° of flexion. Lateral view of a right thigh, distal portion. **With the free end prepared, the ITB strand is passed from distal to proximal and the most important aspect to get the biomechanics as expected, is to pass deep to the FCL.** (FCL, fibular collateral ligament; ITB, iliotibial band.)

Discussion

With the aim of improving rotational stability, anatomic and nonanatomic lateral procedures have been developed. To our understanding and based on the literature, **LET is a better choice over anterolateral ligament reconstruction.**¹¹ It is a technique that has shown to decrease not only anterior translation when combined with ACLR but also to reduce internal tibial rotation that produces anterolateral instability that may lead to ACL graft failure.¹⁰

Our group has been performing this procedure since 2014, and different techniques have been applied. Now,

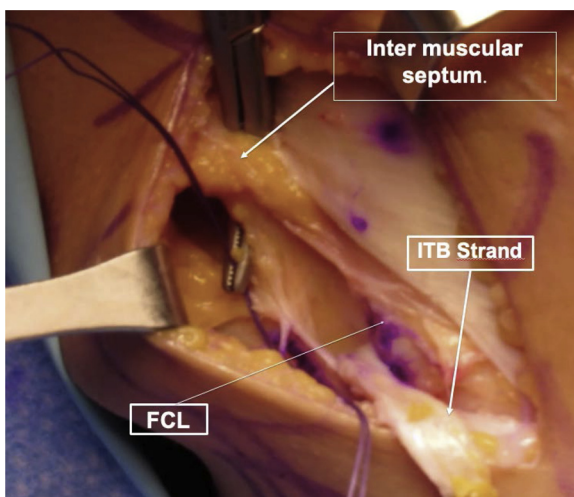


Fig 8. Patient is in the supine position, knee at 90° of flexion. Lateral view of a right thigh, distal portion. Having passed it under the fibular collateral ligament, the intermuscular septum is identified and the sutures are passed deep to it. (FCL, fibular collateral ligament.)

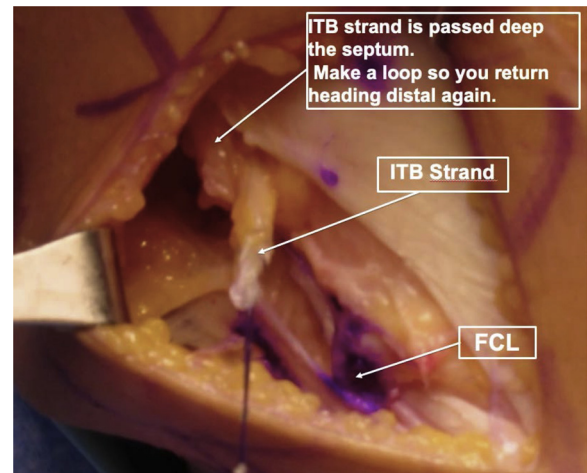


Fig 9. Patient is in the supine position, knee at 90° of flexion. Lateral view of a right thigh, distal portion. When the ITB strand is passed deep into the septum, make a loop so you return heading distal again. (FCL, fibular collateral ligament; ITB, iliotibial band.)

we use a modification of the aforementioned original Macintosh procedure **because of its advantages and low risks** (Table 2); it is a reproducible, easy to learn, and inexpensive procedure in terms that only a high-resistance **suture is needed and not any other implant, such as stapler, anchors, or screws, reducing the risk of tunnel coalition.**

In terms of indicating this additional procedure to ACLR, we recommend to assess it case by case, and supported by the published literature,^{12,13} we can say that suggested indications may be ACLR rerupture, younger age, lateral tibial slope >12°, hyperlaxity,

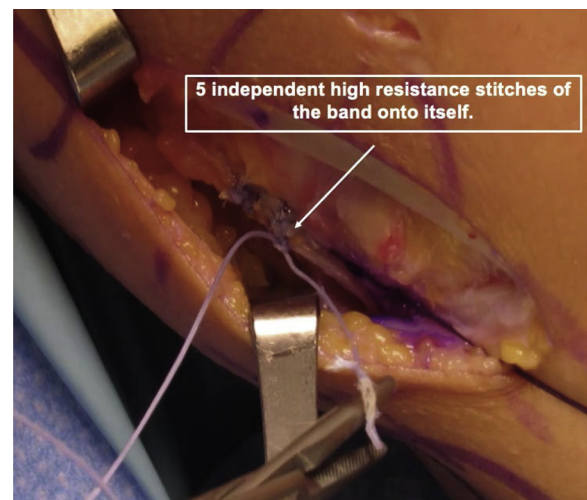


Fig 10. Patient is in the supine position, knee at 30° of flexion. Lateral view of a right thigh, distal portion. Suture the band onto itself. For this, 30° of flexion is recommended and neutral rotation of the tibia is a must. Fixation is performed with 5 independent high-resistance stitches.

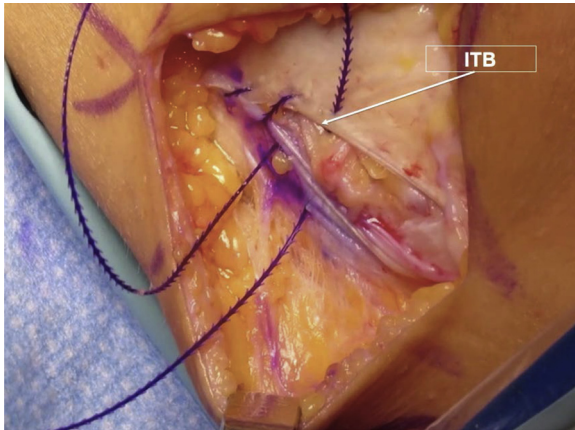


Fig 11. Patient is in the supine position, knee at 30° of flexion. Lateral view of a right thigh, distal portion. For closure, anterior and posterior lips of the ITB are sutured with continuous knotless suture to make it easier and to avoid the risk of muscular herniation. (ITB, iliotibial band.)

medial meniscus posterior horn suture or deficiency, elite players in cutting or pivoting sports, and history of contralateral ACLR.

To assess its biomechanical value, we have been performing a landing and pivoting study with 3-dimensional kinematic movement analysis (Vicon, Oxford, UK) that has shown a reduction in pivot shifting compared with the contralateral limb, without affecting flexion and extension range of motion. We are looking forward to publishing our results. Although this technique and preliminary results have been presented in several meetings by the senior author, this is the very first time we have published it. Based on the biomechanical effects and the literature supporting LET, we recommend this procedure in addition to ACL in selected cases. Further investigation should focus on long-term and clinical outcomes.

Table 2. Advantages and Disadvantages

Advantages	Disadvantages/Risks
Reproducible, easy-to-learn technique.	May add pain to postoperative rehabilitation. (spaces between sentences are not symmetric)
Inexpensive procedure: only a high-resistance suture is needed	Special attention to quadriceps inhibition.
No risk of tunnel coalition when performed with an ACLR.	Muscle herniation if ITB closure is not performed in proper way.

ACLR, anterior cruciate ligament reconstruction; ITB, iliotibial band.

References

- Di Benedetto P, Di Benedetto E, Fiocchi A, Beltrame A, Caisero A. Causes of failure of anterior cruciate ligament reconstruction and revision surgical strategies. *Knee Surg Relat Res* 2016;28:319-324.
- Inderhaug E, Stephen J, Williams A, Amis A. Biomechanical comparison of anterolateral procedures combined with anterior cruciate ligament reconstruction. *J Sports Med* 2017;45:347-354.
- Williams A, Ball S, Stephen J, White N, Jones M, Amis A. The scientific rationale for lateral tenodesis augmentation of intra-articular ACL reconstruction using a modified 'Lemaire' procedure. *Surg Sports Traumatol Arthrosc* 2017;25:1339-1344.
- Devitt BM, Bouguennec N, Barfod KW, Porter T, Webster KE, Feller JA. Combined anterior cruciate ligament reconstruction and lateral extra-articular tenodesis does not result in an increased rate of osteoarthritis: A systematic review and best evidence synthesis. *Knee Surg Sports Traumatol Arthrosc* 2017;25:1149-1160.
- Kwapisz A, Mollison S, McRae S, MacDonald P. Lateral extra-articular tenodesis with proximal staple fixation. *Arthrosc Tech* 2019;8:821-825.
- Rocha da Silva H, Rocha de Faria J, Simões R, et al. Lateral tenodesis associated with an intra-articular anterior cruciate ligament reconstruction without proximal disinsertion of iliotibial band. *Arthrosc Tech* 2019;8:1217-1221.
- Boutsiadis A, Brossard P, Panisset J-C, Graveleau N, Barth J. Minimally invasive combined anterior and anterolateral stabilization of the knee using hamstring tendons and adjustable-loop suspensory fixation device: Surgical technique. *Arthrosc Tech* 2019;6:419-425.
- Bernholt D, Kennedy M, Crawford M, DePhillipo N, LaPrade R. Combined anterior cruciate ligament reconstruction and lateral extra-articular tenodesis. *Arthrosc Tech* 2019;8:855-859.
- Schlichte L, Aitchison A, Green D, Cordasco F. Modified Lemaire lateral extra-articular tenodesis in the pediatric patient: An adjunct to anterior cruciate ligament reconstruction. *Arthrosc Tech* 2019;9:111-116.
- Slette E, Mikula J, Schon J, et al. Biomechanical results of lateral extra-articular tenodesis procedures of the knee: A systematic review. *Arthroscopy* 2016;32:2592-2611.
- Inderhaug E, Stephen J, Williams A, Amis A. Anterolateral tenodesis or anterolateral ligament complex reconstruction: Effect of flexion angle at graft fixation when combined with ACL reconstruction. *J Sports Med* 2017;45:3089-3097.
- Weber A, Zuke W, Mayer E, et al. Lateral augmentation procedures in anterior cruciate ligament reconstruction: Anatomic, biomechanical, imaging, and clinical evidence. *Am J Sports Med* 2019;47:740-752.
- Salmon LJ, Heath E, Akrawi H, Roe JP, Linklater J, Pinczewski LA. 20-Year outcomes of anterior cruciate ligament reconstruction with hamstring tendon autograft: The catastrophic effect of age and posterior tibial slope. *Am J Sports Med* 2018;46:531-543.