



## ■ THE REVISION HIP

# Conversion of hip fusion to total hip replacement

## TECHNIQUE AND RESULTS

M. R. Whitehouse,  
C. P. Duncan

From University of  
British Columbia,  
Vancouver, British  
Columbia, Canada

**Hip arthrodesis remains a viable surgical technique in well selected patients, typically the young manual labourer with isolated unilateral hip disease. Despite this, its popularity with patients and surgeons has decreased due to the evolution of hip replacement, and is seldom chosen by young adult patients today. The surgeon is more likely to encounter a patient who requests conversion to total hip replacement (THR). The most common indications are a painful pseudarthrosis, back pain, ipsilateral knee pain or contralateral hip pain. Occasionally the patient will request conversion because of difficulty with activities of daily living, body image and perceived cosmesis. The technique of conversion and a discussion of the results are presented.**

**Cite this article: *Bone Joint J* 2013;95-B, Supple A:114–19.**

Hip arthrodesis may be performed surgically or ankylosis can occur spontaneously. In the case of the latter, this is usually following infection. Arthrodesis is a procedure that has declined in popularity, with the evolution of both improved fixation methodologies and the huge success of total hip replacement (THR). The ideal candidate for the procedure used to be the young, usually male, manual labourer with monoarthrosis of the hip. There are a number of indications in which hip arthrodesis was, and might still be considered. This includes significant deformity of the femur or pelvis that precludes a THR, in the case of neurological abnormalities where the risk of dislocation is high or in the context of an increased risk of failure of THR in a very young population of patients.

Albee appears to have presented the first report of a hip arthrodesis in the English language with an osteotomy of the femoral head and sourcil performed to achieve flat opposing surfaces without fixation.<sup>1</sup> The osteotomy of the femoral head was performed in line with the superior aspect of the femoral neck and an oblique osteotomy of the sourcil was performed to create an abducted position of the leg when the two surfaces were opposed. Wilson<sup>2</sup> described the use of an ilio-femoroplasty to achieve an extra-articular fusion of the hip and Ghormley<sup>3</sup> suggested the use of a combination of intra and extra-articular bone autografting to address the problem of nonunion and pseudarthrosis. This method used the harvested portion of the ilium, centred on the

anterior superior iliac spine, as a block graft sited in a groove cut into the trochanter, neck, head and ilium. Trumble, and later Brittain described ischiofemoral arthrodesis with the use of a tibial strut autograft.<sup>4,5</sup>

The use of internal fixation devices, such as the Smith-Petersen nail to augment the stability of the arthrodesis, resulted in fusion rates of 85% to 94% according to Watson-Jones and Lange.<sup>6,7</sup> The addition of a subtrochanteric osteotomy,<sup>8</sup> medialisation of the femoral head<sup>9</sup> and the addition of lateral plate fixation<sup>10</sup> were subsequently recommended in order to improve fusion rates.

Long term follow up of patients undergoing hip arthrodesis suggests the results are reasonable. Sponseller, McBeath and Perpich<sup>11</sup> reported a minimum 20 year follow up of a cohort of 53 successfully fused hips, where 41 patients were satisfied and able to work, five were either not entirely satisfied or unable to work but had not required conversion to THR and seven required revision to THR. Callaghan et al<sup>12</sup> described a conversion to THR in six out of 28 patients at a mean follow up of 35 years (17 to 50). Sofue et al<sup>13</sup> had a minimum 15 year follow up of 40 patients, 38 of whom were satisfied with no conversions to THR. At a mean 18 year follow up of 30 patients from a cohort of 47 undergoing hip arthrodesis, Schafroth et al<sup>14</sup> observed that conversion to THR had been performed in seven and there were six nonunions. Pain scores are generally lower in the arthrodesed hip than in the back or ipsilateral knee, and the position in which

■ M. R. Whitehouse, PhD,  
MSc(Orth Eng), BSc(Hons),  
FRCS(Tr&Orth), Lower Limb  
Reconstruction & Oncology  
Fellow

■ C. P. Duncan, MB, MSc,  
FRCS(C), Professor of  
Orthopaedics  
University of British Columbia,  
The University of British  
Columbia, Department of  
Orthopaedics, 3rd Floor, 910  
West 10th Avenue, Vancouver,  
BC, V5Z 4E3, Canada.

Correspondence should be sent  
to M. Whitehouse; e-mail:  
michael.whitehouse@bristol.ac  
.uk

©2013 The British Editorial  
Society of Bone & Joint  
Surgery  
doi:10.1302/0301-620X.95B11.  
32908 \$2.00

*Bone Joint J*  
2013;95-B, Supple A:114–19.  
Received 7 September 2013;  
Accepted after revision 8  
September 2013

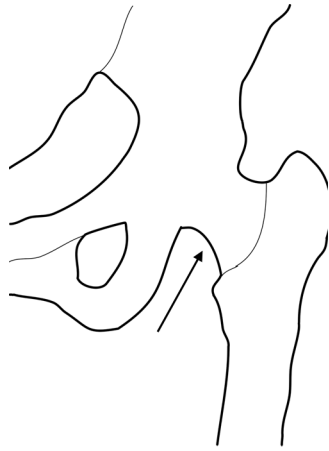


Fig. 1

Diagram showing the use of the pubofemoral arch as an intra-operative landmark.

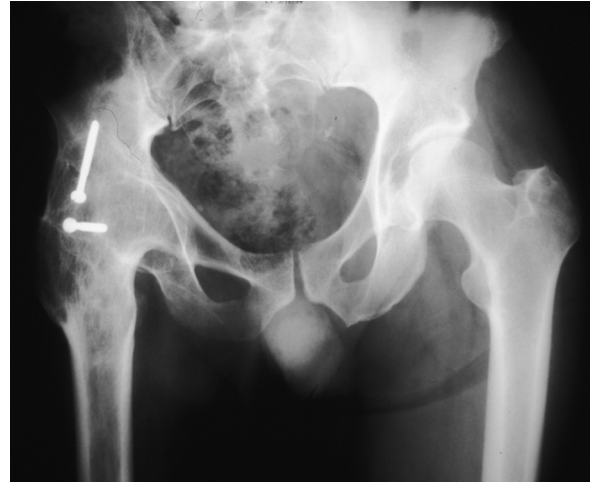

Fig. 2

Radiograph showing the 'two screw danger sign' which may indicate the fixation of a bone block with a substantial portion of the abductors attached.

the hip is arthrodesed affects the likelihood of developing these symptoms, particularly if the hip is fused in abduction.<sup>12</sup>

Common indications for the conversion of an arthrodesed hip to a THR include pain arising from the lower back, ipsilateral knee or contralateral hip, a painful nonunion or malpositioned arthrodesis, planned ipsilateral knee replacement or fractures around the arthrodesis. It is important that the origin of pain is accurately defined, and the functional demands and expectations of the patient explored prior to conversion, in order for the patient to decide whether the anticipated risks and benefits are worthwhile.

### Pre-operative assessment

The original reason why the arthrodesis was performed should be sought. If the arthrodesis was performed for or following infection, any history of delayed wound healing, wound drainage, sinus formation or antibiotics following previous hip surgery should be actively excluded. In the presence of on-going infection, the authors recommend a two-stage procedure is performed to ensure clearance of infection before any definitive THR. The authors suggest a protocol including an interval of three months between procedures, with an articulating spacer in the interim where possible and a minimum of six weeks intravenous antibiotic therapy tailored to the sensitivities of any identified bacteria. If doubt remains, frozen sections are performed on intra-operative samples, in addition to many specimens collected with separate clean instruments sent for microscopy, culture and sensitivity. Patients with on-going infection are informed that the final outcome could be a Girdlestone excision arthroplasty<sup>15</sup> with commensurately lower levels of function. C-reactive protein and erythrocyte sedimentation rate are routinely taken and we use thresholds of < 10 mg/L and < 30 mm/hr respectively to define unacceptable levels.

Other imaging techniques such as a radio labelled white cell scan can also be used.

A clinical examination should be performed to define whether the hip is soundly fused, in what position the hip has been arthrodesed, the amount of leg length discrepancy, (LLD) (which can be difficult to assess, particularly in the case of a malpositioned arthrodesis), and the integrity and function of the abductors. We correlate the clinical and radiological assessment of LLD in an attempt to define this accurately. Long leg films or a CT scanogram of the legs may be required in order to measure LLD accurately. If the LLD > 3 cm, the patient is informed that complete correction of limb length is unlikely without excessive risk of neurovascular damage.<sup>16</sup> The risk is considered higher for a long standing arthrodesis, particularly when it occurred in childhood.

The abductors are palpated for bulk and defects. The patient is asked to attempt abduction in the arthrodesed hip and the degree of contraction assessed. Electromyography has been suggested to be useful but is not part of the authors' protocol. Further imaging, such as an ultrasound scan (USS) or computerised tomography (CT) scan may also be used; CT has the added benefit of allowing further assessment of the bone stock and identifying if a pseudarthrosis is present, which may in turn make the identification of the true acetabulum and its floor straightforward. Radiographs should include an anteroposterior (AP) view of the pelvis and a true lateral of the arthrodesed hip. In the case of femoral deformity, whole length AP and lateral views of the femur should be included. Judet views or in the case of retained metalwork, 60° oblique views may help delineate the bone stock available.

Pre-operative templating of the hip is performed on the radiographs. Landmarks are identified that will be

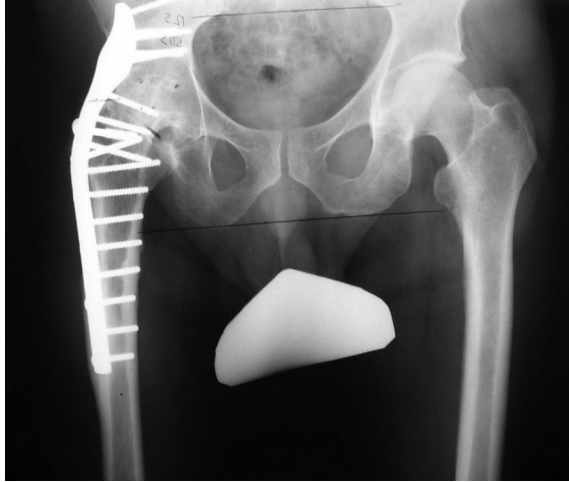

Fig. 3

Pre-operative radiograph demonstrating a hip arthrodesis with a laterally placed cobra plate.

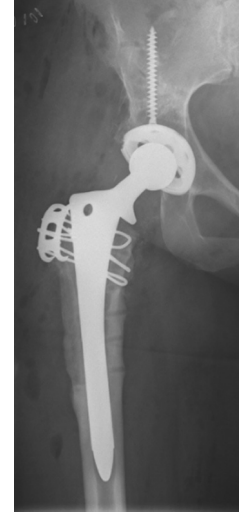


Fig. 4

Post-operative radiograph following removal of the arthrodesis and conversion to THR.

encountered intra-operatively and may be used as reference points. It is useful if the greater trochanter is still prominent. If it is absent, the authors' preferred reference point for the femoral neck osteotomy is the pubo-femoral arch (Fig. 1). If an extra-articular arthrodesis has been performed, then its location should be noted as it will need to be taken down during the procedure.

If the anatomy is relatively normal on the contralateral side it can be used to gain an approximate idea of the implant sizes, which are then checked against the arthrodesed hip and the implant positions and orientations marked. Metalwork and screw holes can also be used as reference points. The location of metalwork may give important clues as to intra-operative encounters. For example, extra-articular screws were used by Thompson<sup>8</sup> and Davis<sup>17</sup> to secure a large iliac crest graft with a substantial portion of the abductors still attached, which strongly signals an attendant risk of post-operative instability (Fig. 2).

### Surgical technique (Figs 3 and 4)<sup>18</sup>

The patient is placed in the lateral decubitus position, with the uppermost arthrodesed side. The limb is prepared and draped to permit free positioning. Scars in the region are marked. The ideal location of the incision lies over the mid axis of the femur laterally and curves posteriorly by approximately 20° at the tip of the trochanter. This may be modified to allow for removal of metal ware or an extra-articular arthrodesis. Where possible, previous incisions are incorporated or excised. If the greater trochanter is still defined with abductors attached, a trochanteric osteotomy is performed. The osteotomised trochanter is reflected proximally, with careful preservation of the superior gluteal

neurovascular bundle. The sciatic nerve is identified and protected through the course of the procedure. The exposure is extended so that landmarks such as the pubo-femoral arch can be identified and the femoral neck osteotomy is marked with reference to the landmarks: this may be confirmed with a radiograph. The osteotomy is performed, and soft-tissue released around the proximal femur to allow exposure of the acetabulum. If the arthrodesis was performed with the head positioned concentrically within the acetabulum, reaming can be focussed on the exposed neck, with concentration on maintenance of the anterior and posterior walls and columns of the pelvis and acetabulum. If the head was not concentric, the superior margin of the acetabular foramen should be exposed inferiorly, and the centre of the acetabulum referenced from there. The authors routinely take a radiograph after reaming has commenced in order to confirm position and orientation. Where the location of the true floor of the acetabulum is not clear, the surgeon can drill medially with a 2 mm drill and pass a depth gauge. The bone quality will not be normal, therefore revision acetabular components are preferred with supplementary screw fixation.

The femur is prepared according to the surgeon's preferred technique. This may need to be modified if a corrective or subtrochanteric osteotomy is required. The stability of the hip is assessed. There is a high risk of dislocation despite correct implant orientation and restoration of leg lengths and offset, and the use of a constrained liner may be required. When the trial reduction is performed, the tension on the sciatic nerve should also be checked. If a trochanteric osteotomy has been performed it is repaired with wires during closure. If no defined trochanter was present, the gluteus

**Table I.** Summary of papers reporting outcome of conversion of hip fusion to total hip replacement series (N/A, not reported)

Author (Year)	No. of patients (hips)	Mean age at conversion (yrs) (range)	Mean duration fusion (yrs) (range)	Mean follow-up (yrs) (range)	Main outcome score used	Pre-operative score	Post-operative score	Survivorship (95% CI at interval where reported)
Abdel-Aal et al <sup>27</sup>	12 (16)	29 (16 to 48)	15 (3 to 38)	1 (N/A)	HHS	42 (39 to 51)	76 (44 to 86)	N/A
Aderinto et al <sup>31</sup>	18 (18)	53 (21 to 77)	33 (11 to 60)	5 (2 to 15)	HHS	49 (37 to 61)	75 (39 to 90)	89%
Amstutz et al <sup>39</sup>	16 (16)	50 (27 to 64)	33 (7 to 62)	1.5 (1 to 3)	Modified MdA	3.8/5.3/5.0	8.5/6.3/5.8	N/A
Brewster et al <sup>30</sup>	33 (33)	N/A (24 to 69)	N/A	(1 to 3.5)	N/A	N/A	N/A	94%
Fernandez-Fairen et al <sup>21</sup>	48 (48)	52 (31 to 68)	26 (3 to 47)	17 (10 to 29)	HHS	60 (47 to 78)	85 (43 to 96)	83% (60 to 95) at 20 yrs
Hamadouche et al <sup>36</sup>	45 (45)	56 (28 to 80)	36 (3 to 65)	8 (5 to 21)	MdA	11.3 +/- to 0.7	16.5 +/- to 1.5	91% (78 to 100) at 10 yrs
Hardinge et al <sup>38</sup>	52 (54)	59 (32 to 74)	21 (2 to 58)	2.5 (1 to 11)	MdA	4.6/3.3/1.0	5.9/5.0/4.7	100%
Joshi et al <sup>20</sup>	187 (208)	51 (20 to 80)	27 (10 to 69)	9 (2 to 26)	MdA	4.7/3.3/1.0	5.6/4.5/4.1	90% (85 to 96) at 15 yrs
Kempf et al <sup>40</sup>	22 (22)	57 (28 to 80)	18 (1 to 32)	6 (1 to 18)	MdA	3.9/3.6/ to	5.3/3.8/4.4	86%
Kilgus et al <sup>25</sup>	38 (41)	53 (24 to 75)	28	7 (2 to 16)	UCLA	6.9/5.7/6.0	8.5/7.2/7.5	78%
Kim et al <sup>37</sup>	12 (24)	36 (19 to 60)	11 (1 to 20)	11 (3 to 17)	HHS	55 (42 to 79)	82 (69 to 92)	96%
Lubahn et al <sup>28</sup>	17 (18)	59 (38 to 82)	21 (5 to 60)	N/A	Iowa Hip Scale	N/A	67 (50 to 80)	89%
Morsi et al <sup>24</sup>	18 (19)	51 (38 to 62)	21 (5 to 41)	7 (5 to 10)	HHS	54 (19 to 76)	93 (81 to 98)	95%
Peterson et al <sup>33</sup>	30 (30)	52 (27 to 70)	33 (1 to 42)	10 (2 to 20)	MCH	20 good/fair, 3 poor/fail		75% (59 to 95) at 10 yrs
Reikerås et al <sup>34</sup>	46 (46)	58 (33 to 75)	17 (7 to 28)	8 (5 to 13)	HHS	69 (51 to 83)	78 (53 to 93)	85%
Richards et al <sup>35</sup>	26 (26)	49 (25 to 74)	20 (18 to 28)	9 (2 to 21)	OHS	N/A	72	74% (55 to 93) at 10 yrs
Rittmeister et al <sup>32</sup>	13 (13)	60 (29 to 86)	29 (14 to 56)	3 (1 to 7)	HHS	55 (23 to 82)	87 (75 to 96)	N/A
Schäfer et al <sup>29</sup>	15 (15)	N/A	31 (2 to 61)	5 (2 to 13)	HHS	N/A	86 (70 to 99)	73%
Strathy et al <sup>22</sup>	74 (80)	50 (21 to 70)	18 (1 to 50)	10 (9 to 15)	MCH	50 good/fair, 30 poor/fail		74%

\* HHS, Harris hip score; MdA, Merle d'Aubigne score (reported as pain/function/motion or walking); UCLA, University of California, Los Angeles hip rating score (reported as pain/function/motion or walking); MCH, Mayo Clinic hip score

medius and minimus are reinserted directly to the femur. If these are too retracted or atrophied, the fascia lata can be attached to the femur.

Active abduction is avoided for the first six weeks post-operatively, and weight bearing is limited to 50% of body weight during this period. Precautions are taken to prevent flexion beyond 90°, no adduction across the midline and no internal rotation beyond neutral for the first three months. External hip restraint is not routinely recommended, but if the abductors or their repair is tenuous, an abduction limiting brace is used for the first six weeks. Where there was no concern intra-operatively regarding infection, parenteral antibiotics are continued for the first 24 hours. If there was some suspicion however, an antibiotic is continued until the microbiology specimens are clear. If Brooker grade three<sup>19</sup> or above heterotopic ossification was present pre-operatively or if the arthrodesis occurred spontaneously, prophylaxis is used, either with indomethacin, or a single low dose of peri-operative radiotherapy.

### Outcomes of conversion

Conversion of hip arthrodesis to THR is infrequently performed, and information on outcomes limited by the size of reported series and the relatively short periods of follow up (Table I). Only one series reports has results of more than 100 cases<sup>20</sup> and only two series have a minimum of ten years follow up or more.<sup>21,22</sup>

The period of recovery following conversion of hip arthrodesis to THR is longer than that following primary or revision surgery. Functional recovery following primary

and revision THR reaches a plateau at one year.<sup>23</sup> Morsi<sup>24</sup> observed that improvement continued up until three years after conversion surgery, with 11 out of 18 patients not requiring a walking aid at final follow-up and Kilgus et al<sup>25</sup> reported improvement in abductor function up two years. Gait assessment of one case by Bonin et al demonstrated alterations in recorded gait parameters up to 2.5 years following conversion.<sup>26</sup> Persistent limp was reported by Abdel-Aal et al<sup>27</sup> in four out of 15 patients one year following surgery, and this fell to two out of 15 cases after three years. Lubahn et al<sup>28</sup> reported that half of their patients were Trendelenburg negative at one year post surgery but that there had been no change in the use of walking aids compared with their pre-operative use, and this was similar to other results.<sup>29</sup> Brewster et al<sup>30</sup> found that 28 out of 33 cases did not require a walking aid at one year following operation, contrary to the findings of Aderinto et al<sup>31</sup> (15 out of 18 cases), Rittmeister et al<sup>32</sup> (eight out of 13 cases) and Peterson et al,<sup>33</sup> where 87% of patients had a limp and 61% required walking aids. Reikerås et al<sup>34</sup> reported an increase in the use of walking aids in the medium to long term, and Fernandez-Fairen et al<sup>21</sup> reported lower abductor strength in a group of patients converted from arthrodesis to THR compared with primary THR.

In the authors' experience, approximately one third of patients undergoing conversion to THR report complete relief of their presenting complaint, with the remainder reporting good relief,<sup>35</sup> which is similar to the findings in other centres.<sup>33,34</sup> Pain is variably relieved by conversion to THR. Brewster et al<sup>30</sup> reported pain relief in 31 out of 33

cases and in the two cases that did not have relief of knee pain, total knee replacement (TKR) was subsequently required. This experience with respect to knee pain was confirmed by others.<sup>21,36</sup> Rittmeister et al<sup>32</sup> reported reliable relief of back pain (eight out of ten cases) but that knee pain was less reliably relieved (two out of nine cases). This pattern was reversed in the follow up of conversion of bilateral ankylosed hips to THR by Kim et al.<sup>37</sup> Back pain as assessed on a visual analogue scale is reduced after conversion<sup>34</sup> but the use of analgesia to control persistent pain may still be required.<sup>24</sup> Deterioration in reported pain is unusual, occurring in one case in Hardinge et al's<sup>38</sup> series, with 11 reporting slight pain and 42 reporting no pain. Relief of contralateral hip pain was found by Lubahn et al<sup>28</sup> to be less reliably achieved than relief of back and ipsilateral knee pain.

Due to differences in case mix, the correction and persistence of LLD is hard to compare between series. The accepted threshold for correction of LLD without an undue risk of neurovascular injury varies between surgeons. The attempted degree of correction is not reported in these studies, with only the residual LLD reported. LLD correction is more likely to be achieved in a patient with little bone loss, in whom the arthrodesis was performed as an adult than that where the hip had ankylosed spontaneously in a child. LLD is rarely reported as a separate indication for surgery, but Rittmeister et al<sup>32</sup> did give this as a reason in ten out of their 18 cases, with a mean pre-operative LLD of 4.1 cm (0 to 10) improved to a post-operative mean of 1.9 cm (0 to 5). The reported experience is of partial correction of LLD, but with persistent LLD rarely being a cause of dissatisfaction.<sup>21,24,25,27,31,39</sup>

A decrease in the normal range of movement (ROM) is to be expected following this sort of surgery. Patients have pathology that leads to scarring and contraction of soft tissue around the hip, and have often undergone repeated operations and a long standing hip arthrodesis prior to conversion to THR. Fortunately it appears that complete restoration of the ROM is not required for patient satisfaction. Residual flexion deformities were reported by Lubahn et al<sup>28</sup> (mean 7°, 0° to 30°) and Amstutz et al<sup>39</sup> (mean 7.5°, range not given), with flexion ROM of greater than 80° in eight out of 17 cases, and a mean flexion ROM of 78° (45° to 125°) respectively. Flexion ROM consistently in excess of 90° were reported by Abdel-Aal et al<sup>27</sup> and Morsi et al,<sup>24</sup> Kilgus et al<sup>25</sup> and Kempf and Jenny<sup>40</sup> reported mean flexion arcs of 87° and 70°, respectively. Brewster et al<sup>30</sup> reported no difference in the mean flexion achieved when conversion of established arthrodesis (75°) or pseudarthroses (78°) were considered. Hardinge et al<sup>38</sup> reported a total passive ROM of greater than 100° in 48 out of 56 cases and Joshi et al<sup>20</sup> reported good or excellent passive ROM in 79% of cases.

A variety of outcome measures have been used in the assessment of the conversion of hip arthrodesis to THR. The most consistently used is the Harris hip score (HHS).<sup>41</sup> The largest mean improvement in the HHS was demonstrated by Morsi et al,<sup>24</sup> with a mean pre-operative score of 54

(19 to 76) and a mean post-operative score of 93 (81 to 98), which was similar to the experience of Rittmeister et al.<sup>32</sup> The smallest mean improvement was demonstrated by Reikerås et al,<sup>34</sup> with a mean pre-operative score of 69 (51 to 83) and a mean post-operative score of 78 (53 to 93): the other reports lie somewhere between these values.<sup>21,27,31</sup> Peterson et al<sup>33</sup> and Strathy et al<sup>22</sup> utilised the Mayo hip score<sup>42</sup> and reported 52% and 45% good or excellent results respectively, with 26% considered failures by this scoring method in the series by Strathy et al.<sup>22</sup> In studies where a patient's response to the results of the conversion were satisfied or dissatisfied, Kim et al<sup>37</sup> reported satisfaction in all 12 bilateral cases, Brewster et al<sup>30</sup> in 30 out of 33, Hamadouche et al in<sup>36</sup> 41 out of 45 and Rittmeister et al<sup>32</sup> in 11 out of 13 cases.

Reported complications include infection, dislocation, fracture, nerve palsy and heterotopic ossification (HO). The incidence of infection may be related to the indications for previous arthrodesis, with infection as the underlying diagnosis resulting in a higher risk of subsequent infection. In our experience, infections occurred in five out of 26 cases, necessitating revision in two cases,<sup>35</sup> which contrasts with the experience of Joshi et al,<sup>20</sup> who reported a 2% incidence. Dislocation is influenced by surgical technique, the use of constrained acetabular components and inclusion of all dislocations or only revisions for dislocation. Aderinto et al<sup>31</sup> reported no dislocations, but constrained liners were used in three out of 18 cases. Lubahn et al<sup>28</sup> reported one dislocation in 17 cases, Joshi et al<sup>20</sup> five dislocations in 187 cases. Our experience is of four out of 26 cases experiencing dislocation, but only one recurrent and requiring revision.<sup>35</sup> Intra-operative fracture occurred in three out of 12 patients undergoing bilateral conversions<sup>37</sup> and femoral shaft perforation in one out of 17 cases in Lubahn et al's series.<sup>28</sup> Joshi et al<sup>20</sup> reported nerve palsies in 15 out of 187 cases, with three not recovering fully. Kim et al<sup>37</sup> reported nerve palsies in two out of 12 cases, Aderinto et al<sup>31</sup> in two out of 15 cases, and Hardinge et al<sup>38</sup> in one out of 54 cases. Abdel-Aal et al<sup>27</sup> reported one femoral artery injury in 15 cases. HO occurred in seven out of 15 cases in a series where prophylaxis was not used.<sup>31</sup> Other series in which it is described demonstrated frequencies between two in 12 and three in 54 cases.<sup>28,37,38</sup>

Risk factors for failure of conversion in the reported series include age at fusion,<sup>20</sup> age < 50 years at the time of conversion,<sup>22,25,33</sup> multiple previous surgical procedures,<sup>25</sup> performance of the arthrodesis following a fracture,<sup>25</sup> surgical compared with spontaneous arthrodesis,<sup>22,33</sup> and duration of arthrodesis in excess of 30 years.<sup>33</sup> Ten-year survivorship data ranges from 74% (55% to 93%) to 96% (92% to 98%).<sup>20,21,25,35</sup> Two studies have directly compared the results of conversion with those of primary or primary and revision THR. In our experience, the Western Ontario and McMaster Universities osteoarthritis index (WOMAC),<sup>43</sup> Oxford hip score (OHS),<sup>44</sup> satisfaction<sup>45</sup> and University of California, Los Angeles (UCLA) scores<sup>46</sup> were all significantly lower in the conversion than primary THR

group, and lower WOMAC, OHS and satisfaction scores were seen in the conversion than revision THR group, although these results were not significant.<sup>35</sup> Fernandez-Fairen et al<sup>21</sup> reported no difference in functional outcome scores (HHS, OHS and Rosser index matrix<sup>47</sup>) or survivorship when conversion was compared with primary THR at long term follow up. Lower abduction strength was noted, but this did not translate to a difference in the incidence of limp or the use of walking aids.

## Conclusion

Conversion of hip arthrodesis to THR is a procedure that replacement surgeons will encounter in practice, although it remains one of diminishing frequency because of the reluctance of adult patients to consent to primary hip fusion during the last ten to 15 years. Satisfactory results can be achieved with a fully informed patient, who should be made aware of the limitations of conversion, and the potential problems and complications that can be encountered such as persistent pain, LLD, nerve and vessel injury, persistent restriction in ROM, fracture, infection, dislocation and heterotopic ossification. Ten year survivorship of between 74% and 96% has been demonstrated, and in the authors' experience, complete resolution of the presenting complaint is achieved in a third of patients, with partial relief in the remainder. However the results of conversion are inferior to those of primary and revision replacement.

No benefits in any form have been received or will be received from a commercial party related directly or indirectly to the subject of this article.

This paper is based on a study which was presented at the Inaugural 2012 Current Concepts in Joint Replacement® – A Short Course held in conjunction with the 7th International Congress of the Chinese Orthopaedic Association in Beijing, China, 16th November.

## References

- Albee FH. Arthritis Deformans of the Hip: A preliminary report of a new operation. *JAMA* 1908;24:1977–1980.
- Wilson JC. Extra-Articular Fusion of the Tuberculous Hip Joint. *Cal West Med* 1927;27:774–777.
- Ghormley RK. Use of the Anterior Superior Spine and Crest of Ilium in Surgery of the Hip Joint. *J Bone Joint Surg [Am]* 1931;13-A:784–798.
- Trumble HC. A Method of Fixation of the Hip Joint by Means of an Extraarticular Bone Graft. *ANZ J Surg* 1932;1:413–420.
- Brittain HA. Ischio-femoral arthrodesis. *J Bone Joint Surg [Br]* 1948;30-B:642–650.
- Watson-Jones R. Arthrodesis of the osteoarthritic hip. *J Am Med Assoc* 1938;110:278.
- Lange M. Arthrodesis of the hip; review of a series of more than five hundred cases. *J Int Coll Surg* 1958;29:638–643.
- Thompson FR. Combined hip fusion and subtrochanteric osteotomy allowing early ambulation. *J Bone Joint Surg [Am]* 1956;38-A:13–22.
- No authors listed. Proceedings and Reports of Universities, Colleges, Councils and Associations. *J Bone Joint Surg [Br]* 1956;38-B:583–603.
- Schneider R. Hip arthrodesis with the cobra head plate and pelvic osteotomy. *Reconstr Surg Traumatol* 1974;14:1–37.
- Sponseller PD, McBeath AA, Perpich M. Hip arthrodesis in young patients. A long-term follow-up study. *J Bone Joint Surg [Am]* 1984;66-A:853–859.
- Callaghan JJ, Brand RA, Pedersen DR. Hip arthrodesis. A long-term follow-up. *J Bone Joint Surg [Am]* 1985;67-A:1328–1335.
- Sofue M, Kono S, Kawaji W, Homma M. Long term results of arthrodesis for severe osteoarthritis of the hip in young adults. *Int Orthop* 1989;13:129–133.
- Schafroth MU, Blokzijl RJ, Haverkamp D, Maas M, Marti RK. The long-term fate of the hip arthrodesis: does it remain a valid procedure for selected cases in the 21st century? *Int Orthop* 2010;34:805–810.
- Girdlestone GR. Discussion on the Late Results of Operation for Chronic Painful Hip. *Proc R Soc Med* 1926;19:48–49.
- Edwards BN, Tullos HS, Noble PC. Contributory factors and etiology of sciatic nerve palsy in total hip arthroplasty. *Clin Orthop Relat Res* 1987;218:136–141.
- Davis JB. The muscle-pedicle bone graft in hip fusion. *J Bone Joint Surg [Am]* 1954;36-A:790–799.
- Panagiotopoulos KP, Robbins GM, Masri BA, Duncan CP. Conversion of hip arthrodesis to total hip arthroplasty. *Instr Course Lect* 2001;50:297–305.
- Brooker AF, Bowerman JW, Robinson BG, Riley LH Jr. Ectopic ossification following total hip replacement: Incidence and a method of classification. *J Bone Joint Surg [Am]* 1973;55-A:1629–1632.
- Joshi AB, Markovic L, Hardinge K, Murphy JCM. Conversion of a fused hip to total hip arthroplasty. *J Bone Joint Surg [Am]* 2002;84-A:1335–1341.
- Fernandez-Fairen M, Murcia-Mazón A, Torres A, Querales V, Murcia A. Is total hip arthroplasty after hip arthrodesis as good as primary arthroplasty? *Clin Orthop Relat Res* 2011;469:1971–1983.
- Strathy GM, Fitzgerald RHJ. Total hip arthroplasty in the ankylosed hip. A ten-year follow-up. *J Bone Joint Surg [Am]* 1988;70-A:963–966.
- Field RE, Cronin MD, Singh PJ. The Oxford hip scores for primary and revision hip replacement. *J Bone Joint Surg [Br]* 2005;87-B:618–622.
- Morsi E. Total hip arthroplasty for fused hips; planning and techniques. *J Arthroplasty* 2007;22:871–875.
- Kilgus DJ, Amstutz HC, Wolgin MA, Dorey FJ. Joint replacement for ankylosed hips. *J Bone Joint Surg [Am]* 1990;72-A:45–54.
- Bonin SJ, Eltoukhy MA, Hodge WA, Asfour SS. Conversion of fused hip to total hip arthroplasty with presurgical and postsurgical gait studies. *J Arthroplasty* 2012;27:493.
- Abdel-Aal A, Bakr H, Mahran M. Total hip arthroplasty for fused hips. *Orthopedics* 2010;33:400–404.
- Lubahn JD, Everts CM, Feltner JB. Conversion of ankylosed hips to total hip arthroplasty. *Clin Orthop Relat Res* 1980;153:146–152.
- Schäfer D, Dick W, Morscher E. Total hip arthroplasty after arthrodesis of the hip joint. *Arch Orthop Trauma Surg* 2000;120:176–178.
- Brewster RC, Coventry MB, Johnson EW. Conversion of the arthrodesed hip to a total hip arthroplasty. *J Bone Joint Surg [Am]* 1975;57-A:27–30.
- Aderinto J, Lulu OB, Backstein DJ, Safir O, Gross AE. Functional results and complications following conversion of hip fusion to total hip replacement. *J Bone Joint Surg [Br]* 2012;94-B(Suppl):36–41.
- Rittmeister M, Starker M, Zichner L. Hip and Knee Replacement After Longstanding Hip Arthrodesis. *Clin Orthop Relat Res* 2000;371:136–145.
- Peterson ED, Nemanich JP, Altenburg A, Cabanela ME. Hip arthroplasty after previous arthrodesis. *Clin Orthop Relat Res* 2009;467:2880–2885.
- Reikerås O, Bjerkreim I, Gundersson R. Total hip arthroplasty for arthrodesed hips. 5- to 13-year results. *J Arthroplasty* 1995;10:529–531.
- Richards CJ, Duncan CP. Conversion of hip arthrodesis to total hip arthroplasty: survivorship and clinical outcome. *J Arthroplasty* 2011;26:409–413.
- Hamadouche M, Kerboull L, Meunier A, Coupied JP, Kerboull M. Total hip arthroplasty for the treatment of ankylosed hips: a five to twenty-one-year follow-up study. *J Bone Joint Surg [Am]* 2001;83-A:992–998.
- Kim YL, Shin SI, Nam KW, et al. Total hip arthroplasty for bilaterally ankylosed hips. *J Arthroplasty* 2007;22:1037–1041.
- Hardinge K, Williams D, Etienne A, MacKenzie D, Charnley J. Conversion of fused hips to low friction arthroplasty. *J Bone Joint Surg [Br]* 1977;59-B:385–392.
- Amstutz HC, Sakai DN. Total joint replacement for ankylosed hips. Indications, technique, and preliminary results. *J Bone Joint Surg [Am]* 1975;57-A:619–625.
- Kempf I, Jenny JY. Total prosthesis after ankylosis of the hip joint. Report of 22 cases. *Int Orthop* 1991;15:239–243.
- Harris WH. Traumatic arthritis of the hip after dislocation and acetabular fractures: treatment by mold arthroplasty. An end-result study using a new method of result evaluation. *J Bone Joint Surg [Am]* 1969;51-A:737–755.
- Kavanagh BF, Fitzgerald RH. Clinical and roentgenographic assessment of total hip arthroplasty. A new hip score. *Clin Orthop Relat Res* 1985;193:133–140.
- Bellamy N, Buchanan WW, Goldsmith CH, Campbell J, Stitt LW. Validation study of WOMAC: a health status instrument for measuring clinically important patient relevant outcomes to antirheumatic drug therapy in patients with osteoarthritis of the hip or knee. *J Rheumatol* 1988;15:1833–1840.
- Dawson J, Fitzpatrick R, Carr A, Murray DW. Questionnaire on the perceptions of patients about total hip replacement. *J Bone Joint Surg [Br]* 1996;78-B:185–190.
- Katz JN, Phillips CB, Baron JA, et al. Association of hospital and surgeon volume of total hip replacement with functional status and satisfaction three years following surgery. *Arthritis Rheum* 2003;48:560–568.
- Amstutz HC, Thomas BJ, Jinnah R, Kim W, Grogan T, Yale C. Treatment of primary osteoarthritis of the hip. A comparison of total joint and surface replacement arthroplasty. *J Bone Joint Surg [Am]* 1984;66-A:228–241.
- Rosser RM, Watts VC. The measurement of hospital output. *Int J Epidemiol* 1972;1:361–368.