

The Outside-In, Percutaneous Release of the Medial Collateral Ligament for Knee Arthroscopy



Thomas E. Moran, M.D., Alex Demers, B.S., John T. Awowale, M.D.,
Brian C. Werner, M.D., and Mark D. Miller, M.D.

Abstract: The outside-in, percutaneous release of the medial collateral ligament (MCL) is a technique used to increase the medial tibiofemoral joint space during arthroscopy to facilitate the use of instrumentation and improve visualization without causing iatrogenic cartilage damage. A recent systematic review of the literature has shown this technique to be efficacious and safe, with no evidence of associated short- or long-term complications. This technique has been used for this indication by the senior author without requiring any deviation from our institution's standard protocol for knee arthroscopy. In an attempt to standardize this technique's utilization and allow for further evaluation in the literature, the senior author's method for this percutaneous, outside-in approach of "pie crusting" the MCL is described.

Arthroscopy remains the most widely performed procedure within orthopaedic surgery for the treatment and evaluation of intra-articular knee pathology.¹ Complete access to certain areas of the knee, specifically the posterior medial compartment, can present a technical challenge during arthroscopy in patients with a tight tibiofemoral joint space. In scenarios with limited visualization or room for instrumentation, surgeons risk inadequately addressing pathology or causing iatrogenic cartilage damage. The percutaneous, outside-in approach of "pie crusting" the medial collateral ligament (MCL) is 1 method described in the literature by which surgeons may increase the

effective medial joint space of the knee intraoperatively to reduce these risks.²

Despite concerns regarding the associated morbidity of performing MCL release during knee arthroscopy, a recent systematic review of the current literature showed this technique to be an efficacious way of increasing the medial joint space of the knee without causing any significant short- or long-term complications.² With additional evidence emerging that supports the use of this technique, further description and standardization of its performance should be established to facilitate its future use and examination in the literature.³

The technique described in this article is used routinely at our institution in situations in which valgus stress proves to be insufficient in adequately increasing the medial joint space of the knee. The purpose of this Technical Note is to describe the senior author's current surgical technique of performing a percutaneous, outside-in, pie-crusting of the MCL, in which bracing is not typically performed postoperatively.

Surgical Technique

Surgical Setup and Preoperative Examination

The patient is positioned supine on the operating room table in the standard arthroscopy position. A lateral arthroscopic stress post (Allen Medical Systems, Acton, MA) is placed proximal to the knee, around the level of the tourniquet, to allow for valgus stress to be applied intraoperatively. A nonsterile tourniquet (Stryker Corporation, Kalamazoo, MI) is positioned

From the University of Virginia Department of Orthopaedic Surgery, Charlottesville, Virginia, U.S.A.

The authors report the following potential conflicts of interest or sources of funding: B.C.W. reports other from Arthrex, Biomet, Integra LifeScience; board or committee member, American Orthopaedic Society for Sports Medicine, American Shoulder and Elbow Surgeons. M.D.M reports other from Arthrex; board or committee member, American Orthopaedic Society for Sports Medicine, Miller Orthopaedic Review Enterprises; publishing royalties, financial or material support, Saunders/Mosby-Elsevier, Wolter Kluwer Health, Lippincott Williams & Wilkins. Full ICMJE author disclosure forms are available for this article online, as [supplementary material](#).

Received September 26, 2019; accepted November 17, 2019.

Address correspondence to Dr. Mark D. Miller, M.D., 515 Ray C. Hunt Dr, Ste 1100, Charlottesville, VA 22903, U.S.A. E-mail: mdm3p@virginia.edu

© 2020 by the Arthroscopy Association of North America. Published by Elsevier. This is an open access article under the CC BY-NC-ND license (<http://creativecommons.org/licenses/by-nc-nd/4.0/>).

2212-6287/191176

<https://doi.org/10.1016/j.eats.2019.11.008>

high on the thigh, and the operative lower extremity is prepared and draped in a standard sterile fashion.

Surgical Approach

A standard anterolateral viewing portal and anteromedial instrumentation portal are created at the joint line, lateral and medial to the patellar tendon, respectively. The knee joint is insufflated with normal saline, and a 4.0-mm, 30° arthroscope (Stryker Corporation) is used to visually inspect the intra-articular anatomy in a standard manner for diagnostic knee arthroscopy.⁴ Depending on the particular surgical indication, a variety of instrumentation may be used to address the respective pathology.

While using the 30° arthroscope to inspect the medial compartment of the knee, the knee is brought into 30° of flexion. A valgus force is then applied to the knee against the lateral arthroscopic stress post by the surgeon's hip or an assistant to stretch the MCL fibers and increase the medial joint space. If it is determined that medial access is restricted in allowing adequate visualization of pathology or safely facilitating instrumentation without causing iatrogenic cartilage damage, percutaneous release of the MCL may then be performed.

Percutaneous Release of the MCL

A detailed video of the technique is provided in [Video 1](#). First, bony landmarks are found by palpation, and the medial epicondyle and tibial plateau are marked. Using the anatomy of the superficial MCL described by LaPrade et al.,⁵ a mark is made in the posterior aspect of the MCL, just proximal to the joint line. This point, which represents the location the percutaneous release is to be performed, is measured 1.5 cm posterior and slightly distal to the medial epicondyle ([Figure 1](#)). To further ensure accurate needle placement, insertion of the arthroscope into the anterolateral portal can be used for transillumination of the joint space ([Figure 2](#)). Next, a constant valgus force is applied to the knee by the surgeon or an assistant. Using an 18-gauge spinal needle (Becton Dickinson, Franklin Lakes, NJ), the skin is penetrated in only 1 location at the position previously marked ([Figure 3](#)). While the needle remains penetrating the skin, the surgeon inserts and withdraws the needle from the superficial MCL while changing the orientation of the spinal needle in an anterior to posterior direction ([Figure 4](#)). The number of sequential insertions and withdrawals of the needle required to perform an adequate release varies between patients. While the percutaneous release is being performed with the spinal needle, the medial compartment is visualized simultaneously through the arthroscopic camera to ensure the appropriate opening of the joint space ([Figure 5](#)). Typically, the release is represented by an audible pop

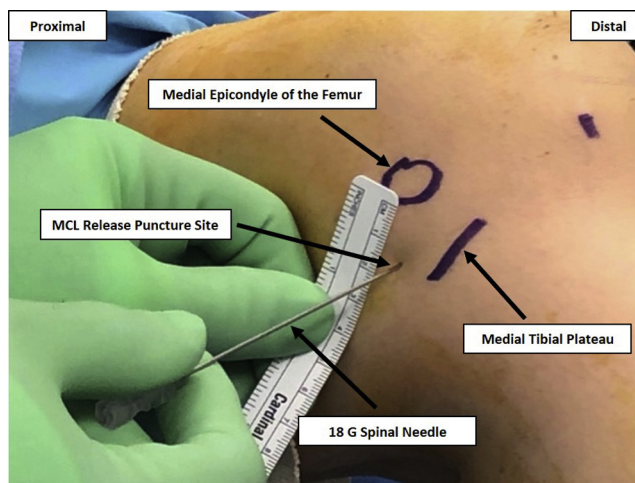


Figure 1. An image of the medial left knee illustrates the landmarks used and the measurements made to identify the desired location for the percutaneous medial collateral ligament (MCL) release. The medial epicondyle of the femur and the medial tibial plateau are located by direct palpation and marked. The optimal location for the performance of the percutaneous release can then be measured relative to these landmarks with the use of a ruler.

that corresponds with an acute increase in medial compartment joint space. This can be confirmed by simultaneous intra-articular visualization ([Figure 6](#)). On examination, this occurrence typically corresponds with new grade 1 laxity of the MCL. After this point, no further fenestration is performed using the spinal

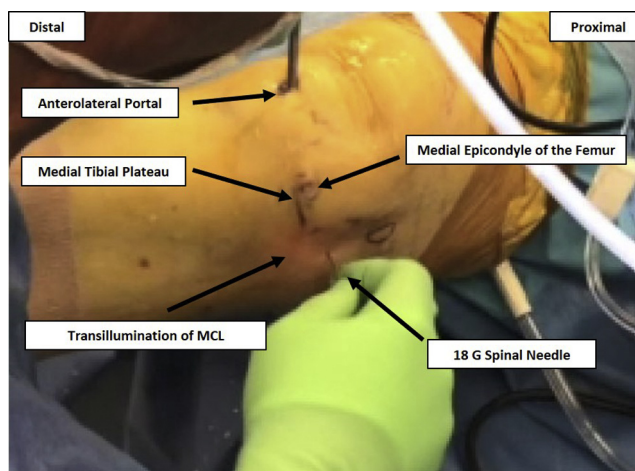


Figure 2. Before performance of the percutaneous release, the arthroscope should be positioned in the anterolateral portal to permit adequate visualization of the medial compartment, while also providing transillumination of the medial joint space to further ensure accurate needle placement with respect to the marked landmarks and native knee anatomy. This setup is shown by an image before the percutaneous release of a right knee being performed. Abbreviation: MCL, medial collateral ligament.

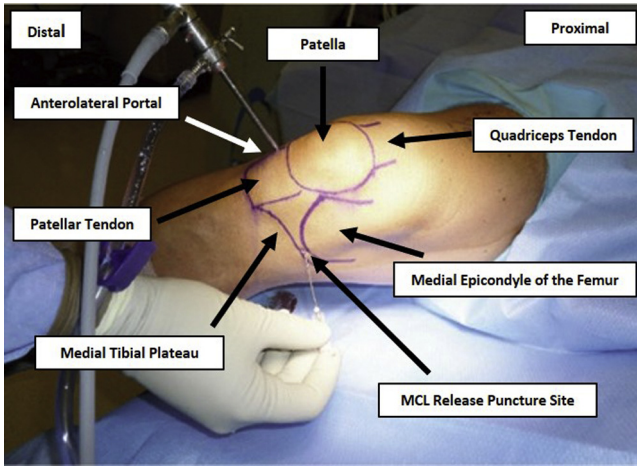


Figure 3. After determining the optimal location for the performance of the medial collateral ligament (MCL) release, an 18-gauge spinal needle can be introduced superficially within 1 location, and translated subcutaneously, as indicated in the image of a right knee.

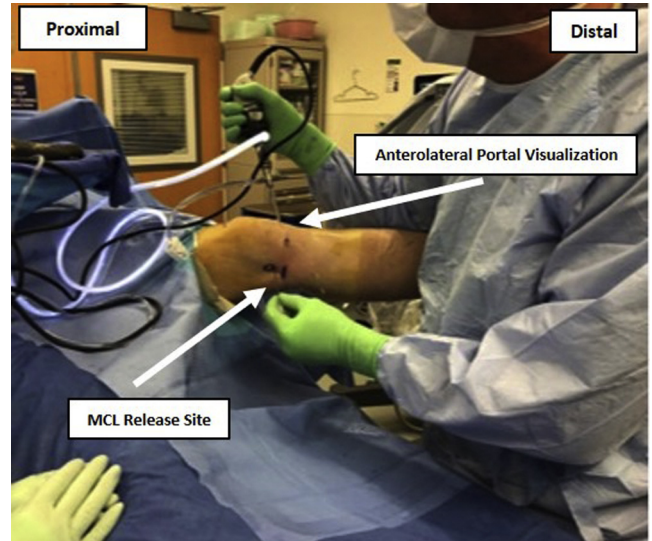


Figure 5. The medial joint space of the knee should be visualized simultaneously during the performance of this technique to ensure that an appropriate release of the medial collateral ligament (MCL) occurs, as illustrated in the image during a procedure on the left knee.

needle. The percutaneous release is complete, and the surgeon is able to proceed with the remainder of the knee arthroscopic procedure.

Postoperative Rehabilitation

All surgeries are performed on an outpatient basis. For a standard diagnostic arthroscopy or arthroscopy with concomitant meniscectomy, loose body removal, or chondroplasty, the knee is not immobilized with a

brace postoperatively. In the instance of a meniscal repair or meniscus root repair, the patient is placed in a hinged knee brace (DJO Global, Lewisville, TX) that prevents flexion beyond 90° for 6 weeks postoperatively. Both of these protocols regarding postoperative bracing are in accordance with the standard

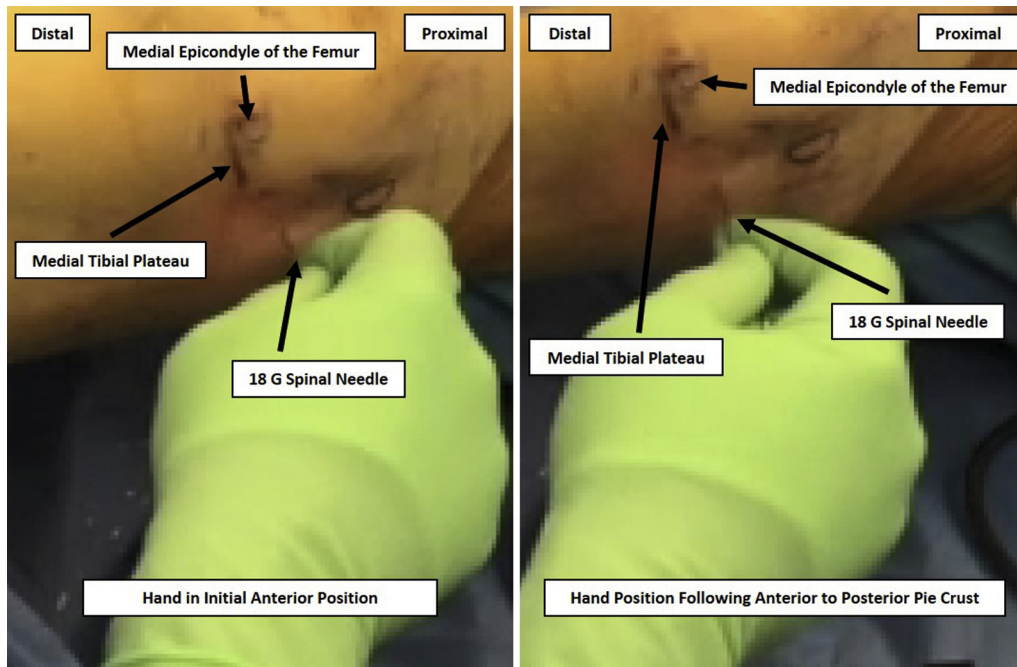


Figure 4. Subcutaneous fenestration is performed in an anterior to posterior direction to pie crust the medial collateral ligament (MCL), allowing for release. Depicted are the initial (left) and final (right) positions of the hand showing the lateral rotation of the wrist necessary for needle translation in the pie crust maneuver during release of a right knee MCL.

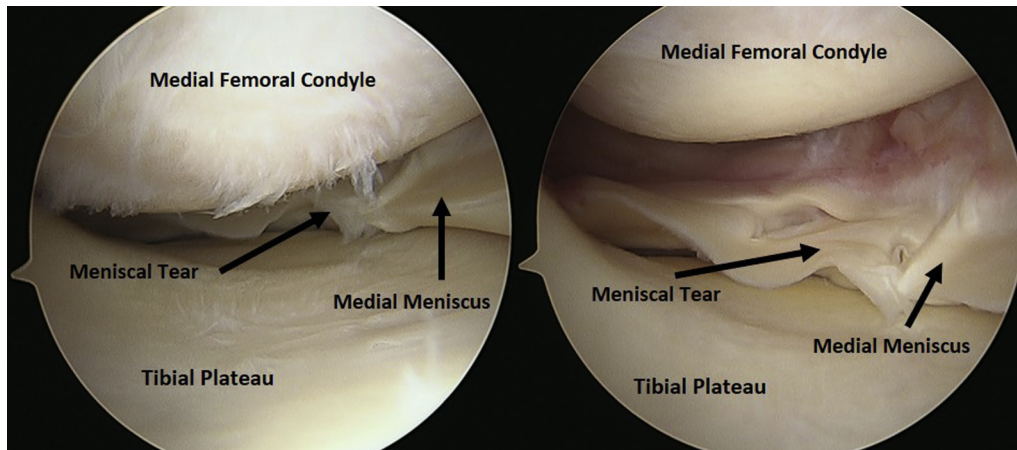


Figure 6. Intra-articular visualization through the anterolateral portal is used to confirm the adequacy of the release performed on the medial collateral ligament (MCL) and can be used to ensure appropriate access to the injury of interest. This image provides an intra-articular view of the medial compartment width before (left) and width generated after performance of the MCL release (right) on the right knee.

postoperative protocol at our institution, regardless of whether a concomitant percutaneous MCL release is performed. For a general knee arthroscopy with partial medial meniscectomy, loose body removal, or shaving chondroplasty, patients are allowed to bear weight on the operative extremity without a brace, and a series of progressive exercises are used to improve range of motion and strengthen the quadriceps muscles. In our protocol, patients typically progress from body weight exercises and simple movements emphasizing active-assisted range of motion stretching toward more complex, closed-kinetic chain exercises. There are no alterations made to the typical rehabilitation instructions or protocol in patients who undergo percutaneous release. Serial functional evaluation is made during follow-up clinic appointments occurring 2 and 6 weeks postoperatively. At each clinic follow-up appointment, manual valgus stress test with the knee in 30° of flexion may be performed without additional precaution to evaluate for laxity if it is suspected clinically. Patients are allowed to progress to activities as tolerated, and a gradual return to sports is allowed when they have achieved full range of motion, are without effusion, and can successfully complete sports-specific drills.

Discussion

The outside-in, percutaneous release of the MCL is an emerging technique for increasing the medial tibiofemoral joint space during knee arthroscopy to improve access for a variety of intra-articular pathologies. As with any surgical intervention, various risks and benefits exist regarding its use (Table 1). Several studies, including a recent systematic review, have shown this technique to be safe and efficacious, but further description and standardization of this technique are required to optimize its clinical use and future study.

Commonly, MCL release has been described in an outside-in percutaneous manner, in which a needle is used to disrupt the fibers of the superficial MCL.^{3,6-11} Alternatively, Javidan et al.¹² described a method in which a banana blade was used to perform an arthroscopic release of the deep MCL. Chung et al.⁹ also described a method in which they performed an open release of the distal insertion of the superficial MCL with a periosteal elevator. In descriptions in which a needle was used percutaneously to generate joint space widening, methods of fiber disruption included inflicting multiple punctures in the MCL^{7,8,10,11,13} and division of fibers.^{3,6,14} We advocate for the use of a single superficial puncture site with additional subcutaneous disruption of fibers, as it minimizes the invasiveness of the procedure while allowing for control of joint space widening under direct visualization. Furthermore, the use of a spinal needle offers an inexpensive and readily available instrument, without additional resources needed for performing the release.

Studies examining the percutaneous release of the MCL also notably differ in the location of the MCL release, which has varied from the femoral side of the MCL,⁷ the tibial side of the MCL,¹⁴ or at the joint line.^{11,13} One study examining outcome after percutaneous MCL release even made no mention of where

Table 1. Risks and benefits of percutaneous medial collateral ligament (MCL) release

| Benefits | Risks |
|---|--|
| Improves visualization of intra-articular pathology | Mild postoperative pain at the site of release |
| Reduces chance of iatrogenic cartilage damage | Risk of damage to saphenous nerve and greater saphenous vein |
| | Chance of iatrogenic grade 1 MCL injury |

the release was performed.¹⁵ Thus far, it is unclear whether the location of the release makes a difference in the amount of additional joint space opening, although all have been performed safely without causing significant short- or long-term morbidity to patients.^{2,7,11,13,15} Future research is needed to quantify the additional joint space opening provided by percutaneous MCL release and document its return to normal postoperatively.

Finally, a lack of consensus exists for postoperative bracing after the release. Given the paucity of literature examining this technique, the decision to brace has largely been determined by the degree of conservatism of the respective surgeon. Those who used a hinged knee brace postoperatively acknowledged their decision to be precautionary, as no literature currently shows that bracing is warranted.^{3,7,9,13} As no evidence currently exists supporting postoperative bracing, we do not advocate for routine bracing, as this adds cost to patients and the health care system in the absence of demonstrated value.

This Technical Note presents a description of the senior author's intra- and postoperative protocol for percutaneous MCL release, which has been used successfully to increase access to the medial tibiofemoral joint space during arthroscopy. Further studies are needed to determine the optimal technique for MCL release and to standardize its use for clinical practice.

References

1. Mordecai SC, Al-Hadithy N, Ware HE, Gupte CM. Treatment of meniscal tears: An evidence based approach. *World J Orthop* 2014;5:233-241.
2. Moran TE, Awowale JT, Werner BC, Fox MA, Miller MD. Associated morbidity after the percutaneous release of the medial collateral ligament for knee arthroscopy. *Arthrosc* 2020;36:891-900.
3. Polat B, Deniz A, Polat AE, et al. Objective measurement of medial joint space widening with percutaneous "pie crust" release of medial collateral ligament during knee arthroscopy. *J Knee Surg* 2020;33:94-98.
4. Ward BD, Lubowitz JH. Basic knee arthroscopy part 3: Diagnostic arthroscopy. *Arthrosc Tech* 2013;2:e503-e505.
5. LaPrade RF, Engebretsen AH, Ly TV, Johansen S, Wentorf FA, Engebretsen L. The anatomy of the medial part of the knee. *J Bone Jt Surg Am* 2007;89:2000-2010.
6. Li X, Selby RM, Newman A, O'Brien SJ. Needle assisted arthroscopic clysis of the medial collateral ligament of the knee: A simple technique to improve exposure in arthroscopic knee surgery. *Orthop Rev (Pavia)* 2013;5:e38.
7. Jeon SW, Jung M, Chun YM, et al. The percutaneous pie-crusting medial release during arthroscopic procedures of the medial meniscus does neither affect valgus laxity nor clinical outcome. *Knee Surg Sport Traumatol Arthrosc* 2018;26:2912-2919.
8. Atoun E, Debbi R, Lubovsky O, Weiler A, Debbi E, Rath E. Arthroscopic trans-portal deep medial collateral ligament pie-crusting release. *Arthrosc Tech* 2013;2:e41-43.
9. Chung KS, Ha JK, Ra HJ, Kim JG. Does release of the superficial medial collateral ligament result in clinically harmful effects after the fixation of medial meniscus posterior root tears? *Arthroscopy* 2017;33:199-208.
10. Bosch U. Die perkutane Perforation der posteromedialen Kapsel-Band-Strukturen zur Vermeidung von Knorpel-schäden bei arthroskopischen Eingriffen am Innenmeniskushinterhorn in engen Gelenken. *Oper Orthop Traumatol* 2006;18:481-484.
11. Lons A, Boureau F, Drumez E, Pasquier G, Putman S. Does medial collateral ligament pie-crusting induce residual laxity in arthroscopic management of medial meniscus tears? A prospective study of 40 cases. *Orthop Traumatol Surg Res* 2018;104:707-711.
12. Javidan P, Ahmed M, Kaar SG. Arthroscopic release of the deep medial collateral ligament to assist in exposure of the medial tibiofemoral compartment. *Arthrosc Tech* 2014;3(6):e699-e701.
13. Fakioglu O, Ozsoy MH, Ozdemir HM, Yigit H, Cavusoglu AT, Lobenhoffer P. Percutaneous medial collateral ligament release in arthroscopic medial meniscectomy in tight knees. *Knee Surgery, Sport Traumatol Arthrosc* 2013;21:1540-1545.
14. Roussignol X, Gauthe R, Rahali S, Mandereau C, Courage O, Duparc F. Opening the medial tibiofemoral compartment by pie-crusting the superficial medial collateral ligament at its tibial insertion: A cadaver study. *Orthop Traumatol Surg Res* 2015;101:529-533.
15. Claret G, Montañana J, Rios J, et al. The effect of percutaneous release of the medial collateral ligament in arthroscopic medial meniscectomy on functional outcome. *Knee* 2016;23:251-255.