

57–66

Unilateral facet dislocations: Is surgery really the preferred option?

Authors Marcel Dvorak¹, Alexander R Vaccaro², Jeffrey Hermsmeyer³, Daniel C Norvell³

Institutions ¹ University of British Columbia, Blusson Spinal Cord Centre, Vancouver BC, Canada

² Thomas Jefferson University and the Rothman Institute, Philadelphia PA, USA

³ Spectrum Research Inc., Tacoma, Washington, USA

ABSTRACT

Study design: Systematic review.

Objective: To compare the safety and effectiveness of initial surgery versus nonoperative management of unilateral facet dislocations with or without fractures.

Summary of background: Unilateral facet injuries represent between 6%–10% of all cervical spine injuries and yet optimal treatment for these injuries has not been established. The surgeon is faced with the decision of whether to manage the injury operatively or nonoperatively. Providing evidence to support this decision is necessary and is the rationale behind this article.

Methods: A systematic review of the English language literature was undertaken for articles published between 1970 and August 2009. Electronic databases and reference lists of key articles were searched to identify studies evaluating surgery and nonoperative management of unilateral facet dislocations. Bilateral facet dislocations, isolated facet fractures (without dislocation), and complete spinal cord injuries were excluded. Two independent reviewers assessed the level of evidence quality using the GRADE criteria and disagreements were resolved by consensus.

Results: We identified six articles meeting our inclusion criteria. Treatment failure, neurological deterioration, and persistent pain occurred more frequently in patients treated nonoperatively versus patients treated with surgery. Surgical patients experienced infections and surgical related complications not experienced by those managed nonoperatively. Patients treated surgically after failed nonoperative management also experienced better outcomes than those who continued to be managed nonoperatively.

Conclusion: When faced with a patient requesting treatment recommendations for their acute unilateral facet dislocation, the surgeon can state that treatment failure, persistent pain, and neurological deterioration occur more frequently with nonoperative treatment based on the available literature. Ultimately it will be the preference of the patient that will decide between these two treatment approaches.

This systematic review was funded by AOSpine.

STUDY RATIONALE AND CONTEXT

Unilateral facet injuries represent 6%–10% of all cervical spine injuries and yet optimal treatment for these injuries is frequently in dispute. When faced with a patient in the emergency room, the treating spine surgeon is often asked to recommend either initial surgery or nonoperative treatment based on his/her experience and understanding of the literature. While patient preference is often a strong deciding factor, it is incumbent upon the surgeon to provide the patient with therapeutic advice that is most likely to return the patient to their pre-injury health status with the lowest risk of complications. This first decision, whether to operate or not, is thus very important. Often this decision is made not in the controlled environment of an elective office or clinic but more frequently in the emergency department and outside regular hours and may be influenced by resource availability, surgeon training, and local practice patterns. Providing evidence to support this decision and subsequent decisions, should initial nonoperative treatment fail, is necessary and is the rationale behind this article.

OBJECTIVES

To compare the safety and efficacy of initial surgery versus nonoperative management of unilateral facet dislocations with or without fractures and, among patients who experience failed nonoperative management, to compare outcomes of those who receive surgery versus those who do not receive surgery.

MATERIALS AND METHODS

Study design: Systematic review.

Sampling: Search: PubMed, Cochrane collaboration database, and National Guideline Clearinghouse databases; bibliographies of key articles. Dates searched: 1970 to August 2009.

Inclusion criteria: (1) Unilateral facet dislocations with or without fractures, (2) Adults 18 years and older, (3) Studies including ten or more patients in either arm

Exclusion criteria: (1) Bilateral facet dislocation, (2) complete spinal cord injury, (3) isolated fracture without dislocation, (3) less than ten subjects per treatment, (4) data on unilateral facet dislocations not presented separately from other injuries.

Outcomes: Failed treatment, neurological deterioration, persistent pain, wound or surgical site infection, and complications (health-related or surgery-specific).

Analysis: Descriptive statistics.

For more details see web appendix at www.aospine.org/ebsj.

RESULTS

We identified six articles meeting our inclusion criteria (**Fig 1**). Four studies evaluated operative or nonoperative treatment for unilateral facet dislocation. Two studies evaluated failed nonoperative treatment (inability to achieve and maintain reduction, a progression in neurological symptoms, or the presence of late pain and/or instability) that did or did not lead to future surgical management.

Operative versus nonoperative treatment of unilateral facet dislocations (Table 1 and Fig 2)

- One-hundred-and-seventy-six patients undergoing operative or nonoperative treatment were identified.
- Treatment failure rates were higher in nonoperatively managed patients (80%) than surgically managed patients (2.6%) [1–4].
- Neurological deterioration happened infrequently, but occurred more after nonoperative treatment (5%) versus operative treatment (0%) [1, 2, 4].

- Posttreatment persistent pain occurred more frequently in nonoperative treatment (30%) than it did in operative treatment (10.3%) [1–4].
- Outcomes were not reported in the nonoperative treatment studies, but for operative treatment were reported as surgical site or deep wound infection (7.8%) and general health or surgery specific complications (13.8%) [1–4].

Failed nonoperative treatment that did or did not lead to future surgical management (Table 2)

- Forty-eight patients that had a failed nonoperative treatment who continued to be managed nonoperatively (n=28) or who subsequently went on to future surgery (n=20) were identified.
- Failed anatomical reduction rates were higher among patients with continued nonoperative management (100%) versus those who underwent surgical management (30%) [5, 6].
- Neurological deterioration occurred more frequently in continued nonoperative treatment (10.7%) versus operative treatment (0%) [5, 6].
- Posttreatment persistent pain occurred more frequently in continued nonoperative treatment (70%) than it did in operative treatment (5%) [5, 6].

Fig 1 Flow chart showing results of literature search

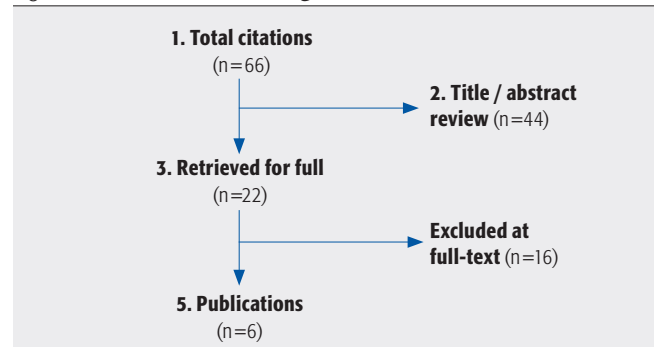


Fig 2 Outcomes rates comparing surgical to nonoperative management of unilateral facet dislocations

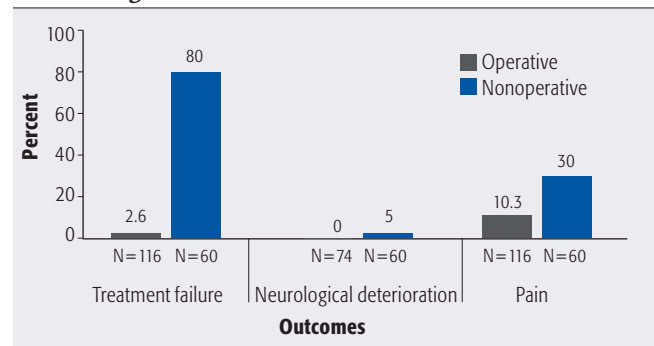


Table 1 Subject characteristics of studies evaluating operative versus nonoperative treatment for unilateral facet dislocation

Outcomes	Operative N=116				Nonoperative N=60			
	Studies (n)	Patients (n)	Results (mean)	Results (range)	Studies (n)	Patients (n)	Results (mean)	Results (range)
Treatment failure*	4	116	2.6%	0–6%	2	60	80%	77–82%
Neurological deterioration [†]	3	74	0%	0%	2	60	5%	0–9%
Wound or surgical infection	4	116	7.8%	0–12%	NR	NR	NR	NR
Persistent pain	4	116	10.3%	0–14%	2	60	30%	27–32%
Complications [‡]	4	116	13.8%	0–29%	NR	NR	NR	NR

* Defined in operative treatment as future subluxation, nonunion, or reoperation; defined in nonoperative treatment as failed anatomical reduction which may or may not lead to future surgical management.

[†] Defined as a negative change in neurological status from pre to postoperative.

[‡] Including general health complications such as pneumonia and surgery-specific complications such as nerve palsy, dysphagia, difficulty swallowing, and wound site drainage.

Table 2 Subject characteristics of failed nonoperative treatment that may or may not lead to future surgical management

Outcomes	Operative N=20				Nonoperative N=28			
	Studies (n)	Patients (n)	Results (mean)	Results (range)	Studies (n)	Patients (n)	Results (mean)	Results (range)
Failed anatomical reduction	2	20	30%	20–40%	2	28	100%	100%
Neurological deterioration*	2	20	0%	0%	2	28	10.7%	0–17%
Persistent pain	2	20	5%	0–10%	1	10	70%	70%

* Defined as a negative change in neurological status from pre to postoperative.

EVIDENCE SUMMARY

Question 1: Compare the safety and efficacy of initial surgery versus nonoperative management of unilateral facet dislocations

Outcomes	Strength of evidence				Conclusions/comments
1. Treatment failure	Very low	Low	Moderate	High	Treatment failure rates are higher in nonoperatively managed patients compared to surgically managed patients.
2. Neurological deterioration	Very low	Low	Moderate	High	Neurological deterioration happened infrequently, but occurred more frequently in nonoperative treatment versus operative treatment.
3. Wound or surgical infection	Very low	Low	Moderate	High	Rate of infection ranged from 0%–12% in surgically managed patients.
4. Posttreatment pain	Very low	Low	Moderate	High	Long term persistent pain occurred more frequently in nonoperative treatment compared to operative treatment.
5. Complications	Very low	Low	Moderate	High	Complication rates occurred at a mean of 13.8% in surgically managed patients.

Details about the determination of strength of evidence can be found in the web appendix at www.aospine.org/ebsj

Question 2: Compare the safety and effectiveness of surgery versus nonoperative management after failed nonoperative management

Outcomes	Strength of evidence				Conclusions/Comments
1. Failed anatomical reduction	Very low	Low	Moderate	High	Failed anatomical reduction rates are higher in nonoperatively managed patients compared to surgically managed patients.
2. Neurological deterioration	Very low	Low	Moderate	High	Neurological deterioration was only reported in patients who received continued nonoperative management at mean of 10.7%.
3. Posttreatment pain	Very low	Low	Moderate	High	Long term persistent pain occurred more frequently in continued nonoperative treatment compared to operative treatment.

Details about the determination of strength of evidence can be found in the web appendix at www.aospine.org/ebsj

DISCUSSION

- In six case series that evaluated isolated unilateral facet dislocations, treatment failure, neurological deterioration, and persistent pain occurred more frequently in patients treated nonoperatively versus patients treated with surgery. Surgical patients experience infections and surgical related complications that those treated nonoperatively do not experience. Patients treated operatively after failed nonoperative management also experience better outcomes than those who continue to be managed (**Tables 3–4**).
- The existing literature reporting outcomes on the treatment of unilateral facet dislocations is limited to case series. No studies were identified that compared operative to nonoperative management in the same patient population. Pooled rates of treatment failure from these case series are remarkably higher in patients who are treated nonoperatively, but the potential for selection bias in this comparison is likely and therefore conclusions must be made with caution. Comparative studies are necessary to establish the efficacy of operative versus nonoperative management of these injuries.
- Although it is the facet that ultimately generates difficulty for realignment, the disc at the injured motion segment may also influence surgeon's decision making. Three of six studies reported surgical management of disc pathology.
 - A discectomy at the injured level was performed in order to facilitate a fusion procedure regardless of whether or not disc herniation was documented by MRI [1].
 - Discectomy was performed in five patients that had disc herniation as detected by MRI [4].
 - The disc was excised if there was disc material dislodged into spinal canal [2].
- Although the quality of publications is lacking, there is remarkable consistency in the results across these studies. When faced with a patient requesting treatment recommendations for their acute unilateral facet dislocation, the surgeon can state that treatment failure, persistent pain, and neurological deterioration consistently occur more frequently with nonoperative treatment based on the available literature. It must be acknowledged that surgical treatment carries with it a complication rate likely around 10%–15%. Similarly, there is consistent support for surgical treatment following failure of nonoperative care. Ultimately it will be the preference of the patient that will decide between these two treatment approaches.

However, none of these studies reported outcomes separately for those who had a discectomy versus those that did not. One study excluded from patient population all disc herniations documented by MRI [3]. In two studies there was no mention of disc disruption or disc herniation [5, 6].

ILLUSTRATIVE CASE (FIGS 3–10)

A 43-year-old man was the unrestrained driver and sole occupant in a single vehicle roll-over high speed motor vehicle accident. The patient was found walking around at the scene of the accident. In the emergency room he complained of neck pain and facial and scalp abrasions. Neurological examination revealed right shoulder numbness, but no other neurological abnormality. He had no other injuries other than his cervical spine facet subluxation.

Anterior decompression was indicated to remove the posteriorly displaced disc fragment and combined anterior and posterior fixation provided reduction of the dislocated facet and stability. In the scenario of a subluxation, as opposed to dislocation, anterior discectomy, fusion, and plating are often effective treatment options. It is anticipated that his C5 radiculopathy would recover after treatment.

Fig 3 Lateral cervical spine plain x-ray demonstrates anterior subluxation of C4 on C5 of approximately 25% of the vertebral body diameter.

Fig 4 Axial CT scan

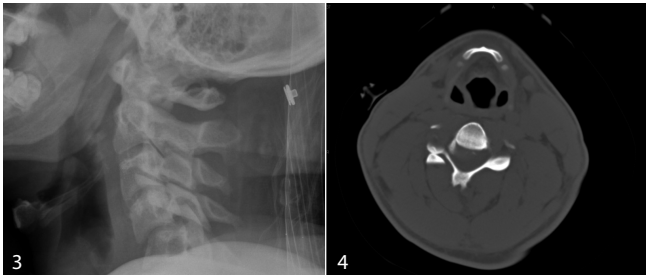


Fig 5 Reformatted image confirms a unilateral right sided facet dislocation at C4–5.

Fig 6 A second reformatted image confirms a unilateral right sided facet dislocation at C4–5.

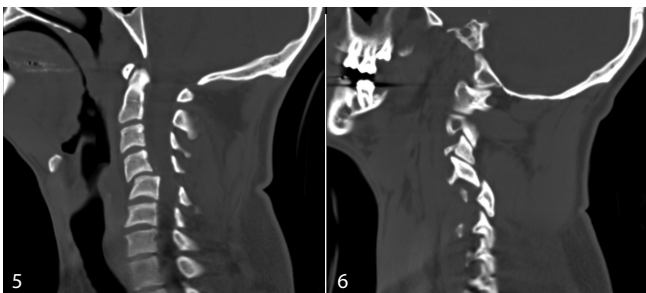


Fig 7 MRI imaging performed preoperatively revealed disc material posterior to the anteriorly subluxed body of C4.

Fig 8 Anterior discectomy was successful at decompression, however was not completely successful at reducing the dislocated facet joint.

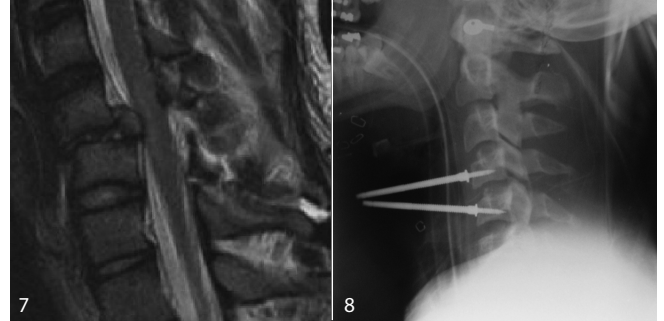


Fig 9–10 Lateral and AP views of combined anterior and posterior fixation which was ultimately necessary to stabilize this injury.

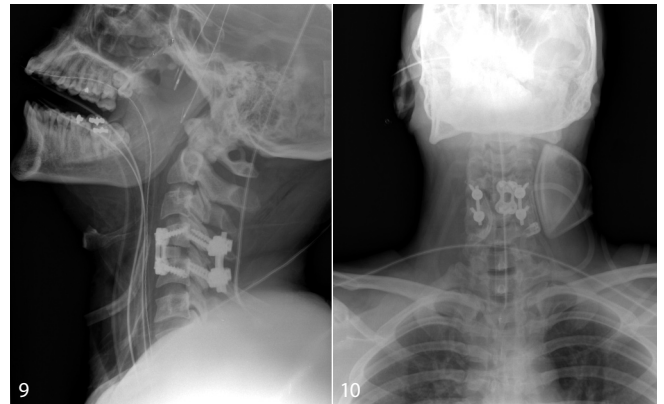


Table 3 Subject demographics of studies evaluating operative versus nonoperative treatment for unilateral facet dislocation

Author (Year)	Study type	Population	Dislocation characteristics	Treatment	Follow-up
Shapiro (1999)	Case series	N=46 Age: 30 years (19–52) 86% male	Unilateral cervical facet dislocation ± fractures; single level dislocation	Surgery: Posterior reduction and/or internal fixation (n=46, 100%) – First 24 patients underwent spinous process wire fixation – Additional 22 patients underwent interspinous wiring with braided cable for lateral mass plating	Mean follow-up: – Spinous process wire group: 102 months – Cable and lateral mass plate group: 40 months – Follow-up rate: 86% – Follow-up range: 12–120 months
Henriques (2004)	Case series	N=17 Age: 47 years (17–82) 94% male	Distractive flexion injuries Stage 2 (unilateral facet) ± fractures 2-level dislocation n=3	Anterior fixation (n=17, 100%)	Mean follow-up: – 15 months – Follow-up rate: NR
Harrington (2007)	Case series	N=11 Age: 42 years (22–65) 55% male	Single-level unilateral facet injuries ± fractures	Anterior cervical discectomy, distraction reduction with allograft fusion and anterior cervical plating	– Follow-up 30 days – Follow-up rate: 100%
Kwon (2007)	Case series	N=42 Age: 35 years (17–86) 74% male Anterior fixation n=20 Age: 38 years (17–86) 70% male Posterior fixation n=22 Age: 33 years (17–69) 77% male	Single-level unilateral facet injury ± fractures	Anterior fixation: anterior cervical discectomy and fusion (n=20, 47%) Posterior fixation: lateral mass screw-plate fixation, and/or oblique wiring (n=22, 53%)	Anterior fixation follow-up rate: 14/20 (70%) at 12 months Posterior fixation follow-up rate: 19/22 (86%) at 12 months
Rorabeck (1987)	Case series	N=26 Age: 37 years (17–74) 85% male	Isolated unilateral facet dislocation n=12 Fracture of facet or associated body fracture n=14	Initial treatment consisted of either skull-tong or halo traction (n=26, 100%) – Six (23%) patients experienced reduction with traction – Two treated nonoperatively with halo thoracic vest – Four underwent one-level posterior fusion – Twenty (77%) did not experience reduction – Ten (38.5%) left in displaced position, ambulated with external bracing – Ten (38.5%) underwent open reduction and single-level posterior fusion	Mean follow-up: – 3 years – Follow-up rate: 100%
Beyer (1991)	Case series	N=36* Age: 33 years (15–87) 78% male *2 patients lost to follow-up Nonoperative: n=24 Age: 30 years (16–74) Operative: n=10 Age: 33 years (15–71)	Unilateral facet dislocations or fracture-dislocations with n=2 at multiple levels	Initial treatment (N=34): – Closed reduction with halo traction (n=28), halo traction alone (n=1), immobilization with cervical brace (n=4), and no treatment (n=1) Operative treatment (n=10): Indications for surgery included: – Persistence or progression of neural deficit (n=4) – Failed reduction (n=3) – Loss of reduction (n=3) Operative treatment consisted of open reduction through posterior approach and fusion with interspinous wiring	Mean nonoperative follow-up: nearly 9 years Mean operative follow-up: 6.5 years Follow-up rate for both groups: 94% 2 patients lost to follow-up

Table 4 Subject outcomes of studies evaluating operative versus nonoperative treatment for unilateral facet dislocation

Author (Year)	Treatment failure N (%)	Neurological deterioration N (%)	Infection N (%)	Pain N (%)	Complications N (%)	Significant findings
Shapiro (1999)	1 (2%) Experienced resubluxation and underwent reoperation of anterior cervical fusion and plating	0 (0%)	3 (6%)	6 (13%) – Persistent neck pain in 4 (17%) of spinous process wire group – Persistent neck pain in 2 (9%) of cable and lateral mass plate group	No other complications reported	– No deaths – Spinous process wire group had 11 (46%) perfect anatomical alignment compared to 14 (64%) cable and lateral mass plate group
Henriques (2004)	1 (5.9%) Patient with 2-level injury reoperated with anterior fusion due to nonunion	0 (0%)	0 (0%)	0 (0%)	– Developed unilateral recurrent laryngeal nerve palsy secondary to surgical approach in 1 (2.8%) – Transient dysphagia in 1 (2.8%) – Injury of the lateral cutaneous femoral nerve as a result of bone graft harvesting in 1 (2.8%)	– Two (66%) of the three patients with 2-level injuries developed nonunion at one level – One nonunion patient reoperated with anterior fusion while reoperation not necessary in the other as patient free of symptoms
Harrington (2007)	0 (0%)	0 (0%) Preoperative ASIA E-7 (64%) D-4 (36%) Postoperative ASIA E-8 (73%) D-3 (27%) One preoperative ASIA score of D improved to E postoperatively. All other preoperative ASIA scores did not change postoperatively.	1 (9.1%)	0 (0%) No pain in any patient as evidence of stability	Ventilator-related pneumonia in 1 (9.1%) patient requiring tracheotomy	Translational subluxation: Preop 5–1 mm; Postop 0–3.5 mm Sagittal rotation: Preop -15 to +16° Postop -11 to +6°
Kwon (2007)	1 (2.4%) Posterior fixation patient developed pseudoarthrosis and required anterior revision	Anterior fixation: Neurological component of NASS cervical spine questionnaire: 85.2 (100 optimal) Posterior fixation: Neurological component of NASS cervical spine questionnaire: 83.9 (100 optimal) Baseline neurological status not measured so deterioration cannot be calculated.	Anterior fixation: 1 (5%) Infection at bone graft site at 3 weeks Posterior fixation: 4 (18%) Superficial wound infection at 2–3 weeks in three patients (14%) MRSA wound infection in one patient (4%)	Anterior fixation: Score of > 5 out of 10 VAS pain in three (15%) patients Posterior fixation: Score of > 5 out of 10 VAS pain in three (13.6%) patients	Anterior fixation: Severe medical complications acutely postop in one patient (5%) Swallowing difficulties in 11 (55%) Posterior fixation: No other complications reported	Median time to achieve discharge criteria: Anterior 2.75 (1–24) days; Posterior 3.5 (1.5–42) days VAS pain score on postoperative day 1: Anterior 2.6; Posterior 3.6 and on postoperative day 2: Anterior 2.1; Posterior 3.0 No difference in anterior versus posterior regarding SF-36 mental and physical scores and for NASS cervical and neurological scores Fusion rate available for patients at 12-month follow-up: Anterior 100% (18/18); Posterior 89% (17/19)

Author (Year)	Treatment failure N (%)	Neurological deterioration N (%)	Infection N (%)	Pain N (%)	Complications N (%)	Significant findings
Rorabeck (1987)	20 (77%) Did not anatomically reduce after initial treatment of skull-tong or halo traction	0 (0%)	NR	7 (26.9%) – No patient (0%) that experienced reduction with traction had pain at follow-up – Of ten patients left in displaced position seven (70%) had disabling pain – Of ten patients that underwent open reduction 0% had pain at follow-up	– Five of seven patients left in displaced position and having significant disabling pain went on to surgical anterior or posterior fusion – Two of ten patients receiving open reduction and single-level fusion did not have a successful reduction	Patients left in displaced position and allowed to heal in that position develop late pain
Beyer (1991)	22 (64.7%) patients did not achieve anatomical reduction: – 15 patients had imperfect reduction – seven patients (all in nonoperative treatment group) were left in dislocated position	Full population: 3 (8.8%) Nonoperative: 3 (13%) Showed no change or possibly deterioration at follow-up Operative: 0 (0%)	NR	Full population: 11 (32.4%) Nonoperative: 10 (42%) Operative: 1 (10%)	Halo traction not effective as a means of obtaining closed reduction – Ten (36%) achieved anatomical reduction – Seven (25%) remained dislocated – Eleven (39%) showed some improvement	– Cervical translation, at or adjacent to the injury level, seen more frequently w/ nonoperative treatment (38%) versus operative (20%) – Solid fusion in ten (100%) patients treated operatively – Spontaneous fusion in 13 patients (54%) in nonoperative group – Anatomical reduction was attained more frequently by operative intervention (60% versus 25%) – Less than anatomical reduction is a risk factor for cervical translation, regardless of treatment

REFERENCES

- Harrington JF, Jr, Park MC (2007) Single level arthrodesis as treatment for midcervical fracture subluxation: a cohort study. *J Spinal Disord Tech*; 20:42–48.
- Henriques T, Olerud C, Bergman A, et al (2004) Distractive flexion injuries of the subaxial cervical spine treated with anterior plate alone. *J Spinal Disord Tech*; 17:1–7.
- Kwon BK, Fisher CG, Boyd MC, et al (2007) A prospective randomized controlled trial of anterior compared with posterior stabilization for unilateral facet injuries of the cervical spine. *J Neurosurg Spine*; 7:1–12.
- Shapiro S, Snyder W, Kaufman K, et al (1999) Outcome of 51 cases of unilateral locked cervical facets: interspinous braided cable for lateral mass plate fusion compared with interspinous wire and facet wiring with iliac crest. *J Neurosurg*; 91:19–24.
- Beyer CA, Cabanela ME, Berquist TH (1991) Unilateral facet dislocations and fracture-dislocations of the cervical spine. *J Bone Joint Surg Br*; 73:977–981.
- Rorabeck CH, Rock MG, Hawkins RJ, et al (1987) Unilateral facet dislocation of the cervical spine. An analysis of the results of treatment in 26 patients. *Spine (Phila Pa 1976)*; 12:23–27.