

## Comparison of fascicular, interfascicular, and epineural suture techniques in the repair of simple nerve lacerations

ROBERT LEVINTHAL, M.D., W. JANN BROWN, M.D.,  
AND ROBERT W. RAND, M.D., PH.D.

*Departments of Surgery/Neurosurgery, and Pathology, University of California at Los Angeles, School of Medicine, Los Angeles, California*

✓ Simple lacerations of dog anterior tibial nerves were repaired utilizing fascicular, interfascicular, and epineural suture techniques. Two months following repair, the involved regions of the nerves were removed and stained with hematoxylin and eosin, Weil, Bielschowsky, and Masson trichrome stains. An independent, unbiased observer rated proximal and distal myelin, connective tissue responses, and proximal to distal axon counts. The proportion of proximal to distal axons revealed no significant difference between fascicular (77%) and epineural (67%) neurorrhaphy, but showed a significant beneficial effect of fascicular suture to the interfascicular (52%) repair (significance at  $< 0.02$ ). Masson stain revealed dense connective tissue responses, but the axon counts were adversely affected only when the separate fascicles showed internal disruption by connective tissue. In general, distal myelination was mildly superior with the fascicular neurorrhaphy technique.

It appears that in simple lacerations in nerves which are repaired via direct end-to-end suture, there is no significant advantage to fascicular over epineural repair; however, there is a definite deleterious effect of interfascicular neurorrhaphy. The theoretical and technical implications of these findings are discussed.

**KEY WORDS** • neurorrhaphy • epineural suture technique •  
interfascicular suture technique • fascicular suture technique •  
nerve laceration • nerve suture

**T**HE ideal neurorrhaphy would assure axonal continuity without causing connective tissue reaction. Certain technical aspects of nerve repair are considered essential to attaining this goal: 1) gentle handling of tissues facilitated by appropriate magnification,<sup>9,10,12</sup> 2) avoidance of undue tension,<sup>8,10,14</sup> 3) a clean, aseptic operative field,<sup>11,14</sup> and 4) suture materials that elicit minimal foreign body response.<sup>2,10</sup>

Inasmuch as the perfect neurorrhaphy is not yet possible, there is considerable controversy as to which is the best of the following three generally acceptable techniques to

repair a simple nerve laceration: 1) The epineural technique, the oldest and most widely accepted technique, aligns proximal and distal stumps by utilizing landmarks on the epineurium. 2) The interfascicular technique, as described by Millesi, *et al.*,<sup>9</sup> joins groups of small fascicles or single large fascicles with the aid of a microscope. 3) The perineural (or fascicular) technique unites single fascicles by perineural suture under the operating microscope.<sup>1,3</sup>

The following study was undertaken to evaluate objectively the efficacy of epineural, interfascicular, and perineural neurorrhaphy

## Techniques of nerve suture

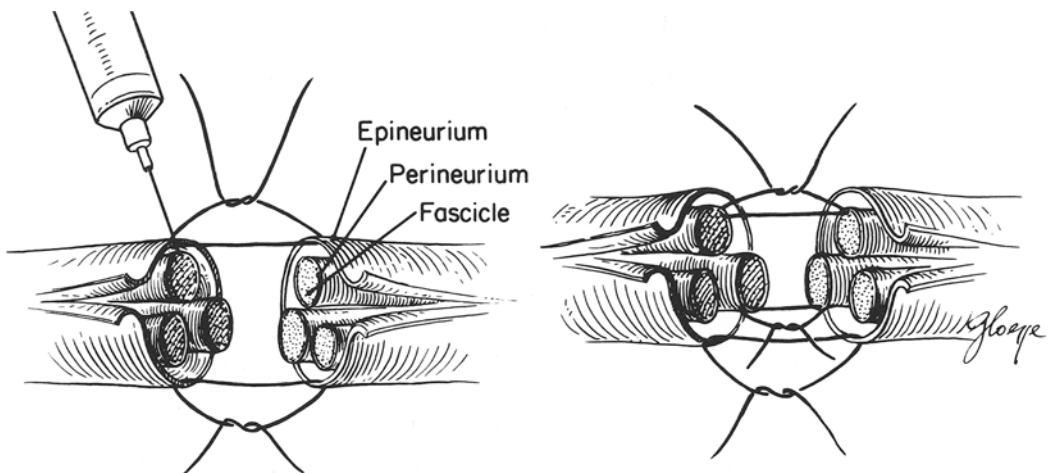


FIG. 1. Drawings showing the epineural technique. *Left:* Saline is injected into the peroneal nerve of the dog. Severed ends are then attached by placing sutures through the epineurium. This epineural anastomosis allows free mingling of severed nerve fascicles. *Right:* Fascicular anastomosis is carried out with individual fascicles being fine-sutured at the perineurium. A suture through the epineurium is depicted for comparison. In the interfascicular anastomosis a group of fascicles are sutured together by stitches placed in the epineural tissues.

in repair of simple peripheral nerve lacerations.

### Materials and Methods

The peroneal nerves of nine mongrel dogs were exposed bilaterally at a point 2 cm proximal to the tibial condyle. At this level, the nerves are approximately 0.5 to 1.0 cm in diameter, and contain five to eight fascicles. One piece of broken glass held against a tongue depressor was used to lacerate the nerve. Each laceration in a single animal was repaired with one of the three suture techniques, so that among nine dogs, 18 nerves were repaired with six nerve anastomoses falling in each neurorrhaphy group. One surgeon (R.L.) performed all of the operative procedures.

In the epineural repair, eight 6-0 silk sutures on a cardiovascular needle were used. The surgeon wore  $\times 3.5$  loupes and every effort was made to follow vascular and fascicular landmarks (Fig. 1).

Before the perineural and interfascicular repair, 0.5 normal saline was carefully injected with a No. 25 needle into the epineural tissue to facilitate the dissection. All of the dissection and the anastomoses were performed under  $\times 16$  to  $\times 25$  magnification (200 mm objective lens). Three or four proximal bundles of fascicles were dissected free and anastomosed to their distal mates with

two 10-0 nylon sutures for each interfascicular group (Fig. 2). For the perineural repair, six to eight separate fascicles were isolated and sutured end to end with two 10-0 nylon sutures placed in the perineurium of each fascicle (Fig. 3).

The wounds were closed with a two-layer closure. Two animals had superficial wound dehiscence; the wounds were cleansed and closed without further problem. All animals were provided 3-day coverage with intramuscular antibiotics. No external splinting was used.

At the end of 2 months the nerves were dissected free at a point approximately 1.5 cm proximal and distal to the suture and were then removed. They were kept in a solution of 10% formalin for 2 weeks, then removed, compared, and photographed. The nerves were then embedded in paraffin, sectioned, and stained, using hematoxylin and eosin, Masson trichrome, Weil and Bielschowsky techniques.

An unbiased observer (W.J.B.) was asked to grade the proximal-to-distal myelination and connective tissue responses. He was not informed as to which technique was employed on any nerve. On a scale of 0 to 5, zero signified no myelination, while a 5+ indicated healthy undamaged nerve. The connective tissue reaction was graded in each transverse section and in the longitudinal section. In this

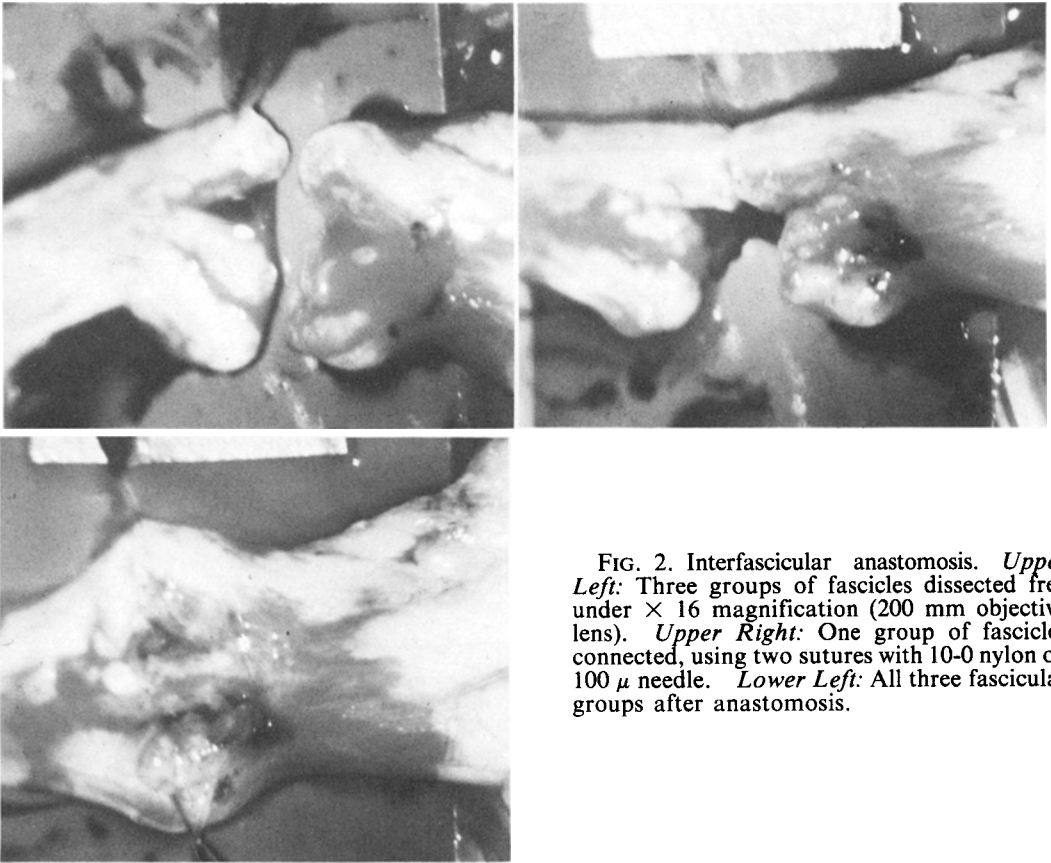


FIG. 2. Interfascicular anastomosis. *Upper Left:* Three groups of fascicles dissected free under  $\times 16$  magnification (200 mm objective lens). *Upper Right:* One group of fascicles connected, using two sutures with 10-0 nylon on 100  $\mu$  needle. *Lower Left:* All three fascicular groups after anastomosis.

ranking, zero was considered to be a normal, uninjured nerve whereas 5+ represented an area completely replaced by fibrous tissue, without remaining axons. Utilizing the Bielschowsky stain, a count of proximal-to-distal axon concentration was performed. The sections were photographed with a  $\times 10$  magnification (actual calculated magnification was  $\times 33$ ). The photographs were then enlarged 7.2 times and axon counts were made in representative fascicles with the aid of a transparent grid. The number of axons in each square was determined and multiplied by the number of squares per fascicles to calculate the axons per fascicle. Two or three fascicles were averaged and the number of axons distally was divided by the number proximally and multiplied by 100 to compute the axonal ratio.

**Results**

There was no reproducible characteristic of any technique on the gross nerve. Neuromas

were present with each suture, but no specific method was clearly superior or inferior.

The perineural suture had slightly better distal myelination than the epineural, and the epineural appeared somewhat superior to the interfascicular technique (Table 1). There were four nerves with 3+ ratings; three of these were sutured by using the perineural technique, and one with epineural suture. One nerve evidenced a 0 distal myelination; it was repaired with the interfascicular method. Out of seven 1+ distal myelination responses,

TABLE 1  
*Distal myelination*

Myelination Grade	Neurorrhaphy Technique		
	Perineural	Epineural	Interfascicular
3+	+++	+	
2+	++	++	++
1+	+	+++	+++
0			+

## Techniques of nerve suture

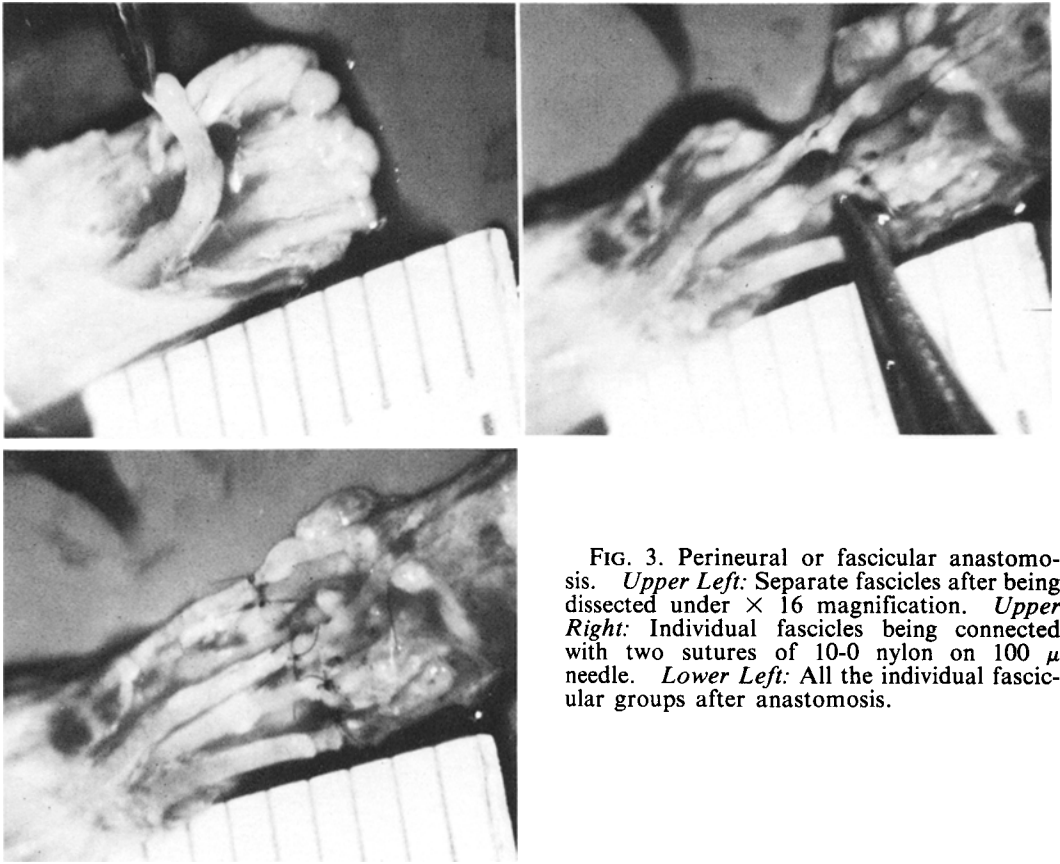


FIG. 3. Perineural or fascicular anastomosis. *Upper Left:* Separate fascicles after being dissected under  $\times 16$  magnification. *Upper Right:* Individual fascicles being connected with two sutures of 10-0 nylon on 100  $\mu$  needle. *Lower Left:* All the individual fascicular groups after anastomosis.

only one was associated with the perineural technique. The other six 1+ ratings were equally divided between epineural and interfascicular repairs. There were also six 2+ ratings and these were evenly distributed among the various methods.

A wide variability in connective tissue response to the different neurorrhaphy techniques was evident. The amount of connective tissue response did not appear to adversely affect axonal regeneration unless there was actual invasion through the perineural barrier

by scar tissue (Fig. 4). The distal-to-proximal axon ratios are shown in Fig. 5 and Table 2. The difference between the perineural and interfascicular techniques is significant at  $p < 0.02$  by the Student "t"-test. The differences between the other neurorrhaphy methods were not significant with the small numbers available for analyses.

### Discussion

Until recently, epineural neurorrhaphy has been the generally accepted method of simple nerve repair.<sup>11,13</sup> However, as early as 1917, Langley and Hashimoto envisioned funicular suture.<sup>6</sup> Sunderland also was early to point out the theoretical advantage of fascicular or perineural suture.<sup>13-15</sup> Not until the introduction of the operating microscope to peripheral nerve surgery did true perineural suture become technically possible.<sup>12</sup> Since that time, many authors have advocated the interfascicular<sup>9,10</sup> and perineural suture techniques.<sup>1</sup>

TABLE 2

*Mean and range of distal-to-proximal axon ratios*

Technique	Mean (%)	Range (%)
perineural	77.3 $\pm$ 13.6	56.4-90.3
epineural	67.3 $\pm$ 19.5	39.2-84.7
interfascicular	51.8 $\pm$ 15.8	27.5-68.6

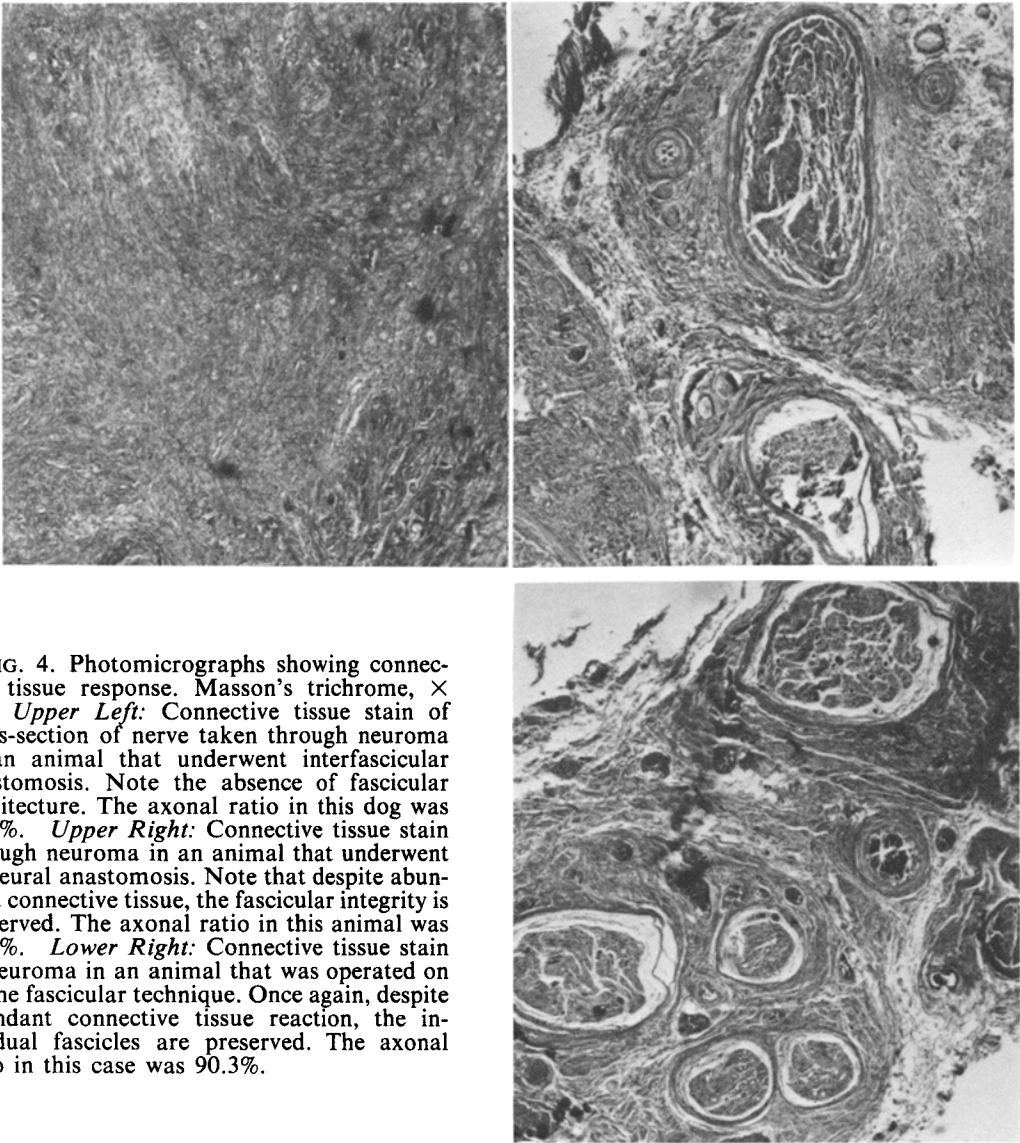


FIG. 4. Photomicrographs showing connective tissue response. Masson's trichrome,  $\times 10$ . *Upper Left:* Connective tissue stain of cross-section of nerve taken through neuroma in an animal that underwent interfascicular anastomosis. Note the absence of fascicular architecture. The axonal ratio in this dog was 39.1%. *Upper Right:* Connective tissue stain through neuroma in an animal that underwent epineurial anastomosis. Note that despite abundant connective tissue, the fascicular integrity is preserved. The axonal ratio in this animal was 83.3%. *Lower Right:* Connective tissue stain of neuroma in an animal that was operated on by the fascicular technique. Once again, despite abundant connective tissue reaction, the individual fascicles are preserved. The axonal ratio in this case was 90.3%.

The perineural or fascicular neurorrhaphy has two theoretical advantages: direct alignment of fascicles is possible, and only damaged fascicles are repaired. There are also some possible disadvantages: the required dissection may produce additional scarring, and there may be damage to blood supply.

The interfascicular technique does not afford direct perineural anastomosis, and the amount of dissection needed is only slightly less than that required for the perineural method.

The epineurial repair offers the positive feature that no internal disruption of the nerve occurs; however, even in the most meticulous hands, the epineurial neurorrhaphy cannot produce true fascicular alignment.

Since each technique has distinct disadvantages, all three fall short of the ideal neurorrhaphy. Although it appears that the perineural technique may produce slightly better axonal ratios and distal myelination than the epineurial method, the differences are not

# Techniques of nerve suture




FIG. 5. Scatter graph showing distal:proximal axon ratios. Values in parentheses are obtained by calculating distal:proximal axon count  $\times 100$ . The number beside each axonal ratio indicates the dog from which the nerve was obtained. In no case did an interfascicular anastomosis have a higher axonal ratio than the fascicular or epineural anastomosis in the opposite leg.

significant. The perineural method realizes significantly higher axonal ratios and a greater distal myelination than the interfascicular suture. The perineural and epineural procedures probably achieve better results because the former produces excellent fascicular alignment while the latter causes no internal trauma and subsequent connective tissue proliferation. The interfascicular technique appears less ideal because it does not effect perineural alignment, yet it causes internal disruption and scar formation.

A number of conditions should be emphasized:

1. These operations were performed in dogs; their response to nerve suture may not exactly represent that of human subjects.<sup>4,5</sup> The number of animals utilized was small; a larger series may have elucidated further statistically significant trends.

2. This experiment is pertinent only to acute, simple, end-to-end suture; other theoretical and technical considerations would be relevant in cases requiring nerve grafting.<sup>7,9-11,16</sup>

3. Our grading system for myelination and connective tissue response, although performed blindly, is a subjective number system

and therefore open to limitations.

4. Most important, the success of nerve repair is dependent on strict adherence to the technical principles set forth in the introduction.

#### References

1. Bora FW Jr: Peripheral nerve repair in cats. The fascicular stitch. **J Bone Joint Surg** 49A:659-666, 1967
2. Edshage S: Peripheral nerve suture. A technique for improved intraneural topography evaluation of some suture materials. **Acta Chir Scand [Suppl]** 331:1-104, 1964
3. Hakstian RW: Funicular orientation by direct stimulation. An aid to peripheral nerve repair. **J Bone Joint Surg** 50A:1178-1186, 1968
4. Kline DG, Hayes GJ, Morse AS: A comparative study of response of species to peripheral-nerve injury. I. Severance. **J Neurosurg** 21:968-979, 1964
5. Kline DG, Hayes GJ, Morse AS: A comparative study of response of species to peripheral-nerve injury. II. Crush and severance with primary suture. **J Neurosurg** 21:980-988, 1964
6. Langley JN, Hashimoto M: On the suture of separate nerve bundles in a nerve trunk and on internal nerve plexuses. **J Physiol (Lond)** 51:318-346, 1917
7. Levinthal R: Microsurgical and theoretical aspects of nerve allografting, in Rand RW (ed): **Microsurgery**. St. Louis: CV Mosby (In press)
8. Lundborg G, Rydevik B: Effects of stretching the tibial nerve of the rabbit. **J Bone Joint Surg** 55B:390-401, 1973
9. Millesi H, Meissl G, Berger A: The interfascicular nerve-grafting of the median and ulnar nerve. **J Bone Joint Surg** 54A:727-750, 1972
10. Samii M: Modern aspects of peripheral and cranial nerve surgery, in Krayenbühl H (ed): **Advances and Technical Standards in Neurosurgery**. New York/Wein: Springer-Verlag, 1975, vol 2, pp 33-85
11. Sedden H: **Surgical Disorders of the Peripheral Nerves**. Baltimore: Williams and Wilkins, 1972, 336 pp
12. Smith JW: Microsurgery of peripheral nerves. **Plast Reconstr Surg** 33:317-329, 1964
13. Sunderland S: The connective tissue of peripheral nerves. **Brain** 88:841-854, 1965
14. Sunderland S: Funicular suture and funicular exclusion in the repair of severed nerves. **Br J Surg** 40:580-587, 1953
15. Sunderland S: The intraneural topography of the radial median and ulnar nerves. **Brain** 68:243-299, 1945
16. Sunderland S: **Nerves and Nerve Injuries**. Edinburgh/London: Churchill Livingstone, 1968, 1160 pp

---

*Address reprint requests to:* Robert Levinthal, M.D., c/o Editor, Department of Surgery, University of California, Los Angeles, School of Medicine, Los Angeles, California 90024.