



ELSEVIER

Contents lists available at ScienceDirect

JSES International

journal homepage: [www.jseinternational.org](http://www.jseinternational.org)

## Should closed reduction be attempted in the emergency department for an acute anterior shoulder fracture dislocation?



Wei Yuan, MD (China) MRCS (Edin),  
Ivan Tjun Huat Chua, MBBS (S'pore), MRCS (Edin), M.Med (Ortho), FRCS (Ortho) \*

Department of Orthopaedic Surgery, Tan Tock Seng Hospital, Singapore

### ARTICLE INFO

#### Keywords:

anterior fracture dislocation  
shoulder  
closed reduction  
iatrogenic fracture  
displacement  
emergency department

Level of evidence: Level III; Retrospective  
Cohort Comparison; Treatment Study

**Background:** Whether an anterior shoulder fracture dislocation should be reduced under sedation in the emergency department is still a dilemma. This retrospective study aimed to determine when it is safe to perform a closed reduction based on the fracture pattern.

**Methods:** Surgically treated anterior shoulder fracture dislocations over eight years were classified into three groups. Group 1 involved an isolated greater tuberosity fracture. Group 2 and 3 involved surgical and or anatomical neck fractures. In group 2, the head and the shaft fragments were displaced together anteriorly and inferiorly; whereas in group 3, the head was displaced and locked under the glenoid, but the shaft migrated superiorly. The outcome and complications of closed reduction were reviewed.

**Results:** Twenty-nine patients with 30 surgically treated anterior shoulder fracture dislocations were reviewed. These included twelve patients (thirteen shoulders) in group 1, six patients in group 2, and eleven patients in group 3. Closed reduction was attempted in twelve shoulders in group 1, five shoulders in group 2, and six shoulders in group 3. Eleven group 1, four group 2, and none group 3 dislocations were successfully reduced. The patient who failed reduction in group 1 sustained an iatrogenic anatomical neck fracture. One patient failed reduction in group 2. His surgical neck fracture was displaced further after manipulation. No other complications occurred after closed manipulation.

**Discussion and Conclusion:** Closed reduction under sedation is usually successful and safe for group 1 injuries with an iatrogenic complication rate of only 8.3% (1/12) in our series. It should also be considered for group 2 injuries as 80% (4/5) were successfully reduced. However, further displacement from the reduction maneuver may warrant an urgent open reduction. Closed reduction is futile for group 3 injuries. We recommend an acute management algorithm based on our results.

© 2020 The Author(s). Published by Elsevier Inc. on behalf of American Shoulder and Elbow Surgeons. This is an open access article under the CC BY-NC-ND license (<http://creativecommons.org/licenses/by-nc-nd/4.0/>).

Anterior shoulder dislocation associated with a proximal humeral fracture is rare. The ideal acute management is still controversial. The various methods include closed reduction in the emergency department (ED) under sedation, closed reduction in the operation theater under general anesthesia, and open reduction<sup>9</sup>. Closed reduction under sedation may be more difficult because the reduction forces are not transmitted to the humeral head when it is separated from the shaft. In addition, the reduction maneuvers can cause further fracture displacement or even iatrogenic fractures. And the blood supply of the humeral head may be further compromised. However, if closed reduction is successful, an

urgent operation can be avoided, and the definitive surgery can be performed on an elective basis in a more prepared manner.

In this retrospective study, we reviewed our experiences in the acute management of anterior shoulder fracture dislocations. We aim to classify the injuries based on the fracture pattern and recommend an acute management algorithm in the ED.

### Materials and methods

All patients who sustained an anterior shoulder fracture dislocation and were treated surgically between 1st Jan 2010 and 31st Dec 2017 in our institution were included. Patients' demographics and mechanism of injury were reviewed.

The injuries were classified into three groups based on the fracture pattern on the initial radiographs (Table I). No CT scan was performed before reduction. Group 1 patients sustained an isolated greater tuberosity fracture. Group 2 and 3 patients sustained an anatomical neck and or surgical neck fracture, with or without

Institutional Review Board of National Healthcare Group approval was obtained before the start of the study (reference no. 2019/00298).

\* Corresponding author: Ivan Tjun Huat Chua, MBBS (S'pore), MRCS (Edin), M.Med (Ortho), FRCS (Ortho), Department of Orthopaedic Surgery, Tan Tock Seng Hospital, Singapore.

E-mail address: [ivan\\_chua@ttsh.com.sg](mailto:ivan_chua@ttsh.com.sg) (I.T.H. Chua).

<https://doi.org/10.1016/j.jseint.2020.09.014>

2666-6383/© 2020 The Author(s). Published by Elsevier Inc. on behalf of American Shoulder and Elbow Surgeons. This is an open access article under the CC BY-NC-ND license (<http://creativecommons.org/licenses/by-nc-nd/4.0/>).

greater tuberosity fracture. In group 2, the head and the shaft fragments were displaced together inferiorly and anteriorly; whereas in group 3, the head fragment was displaced to the axilla and locked under the glenoid, and the shaft migrated superiorly (Fig. 1).

The number of reduction attempts, reduction maneuvers, successfulness of reduction, complications, and subsequent surgeries were reviewed.

## Results

Twenty-nine patients with thirty fracture dislocations were included in the study. One of them sustained bilateral shoulder fracture dislocations simultaneously. Thirteen patients were male, and sixteen were female. Mean age at the time of injury was 62 (range: 26 to 82) years. Mechanism of injury was road traffic accident in seven patients, fall from standing height in eighteen patients, and seizure in four patients.

Twelve patients (thirteen shoulders) were classified into group 1, including the one who sustained bilateral dislocations. His left shoulder injury was missed initially in the ED thus was not reduced. Closed reduction under sedation was attempted for the rest twelve shoulders. The ED physicians delivered sedation with propofol. Eleven shoulders were successfully reduced. Of them, nine were reduced on the first attempt, one on the second attempt, and one on the third attempt. They were all fixed with cancellous screws or proximal humerus locking plate subsequently. The one who failed closed reduction sustained an iatrogenic fracture of the anatomical neck on the first reduction attempt. And no further closed reduction was attempted for him. He underwent hemiarthroplasty. No other complications occurred in this group.

Six patients were classified into group 2. According to Neer's classification, two fractures were 2-part, two were 3-part, and two was 4-part. One 2-part fracture dislocation was not recognized initially and was treated as a proximal humeral fracture without dislocation. Thus, no reduction was attempted. For the rest, four were successfully reduced on the first attempt. One failed reduction. And as a result, her surgical neck fracture was displaced further after the first reduction attempt and the head was trapped in the axilla. She underwent hemiarthroplasty. For the rest five patients, two underwent fixation with a proximal humerus locking plate, and three underwent reverse shoulder arthroplasty. No other complications occurred.

Eleven patients were classified into group 3. Closed reductions in the ED were attempted once or twice for six of them without any success. The rest were not reduced as they were regarded as irreducible by the attending ED physicians. In terms of definitive surgery, three underwent fixation. One underwent reverse shoulder arthroplasty, and the rest seven underwent hemiarthroplasty. Three patients in this group sustained brachial plexus injury. Closed reduction was attempted twice in one of them and not attempted in the other two.

## Discussion

In this study, we classified anterior shoulder fracture dislocation into three groups (Table 1). Most dislocation with an isolated greater tuberosity fracture (group 1) could be reduced successfully under sedation in the ED. However, one of them could not be reduced and sustained an iatrogenic neck fracture as a result of manipulation. Patients with a surgical and or anatomical neck fracture, with or without greater tuberosity fracture, were further divided into two groups. When the head and the shaft fragments were displaced together (group 2), closed reduction was successful in four of the five patients. However, when the head was severely displaced away

**Table 1**  
Classification of anterior shoulder fracture dislocation.

Group	Fracture pattern
1	Isolated GT fracture
2	Anatomical and or surgical neck fracture, with or without GT fracture Head and shaft fragments were displaced inferiorly and anteriorly together
3	Anatomical and or surgical neck fracture, with or without GT fracture Head was retained in the axilla and locked under glenoid, shaft migrated superiorly

GT, greater tuberosity.

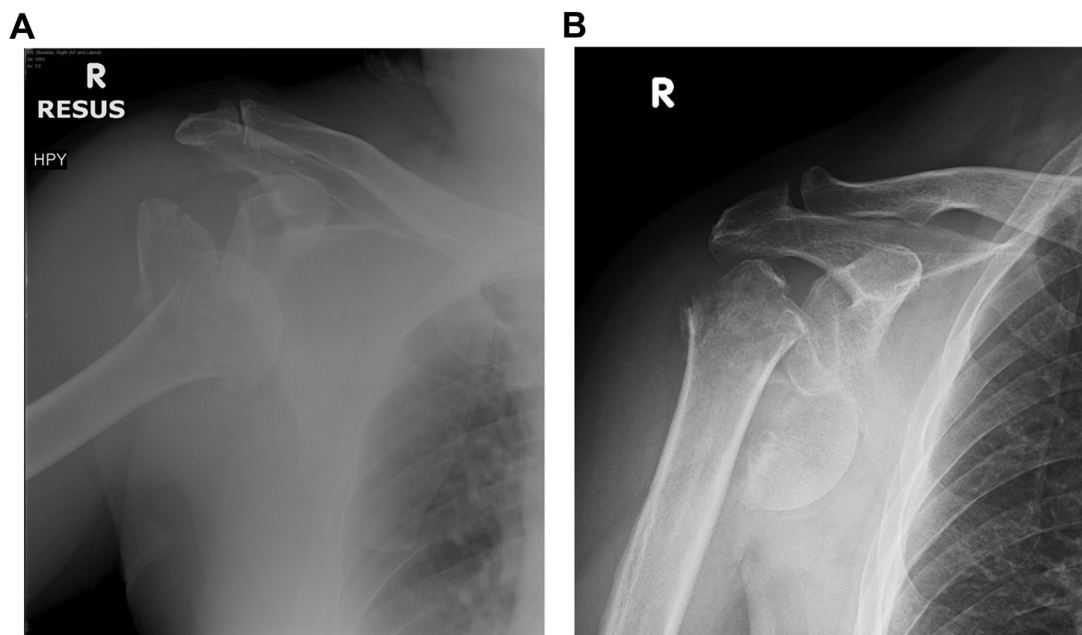
from the shaft and locked under the glenoid (group 3), attempted closed reductions all failed.

Studies on the acute management of an anterior shoulder fracture dislocation are sparse. Wronka et al<sup>12</sup> classified 94 such injuries into two types. Type I involved an isolated greater tuberosity fracture and type II involved a surgical neck fracture with or without a greater tuberosity fracture. Of the 62 cases who underwent closed reduction under sedation, 3 type I and 5 type II cases failed. Four failed type II injuries had significant displacement of the surgical neck fracture and required an urgent operation. The author recommended a closed reduction for type I but not type II injuries. In our study, we further divided their "type II" injuries into group 2 and 3. Our experiences showed that most group 2 injuries could be reduced, as opposed to group 3 injuries.

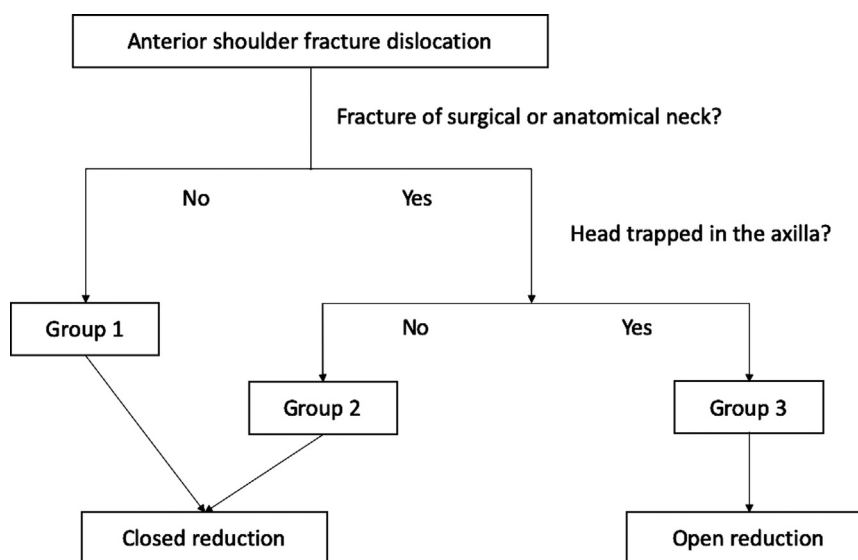
Most of group 1 injuries could be reduced under sedation<sup>12</sup>. Solovyova et al<sup>11</sup> also reported successful closed reduction on the first attempt without iatrogenic fracture in all 13 patients over 50 years old. However, there were rare cases that could not be reduced due to blocks such as biceps tendon, greater tuberosity fragment, or Hill-Sachs lesion<sup>1,5,7,10</sup>. A "shield fracture" is a special fracture pattern where the greater and lesser tuberosities are attached to each other, and both were separated from the head. They are attached to the subscapularis and infraspinatus tendons. These muscles push the humeral head anteriorly and block reduction<sup>2</sup>. When a closed reduction is not successful, especially after multiple attempts, one should consider the injury as irreducible and proceed with open reduction.

Although rare, an iatrogenic fracture may occur in group 1 injuries. Ferkel et al<sup>4</sup> reported two such cases, in which the humeral neck fractured by closed reduction and the head was trapped in the axilla as a result. Similarly, in our study, one group 1 injury became group 3 injury after manipulation. CT scan was not routinely performed prior reduction, but we scrutinized the initial radiographs and did not find any neck fracture. Ranawat et al<sup>9</sup> considered that significant medial displacement of the head might predispose patients to iatrogenic fracture. However, this has not been our experience. Significant medial displacement was also seen in successfully reduced group 1 injuries. Nonetheless, the incidence of this complication is low in group 1 injuries and, in our opinion, closed reduction under sedation should still be attempted.

Closed reduction for an anterior dislocation with a surgical or anatomical neck fracture is generally not recommended<sup>3,6,12</sup> as the fracture may be displaced further. Demirhan et al<sup>11</sup> reported six iatrogenically displaced anatomical neck fractures resulting from closed reduction. And they were treated with primary humeral head replacement. Hersche<sup>6</sup> also reported seven cases in which open or closed reduction led to displacement of neck fracture. And subsequently, avascular necrosis developed in all six patients with an anatomical neck fracture. We divided our patients with surgical or anatomical neck fractures into two groups. Reduction attempts for group 2 injuries in our series were successful in most of the cases without displacing fractures further. Iatrogenic further displacement of fracture occurred in 20% (1/5) of the cases. Thus,



**Figure 1** Radiographic illustration of group 2 and group 3 injuries. Surgical neck fracture was present in both radiographs. (A) group 2 injury. Humeral head and shaft were displaced together. (B) group 3 injury. Humeral head was retained in the axilla, locked under the glenoid. Humeral shaft migrated superiorly.



**Figure 2** Algorithm of acute management of anterior shoulder fracture dislocations.

we think a gentle reduction attempt with gradual force can still be attempted for group 2 injuries. Urgent open reduction facilities and personnel should be available.

Age is another consideration. Iatrogenic fracture or further displacement of existing fracture is less forgiving in young patients. Disruption of blood supply to the humeral head may lead to avascular necrosis. Hemiarthroplasty or reverse shoulder arthroplasty are good options for elderly patients with low functional demands but not ideal for young patients due to high functional demand and prosthesis longevity. As such, for young patients (age < 60) in group 2, closed reduction under general anesthesia with fluoroscopy can be considered. A failed reduction attempt can be promptly converted to open reduction and internal fixation in the operation theater. Percutaneous pinning as an adjunct to prevent fracture propagation during reduction has also been described<sup>9</sup>.

Group 3 injuries are generally regarded as irreducible and open reduction is recommended. However, successful reduction was reported<sup>8</sup>. In that report, a nondisplaced anatomical neck fracture became displaced, and the head was trapped in the axilla after closed reduction. The author first pushed the humeral head upward from the axilla, then abducted the arm, followed by pushing the shaft toward the head and pushing the head back into the glenoid. All reduction attempts for group 3 injuries failed in our series. Thus, we do not recommend to reduce them.

Based on our results, we recommend an acute management algorithm for anterior shoulder fracture dislocation (Fig. 2). However, we should bear in mind that there are exceptions in every group.

There are a few limitations in our study. First, the number of patients is small. Because of the rarity of this injury, most literatures

are also case reports or case series. Second, most closed reductions were done by the ED physicians instead of the orthopedic surgeons. In the local setting, orthopedic surgeons are only referred for difficult reductions. However, the ED physicians are very experienced in manipulation and reduction as they are always the first line. Finally, the reduction maneuver was only documented in one case. We could not draw a conclusion on which maneuver is more effective or safer.

### Conclusion

We recommend an algorithm to guide the acute management of anterior shoulder fracture dislocations. Anterior shoulder fracture dislocation with an isolated greater tuberosity fracture should be reduced under sedation in the ED. Closed reduction can also be attempted when there is surgical or anatomical neck fracture, as long as the head is not trapped in the axilla and locked under the glenoid. One should bear in mind that there are exceptions in each group.

### Disclaimer

The authors, their immediate families, and any research foundations with which they are affiliated have not received any financial payments or other benefits from any commercial entity related to the subject of this article.

### References

1. Aiyenuro OD, Zadeh HG. Irreducible acute anterior shoulder dislocation due to rotator cuff tear and associated fracture of the greater tuberosity: A method of open reduction and rotator cuff repair. *Inj Extra* 2007;38:74-7. <https://doi.org/10.1016/j.injury.2006.07.050>.
2. Amroodi MN. Irreducible anterior shoulder dislocation associated with displaced fracture of the greater tuberosity: An analysis of seven cases. *Shafa Orthop J* 2015;2:10-4.
3. Demirhan M, Akpinar S, Atalar AC, Akman S, Akalin Y. Primary replacement of the humeral head in iatrogenically displaced fracture-dislocations of the shoulder: a report about six cases. *Injury* 1998 Sep;29:525-8.
4. Ferkel RD, Hedley AK, Eckardt JJ. Anterior fracture-dislocations of the shoulder: pitfalls in treatment. *J Trauma* 1984 Apr;24:363-7.
5. Henderson RS. Fracture-dislocation of the shoulder with interposition of long head of biceps. *J Bone Joint Surg Br* 1952;34-B:240-1.
6. Hersche O, Gerber C. Iatrogenic displacement of fracture-dislocations of the shoulder. A report of seven cases. *J Bone Joint Surg Br* 1994 Jan;76:30-3.
7. Janecki CJ, Barnett DC. Fracture-dislocation of the shoulder with biceps tendon interposition. *J Bone Joint Surg Am* 1979;61:142-3.
8. Koda M, Hisamitsu J, Nakayama S, Nishikawa S, Furuya T, Yamazaki M, Ogino S. Successful closed reduction for iatrogenic displacement of the anatomical neck of the humerus: a case report. *BMC Res Notes* 2014;7:770. <https://doi.org/10.1186/1756-0500-7-770>.
9. Ranawat AS, DiFelice GS, Suk M, Lorch DG, Helfet DL. Iatrogenic propagation of anterior fracture-dislocations of the proximal humerus: case series and literature review with suggested guidelines for treatment and prevention. *Am J Orthop (Belle Mead NJ)* 2007 Sep;36:E133-7.
10. Seradge H, Orme G. Acute irreducible anterior dislocation of the shoulder. *J Trauma* 1982 Apr;22:330-2.
11. Solovyova O, Shakked R, Tejwani NC. Should All Shoulder Dislocations be Closed Reduced? Assessment of Risk of Iatrogenic Injury in 150 Patients. *Iowa Orthop J* 2017;37:47-52.
12. Wronka KS, Ved A, Mohanty K. When is it safe to reduce fracture dislocation of shoulder under sedation? Proposed treatment algorithm. *Eur J Orthop Surg Traumatol* 2017 Apr;27:335-40. <https://doi.org/10.1007/s00590-016-1899-z>.