

OPEN

Surgical Technique for Closed Reduction and Percutaneous Pinning of Pediatric Lateral Humeral Condyle Fractures

Vincent W. Prusick, MD,*† Nicholas J. Dantzker, MD,*
 Alexander A. Hysong, BA,‡ Megan Johnson, MD,*† Gregory A. Mencia, MD,*†
 Christopher M. Stutz, MD,§ and Jonathan G. Schoenecker, MD, PhD*†||¶

Summary: Lateral condyle fractures are intra-articular injuries of the distal humerus and are the second most common elbow fracture in pediatric patients. When these fractures involve significant displacement, anatomic reduction of the lateral condyle fragment is commonly achieved using open reduction techniques. Although a technique for closed reduction of lateral condyle fractures has been proposed in the literature, an instructional, step-by-step description of such a technique has yet to be published. We have built upon the previously published closed reduction technique by focusing on the pathomechanism of injury, with the goal of making successful closed reduction more reliably reproducible across treating surgeons. Specifically, this article provides step-by-step descriptions of the proposed mechanism of injury, reduction technique, pinning technique, arthrogram/casting technique, and suggested follow-up for pediatric patients with lateral humeral condyle fractures.

Key Words: pediatrics—lateral humeral condyle fracture—closed reduction—percutaneous pinning—arthrogram—technique.

(*Tech Orthop* 2020;35: 145–150)

Lateral condyle fractures are intra-articular injuries of the distal humerus and are the second most common elbow fracture in pediatric patients.¹ Unlike supracondylar humerus fractures, lateral condyle fractures are rarely associated with neurovascular injury

and do not require urgent treatment unless they involve a dislocated joint (Song 5 or valgus-impaction type—see below). When significant displacement is present, accurate reduction of the chondroepiphysis, which contains the entirety of the articular surface, minimizes complications such as malunion, limited elbow range of motion, and cubitus varus/valgus.^{2,3} Typically, anatomic reduction of displaced lateral condyle fractures is achieved using open reduction techniques as the fragment contains no structure (periosteum or articular cartilage) to key in the fracture fragment and the chondroepiphysis cannot be imaged with standard radiographic imaging. Although a technique for closed reduction of lateral condyle fractures has been proposed in the literature, an instructional, step-by-step description of such a technique has yet to be published.^{1,2} In light of this, we have built upon the previously published closed reduction technique by focusing on the pathomechanism of injury, with the goal of making successful closed reduction more reliably reproducible across treating surgeons. Although the mechanism and pathoanatomy underlying lateral condyle fractures remains controversial, we believe that a thorough understanding of these concepts is critical to the success of closed reduction methods.

Much of the controversy in the literature stems from disagreement as to whether the deforming force of this injury results from the impaction of the radial head against the lateral condyle or

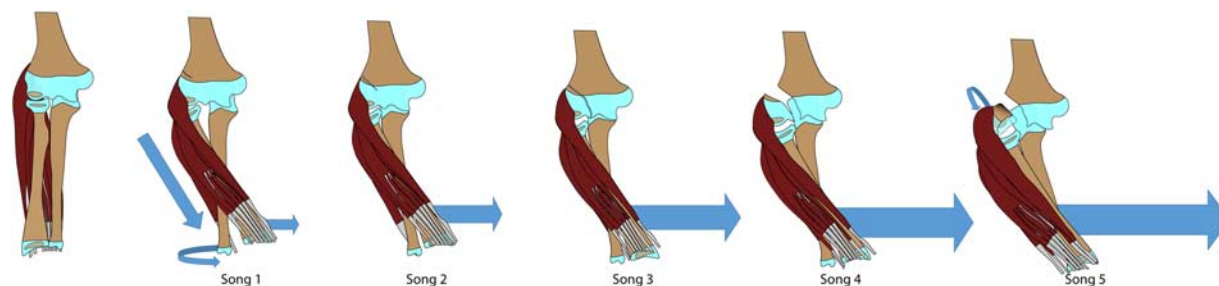


FIGURE 1. Illustration of the pathomechanism underlying avulsion-type lateral condyle fractures. The amount of displacement of the lateral condyle fragment increases with increased varus force at the elbow and contraction of the extensor-supinator muscles.

From the Departments of *Orthopaedics and Rehabilitation; †Pediatrics; ||Pathology, Microbiology, and Immunology, Vanderbilt University Medical Center; ¶Department of Pharmacology, Vanderbilt University; ‡Vanderbilt University School of Medicine, Nashville, TN; and §Texas Scottish Rite Hospital for Children, Pediatric Orthopaedic Surgery, Dallas, TX.

V.W.P., N.J.D., and A.A.H. contributed equally.

Supported by the Vanderbilt Department of Orthopaedics and Rehabilitation, Nashville, TN; The Caitlin Lovejoy Foundation, Nashville, TN.

The authors declare that they have nothing to disclose.

For reprint requests, or additional information and guidance on the techniques described in the article, please contact Jonathan G. Schoenecker, MD, PhD, at jon.schoenecker@vanderbilt.edu or by mail at 4202 Doctor's Office Tower, 2200 Children's Way, Nashville, TN 37232. You may inquire whether the author(s) will agree to phone conferences and/or visits regarding these techniques.

Supplemental Digital Content is available for this article. Direct URL citations appear in the printed text and are provided in the HTML and PDF versions of this article on the journal's website, www.techortho.com.

Copyright © 2018 The Author(s). Published by Wolters Kluwer Health, Inc. This is an open-access article distributed under the terms of the Creative Commons Attribution-Non Commercial-No Derivatives License 4.0 (CCBY-NC-ND), where it is permissible to download and share the work provided it is properly cited. The work cannot be changed in any way or used commercially without permission from the journal.

is instead caused by an avulsion mechanism of the extensor-supinator muscles (mobile wad) pulling off the lateral condyle.⁴ Although both of these mechanisms likely play a role in producing fractures of the lateral condyle, we are proposing a reduction technique focused on injuries that have occurred via the avulsion mechanism. It is through an appreciation of how the distinct position of the forearm in space creates this force that one can utilize closed reduction with reliable success. Specifically, the

position of the forearm is characterized by a fall on an outstretched arm while the elbow and the wrist are extended, and the forearm is pronated. The resulting avulsion force is the product of a varus moment at the elbow applied concomitantly with the concentric contraction of the wrist extensors, both of which act on the lateral condyle (Fig. 1). It is this mechanism in particular, that creates a fracture that is amenable to closed reduction (see Video, Supplemental Digital Content 1, <http://links.lww.com/TIO/A17>, which

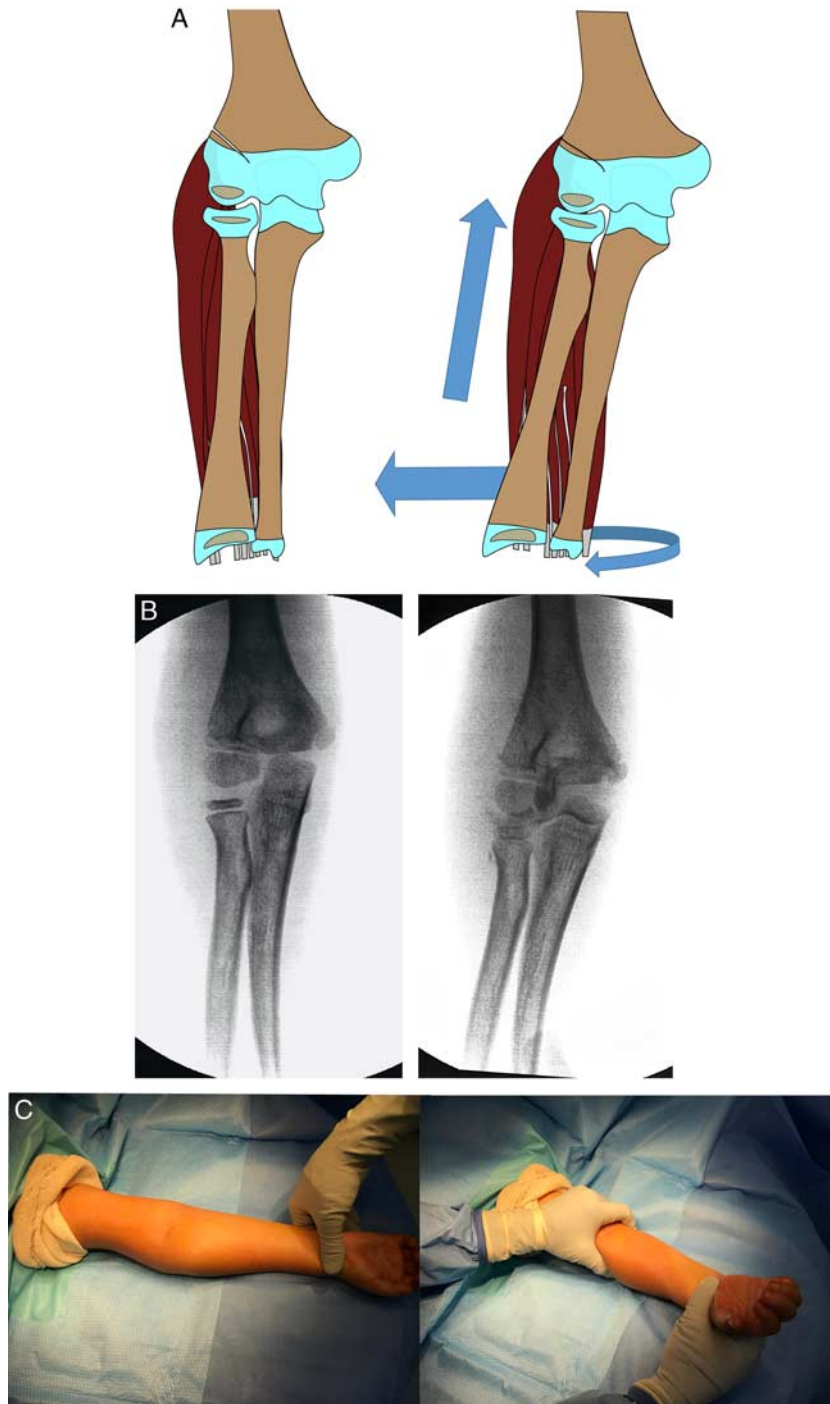


FIGURE 2. Illustration (A), intraoperative fluoroscopy (B), intraoperative photographs (C) of reduction maneuver for a minimally displaced lateral condyle fracture, in which there is an intact articular hinge (Song 2, Jakob 1).

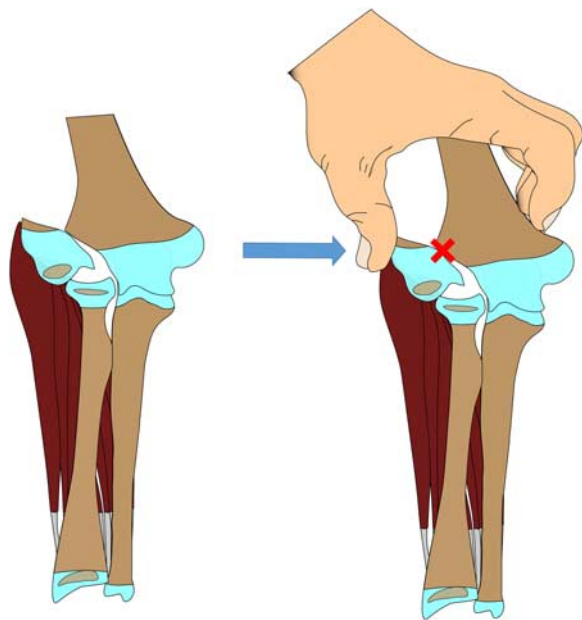


FIGURE 3. Failed reduction when the space for the lateral condyle fragment is not opened up with pronation and varus force.

shows how concomitant pronation, varus, and traction apply a distracting force on the lateral condyle and displace it from the joint space). Fractures that result from this mechanism are well classified using the Song and Jakob classification systems¹ (Supplemental Fig. 1, Supplemental Digital Content 2, <http://links.lww.com/TIO/A18>). This is in contrast to the valgus-impaction type of lateral condyle fracture (we refer to as the “Song 6”), which is the result of a fall directly onto the elbow and accounts for a small percentage of lateral condyle fractures that cannot be treated with closed reduction³ [see Video 2, Supplemental Digital Content 3, <http://links.lww.com/TIO/A16>, which shows a lateral view of supination, valgus, and impaction resulting in a lateral condyle fracture with concomitant ulnohumeral dislocation].

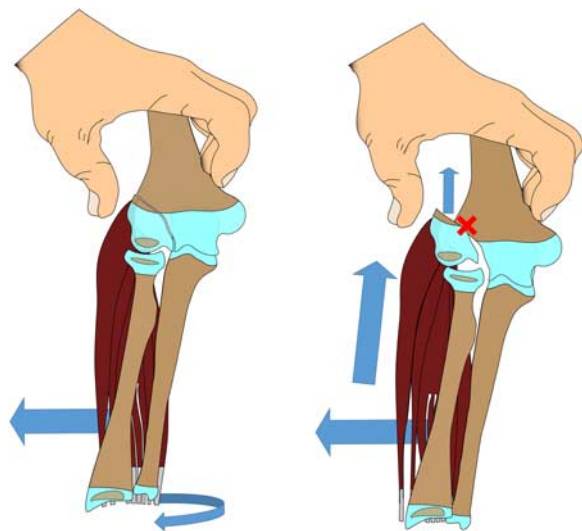


FIGURE 4. Failure of reduction when the thumb is not used as an anti-glide buttress to prevent superior migration of the lateral condyle fragment.

PREOPERATIVE EVALUATION

Song 1 fractures, in which the fracture line is confined to the bony metaphysis and clearly does not enter the chondroepiphysis, can be accurately evaluated on plain radiographs alone, with emphasis of obtaining an internal oblique to assess maximal displacement.⁵ However, it can be very difficult and often impossible to accurately differentiate between an equivocal Song 1 to 3 fracture on plain films. Because the fracture line enters the chondroepiphysis, which cannot be evaluated by standard radiography, advanced imaging is required to accurately evaluate the extent of the fracture and the amount of displacement at the articular surface. For this reason, until other noninvasive modalities have been well established, if the extent of the fracture is within the chondroepiphysis and it is difficult to determine whether the articular hinge is intact from radiographs, we advocate the use of an intraoperative arthrogram to determine whether the fracture extends completely through the chondroepiphysis thereby compromising the articular hinge. The arthrogram is obtained either diagnostically at the onset to determine treatment (Song 2 to 3) or after reduction and fixation is completed in fractures with significant displacement on plain films (Song 4 to 5). The technique for obtaining an arthrogram is detailed below (see the Arthrogram/casting techniques section).

Operating Room Setup

We have found that the reduction technique outlined below accommodates multiple variations in OR setup based on surgeon preference and comfort. There are a few important elements to the OR setup, however, which are common across these variations. We uniformly position the patient such that the operative arm is at 90 degrees to the torso. This positioning allows the surgeon to easily manipulate the arm into the positions necessary to obtain AP, lateral, and oblique fluoroscopic images throughout the procedure. In addition, the C-arm is always positioned on the operative side of the table and brought in from the foot of the bed with the surgeon standing at the patient’s head. This facilitates easy access to the lateral elbow in cases when an open reduction is required.

Treatment Technique

Lateral Condyle Fractures With an Articular Hinge that Clearly do not Enter the Chondroepiphysis (Song 1, Jakob 1)

With disrupted periosteum and metaphyseal fracture proximally, but with clear evidence that the fracture line does not enter the chondroepiphysis, the treating surgeon can be assured that the articular hinge (distal) is intact. Although these fractures do not displace, the forearm can be manipulated into supination with wrist extension to relax the deforming musculature (extensor/supinator) and casted.

Lateral Condyle Fractures With an Articular Hinge With Uncertain Involvement of the Chondroepiphysis (Song 2, Jakob 1)

If the extent of the fracture is within the chondroepiphysis and it is difficult to determine whether the articular hinge is intact from radiographs, we perform an examination under anesthesia with an arthrogram. If the fracture enters the chondroepiphysis but does not extend to the articular surface (Song 2) the lateral condylar fragment is not freely mobile and therefore can be “keyed” and compressed. The forearm is manipulated into supination with wrist extension to relax the deforming musculature (extensor/supinator) and a valgus force is applied to the elbow, utilizing the radial head to push the

lateral condyle fragment into its fully reduced native position with the articular cartilage “keying” in the fragment (Fig. 2). The surgeon may choose to either cast in this position (closed reduction with manipulation) or percutaneously pin the fragment (closed reduction with manipulation and percutaneous pinning technique described below). Fixation arthrograms are not required if the surgeon determined the articular hinge to be intact.

Lateral Condyle Fractures Without an Articular Hinge (Song 3 to 5, Jakob 2 to 3)

Without intact periosteum (proximal) or an articular hinge (distal) the lateral condylar fragment is freely mobile. This produces 2 difficulties that must be overcome, regardless if treated by a closed or open reduction. First, if the lateral condylar fragment is subluxed/dislocated (Song 4 to 5) the elbow collapses into valgus preventing adequate space for the fracture fragment (Fig. 3). Second, any compressive force on the lateral condylar fragment, such as the radial head with the elbow positioned in valgus, may induce superior translation of the fracture fragment and subsequent loss of reduction (Fig. 4). The reduction of these fractures therefore requires 2 additional steps as compared with the Song 2.

Step 1: Restore the lateral condylar fragment back to its natural position within the radiocapitellar joint (Fig. 5). The surgeon should begin by recreating the injury to open up the space needed to reduce the fracture fragment. This is accomplished by pronating the forearm and applying a gentle varus stress in elbow extension with gentle traction. This maneuver widens the lateral joint space and utilizes the mobile wad to distract the fragment, putting the piece in a position where it can be manipulated back to its point of origin. To do so, the surgeon’s thumb is placed posterior to the fragment and provides an anterior and proximal directed force to reduce the fragment into the radiocapitellar joint.

Step 2: Prevent proximal translation of the fracture fragment when using the radial head with a valgus force to compress the fracture fragment to the distal humerus (Fig. 5). As described above, the surgeon then uses the radial head and valgus stress to compress the fragment. However, with complete disruption of periosteum and the articular cartilage there are no structures to prevent superior translation with this reduction maneuver, and often the fragment is merely displaced again. To overcome this obstacle, the surgeon’s thumb is positioned to function as an “antiglide buttress.” Specifically, the thumb is placed on the posterolateral surface of the fragment to prevent proximal migration while applying a valgus stress at

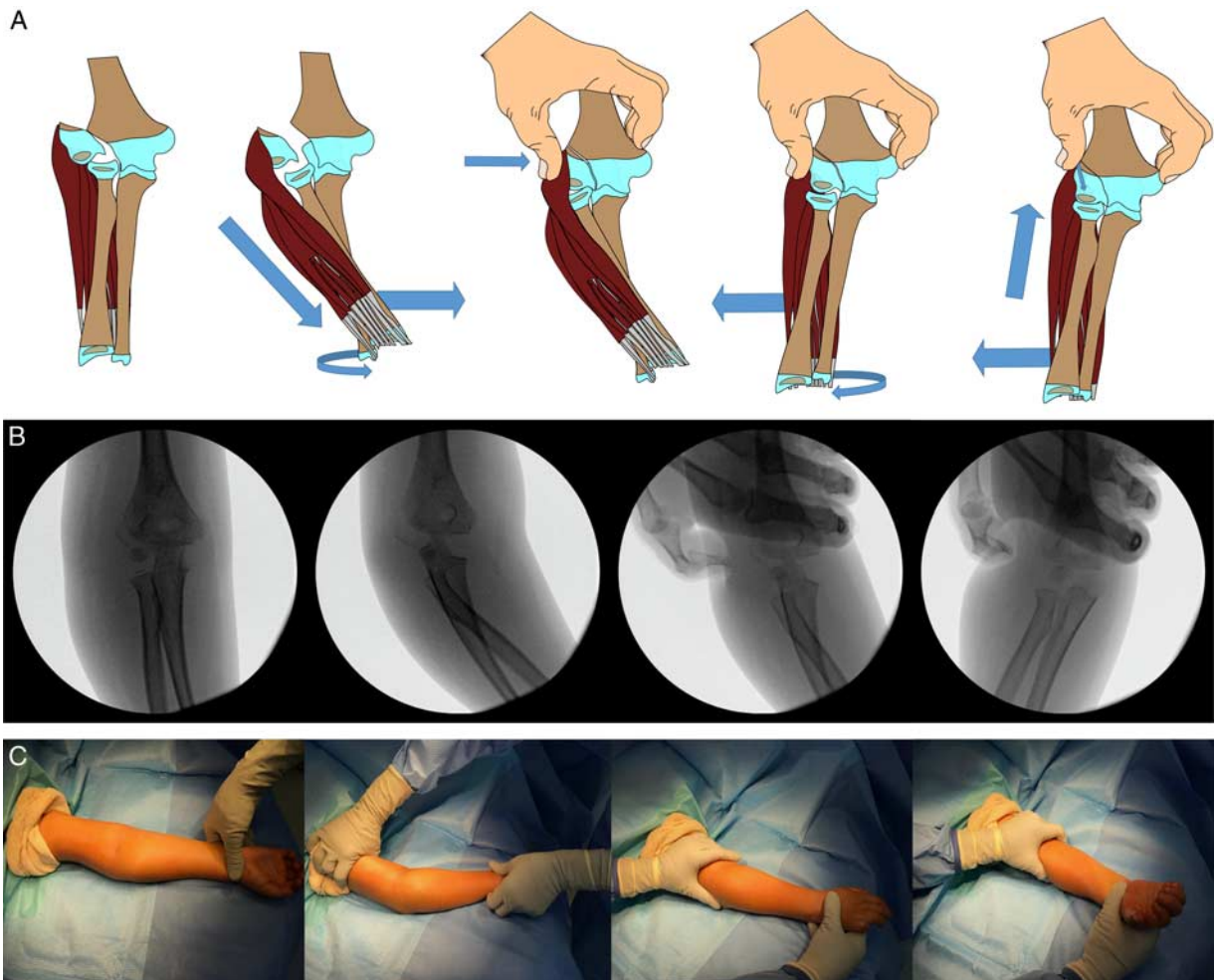


FIGURE 5. Illustration (A), intraoperative fluoroscopy (B), intraoperative photographs (C) of reduction maneuver for a displaced lateral condyle fracture, in which there is not an intact articular hinge (Song 3 to 5, Jakob 2 to 3).

the elbow. These reduction steps are typically performed with the elbow positioned at ~45 degrees of flexion although this can vary depending on the individual fracture. Reduction is then verified with c-arm imaging. The fixation and arthrogram are then performed (see the Arthrogram/casting techniques section below). The valgus position of the elbow must be maintained during surgical fixation and although this technique can be accomplished without assistance, it is substantially easier with 1 surgeon obtaining the reduction while a second inserts the fixation pins.

Fixation Technique

For any operative lateral condyle fracture, once an acceptable reduction is obtained, the surgeon can then proceed to place smooth wire fixation. We typically use three 2.0-mm pins in a divergent pattern.^{6,7} The first pin is directed through the middle of the fracture fragment and across the olecranon fossa with the starting point typically just anterior to the assistant's thumb that is serving as an antiglide buttress. This initial pin placement allows for fine tuning of the articular surface if necessary before the placement of the second pin across the trochlear region. While inserting the trochlear pin we find it helpful to place an index finger across the elbow on the medial epicondyle and provide an additional compression across the fracture as well as acting as a guide for the pin across the trochlea. A third pin is placed that is directed up the lateral

column (Fig. 6). Finally, although not reported, the surgeon should be aware of the anatomic location of the radial, median, and ulnar nerves in relation to the pins to avoid iatrogenic injury (Supplemental Fig. 2, Supplemental Digital Content 4, <http://links.lww.com/TIO/A19>).

Arthrogram/Casting Technique

For fractures that are to be definitively treated with long-arm casting alone (Song 1 fractures always, Song 2 fractures based on surgeon preference), the arm should be casted with the forearm in 15 to 20 degrees of supination and a gentle valgus mold at the elbow. In those fractures requiring operative intervention because of a disrupted articular hinge, an arthrogram after fixation is complete allows the surgeon to assess for adequate reduction of the chondroepiphysis, which is defined by congruity of the articular surface on AP, lateral, and internal oblique views of the elbow.^{4,5} The internal oblique view is essential as it shows the maximum displacement of the fragment in lateral condyle fractures.⁵ There are multiple access points for insertion of the needle for the arthrogram, but our preferred location is posteriorly into the olecranon fossa (Fig. 7). We use an 18- or 20-G needle to inject 1 to 3 mL of radiopaque dye diluted to 50% in normal saline. Once arthrogram imaging has confirmed an adequate reduction, the pins can be cut to the appropriate length and bent 90 degrees over sterile felt padding. This is followed by the application of sterile

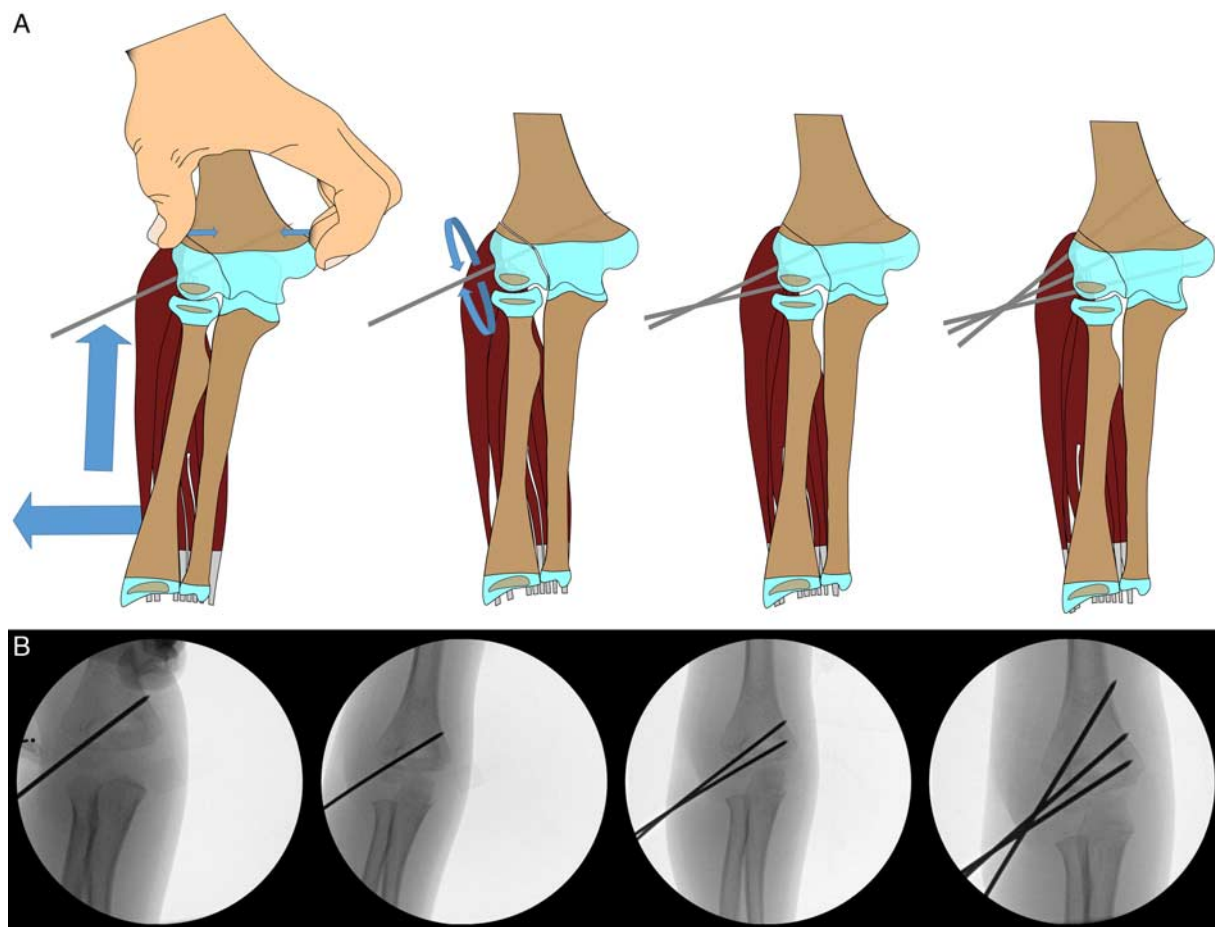


FIGURE 6. Illustration (A) and intraoperative fluoroscopy (B) of technique for percutaneous fixation of the reduced lateral condyle fragment.

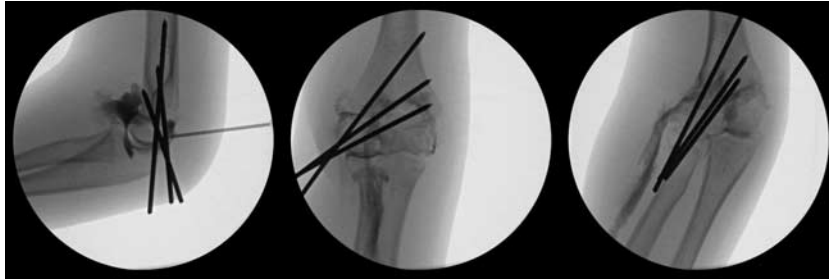

FIGURE 7. Arthrogram showing placement of needle in olecranon fossa and dye tracking down the plane of the extensor-supinator mass. Note the congruency of the articular surface on the anteroposterior, lateral, and internal oblique views of the elbow.

dressings and a long-arm cast with the elbow in 90 degrees of flexion and the forearm in a neutral position. Although compartment syndrome is an extremely rare complication of pediatric lateral condyle fractures, the cast may be univalved or bivalved depending on the clinical scenario and surgeon preference.

Follow-up

The patient is seen 1 week postoperatively for radiographic alignment check and long-arm cast overwrapping if the cast was univalved or bivalved. If the cast is not valved, the patient is seen 1 to 4 weeks postoperatively, based on surgeon preference. Subsequent follow-ups include a 4-week postoperative visit for radiographs out of the cast and pin removal in clinic if callus formation is progressing as evidenced by the beginnings of ossification along the area of periosteal disruption on the lateral condylar ridge. A long arm cast is reapplied for 2 weeks and the patient returns for a follow-up visit at 6 weeks postoperative, at which time repeat imaging is obtained and the cast is discontinued if adequate healing has been achieved.

ACKNOWLEDGMENTS

The authors thank the members of the Schoenecker Laboratory for their assistance in critically editing the manuscript and supporting the project's completion. In addition, the authors acknowledge our family, friends, and academic

colleagues for their continual encouragement, support, and understanding.

REFERENCES

1. Song KS, Kang CH, Min BW, et al. Closed reduction and internal fixation of displaced unstable lateral condylar fractures of the humerus in children. *J Bone Joint Surg Am.* 2008;90:2673–2681.
2. Song KS, Shin YW, Oh CW, et al. Closed reduction and internal fixation of completely displaced and rotated lateral condyle fractures of the humerus in children. *J Orthop Trauma.* 2010;24:434–437.
3. Kirkos JM, Beslikas TA, Papavasiliou VA. Posteromedial dislocation of the elbow with lateral condyle fracture in children. *Clin Orthop Relat Res.* 2003;408:232–236.
4. Song KS, Waters PM. Lateral condylar humerus fractures: which ones should we fix? *J Pediatr Orthop.* 2012;32(suppl 1):S5–S9.
5. Song KS, Kang CH, Min BW, et al. Internal oblique radiographs for diagnosis of nondisplaced or minimally displaced lateral condylar fractures of the humerus in children. *J Bone Joint Surg Am.* 2007;89:58–63.
6. Bloom T, Chen LY, Sabharwal S. Biomechanical analysis of lateral humeral condyle fracture pinning. *J Pediatr Orthop.* 2011;31:130–137.
7. Chen TLW, He CQ, Zheng TQ, et al. Stiffness of various pin configurations for pediatric supracondylar humeral fracture: a systematic review on biomechanical studies. *J Pediatr Orthop B.* 2015;24:389–399.