

Ortho Radiology Recap

M5 Revision

Mok Ying Ren

Goals

1. Shock your system with a quiz of common XR and things you should know
2. Recorded lecture for you to recap all important X-rays — please watch it on your own time.
(<https://mokyngren.sg/oms/xr-review-course>)



OMS XR Review Course



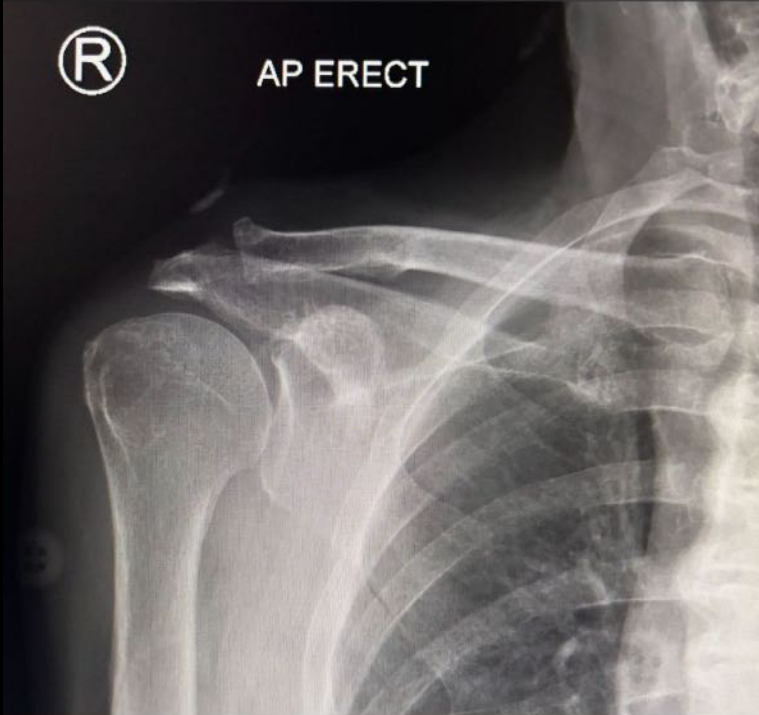
X-ray (XR) reading can be daunting for undergraduate exams, especially if you haven't seen a fracture XR in years. Your ability to spot abnormalities in an XR depends on how familiar you are with normal XRs. It's crucial to start your final posting or exam preparation by thoroughly familiarising yourself with what's normal. This course aims to provide just that.

- ▶ Course Info
- ▶ Step 1. Download Slides
- ▶ Step 2. Course Video
- ▶ Step 3. Review Quiz
- ▶ Step 4. Anki Flashcards
- ▶ Step 5. Questions and Answers



Shoulder: What is the diagnosis?

Q1

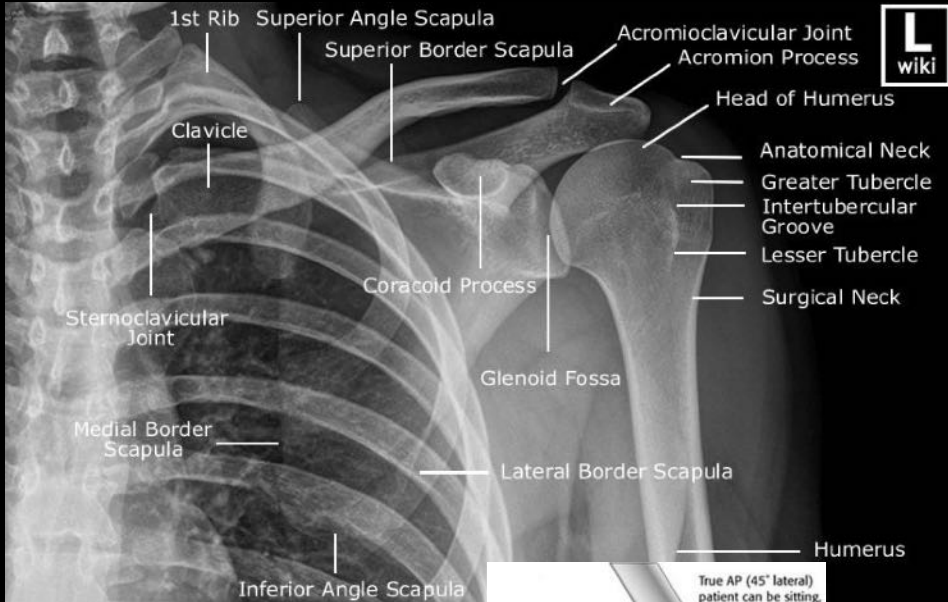


🕒 17

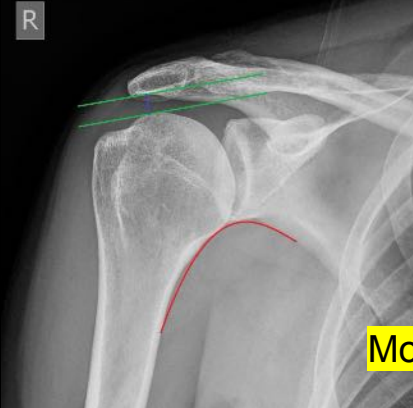
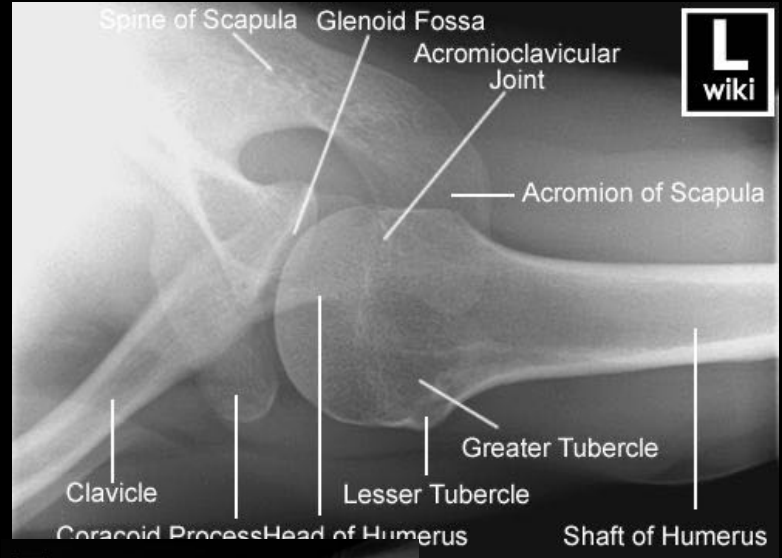
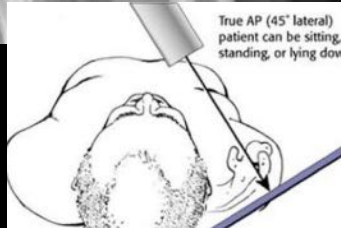
Shoulder: What is the diagnosis?

- Primary Osteoarthritis
- Rotator Cuff Arthropathy
- Shoulder Dislocation
- Proximal Humerus Fracture
- ACJ Arthritis

Normal Shoulder XR

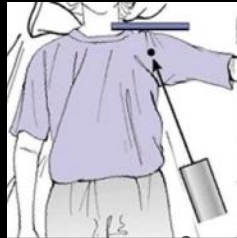

Shoulder AP



Moloney's Arc

Shoulder Axial (Coracoid determines Anterior)



Shoulder Special Views

Coracoacromial Arch

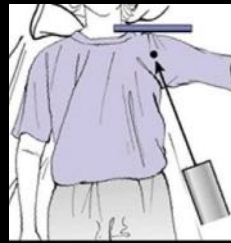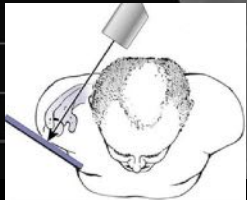Coracoid Process

Acromion

Outlet

Shaft of Humerus

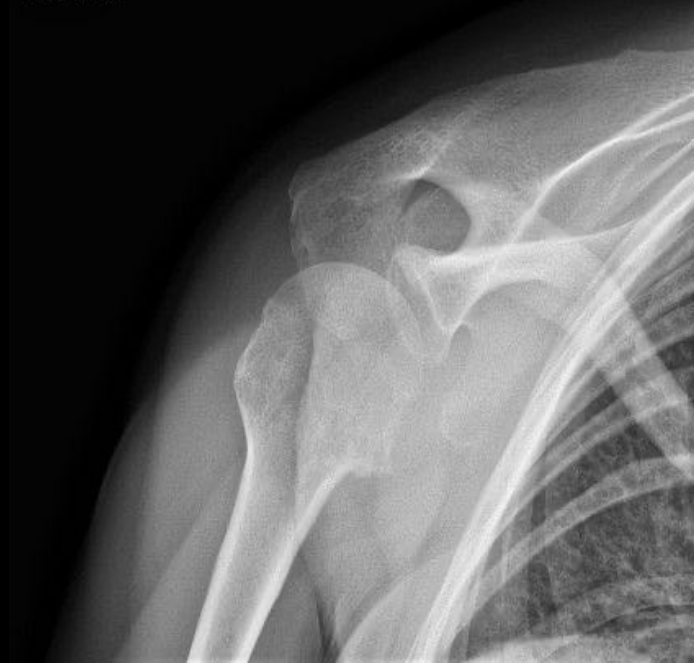Y-Scapula View



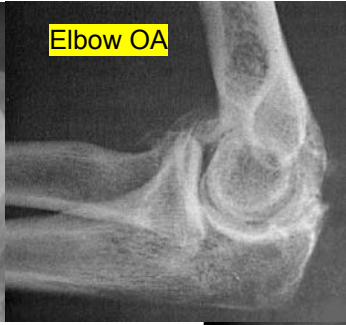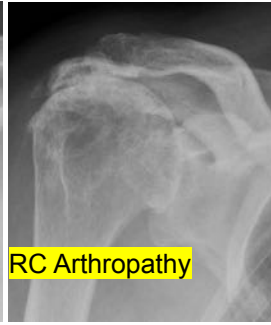
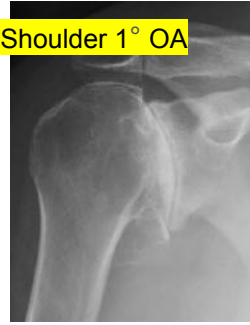RIGHT
VELPEAU

Axial View - requires
abduction of arm

Velpeau View



Approach to Arthritis XR



0. Primer [Think of the principles]

- XR of what?
- Skeletally mature?
- 2 views?

1. What Joint is Degenerated?

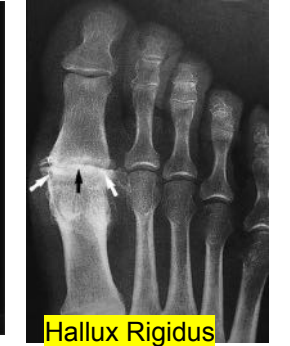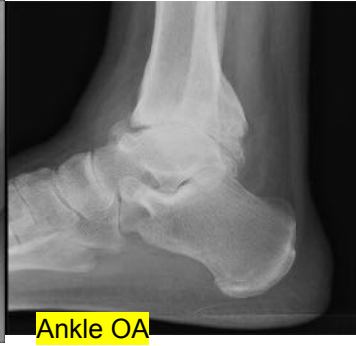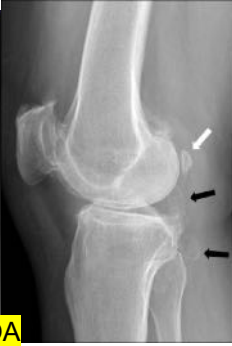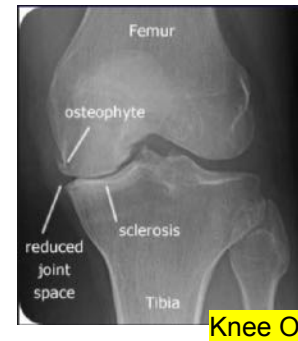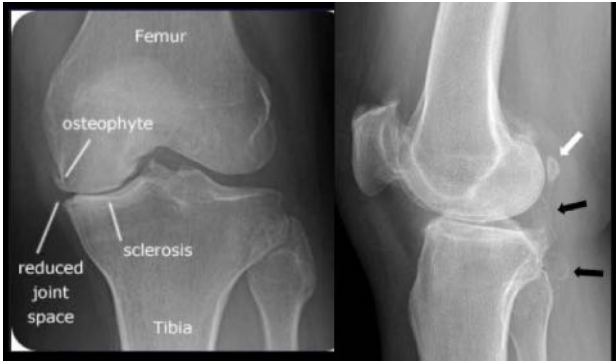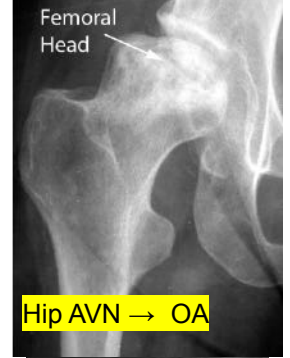
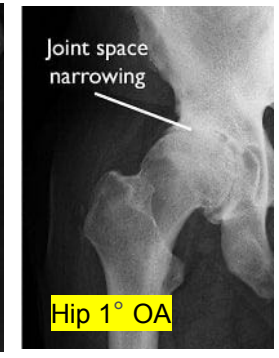
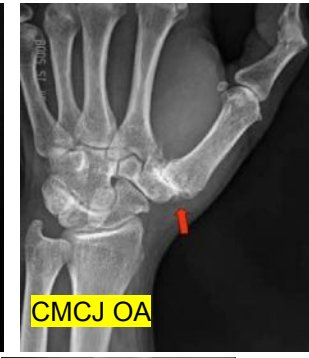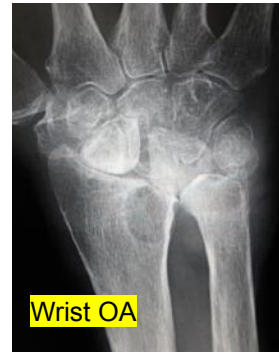- Try to be specific

2. What are the features of arthritis?

- **L** - Loss of Joint Space
- **L** - Loose bodies
- **O** - Osteophytes
- **S** - Subchondral sclerosis
- **S** - Subchondral cysts

3. Any obvious deformity? e.g.

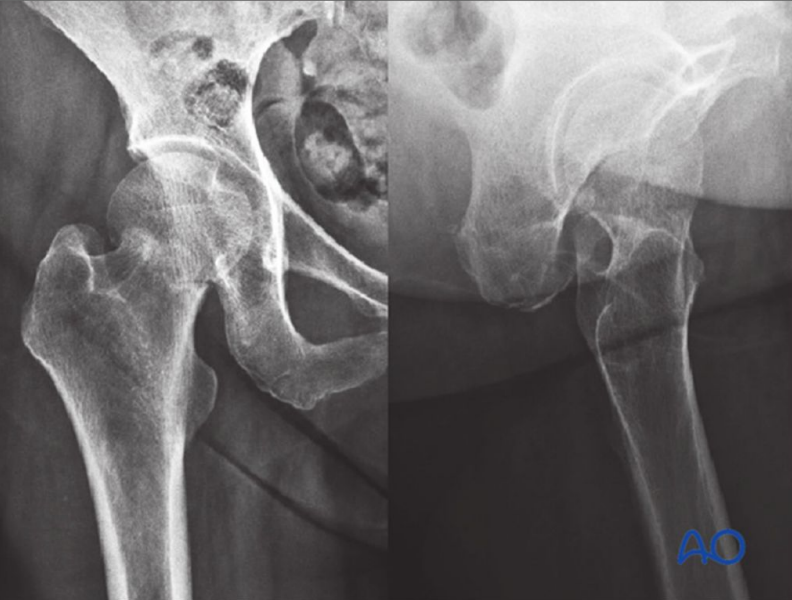
- Knee/ Ankle - Varus/ Valgus
- Shoulder - superiorly displaced
- Hip - Collapse of femoral head





Hip XR: What is the diagnosis?

Q2

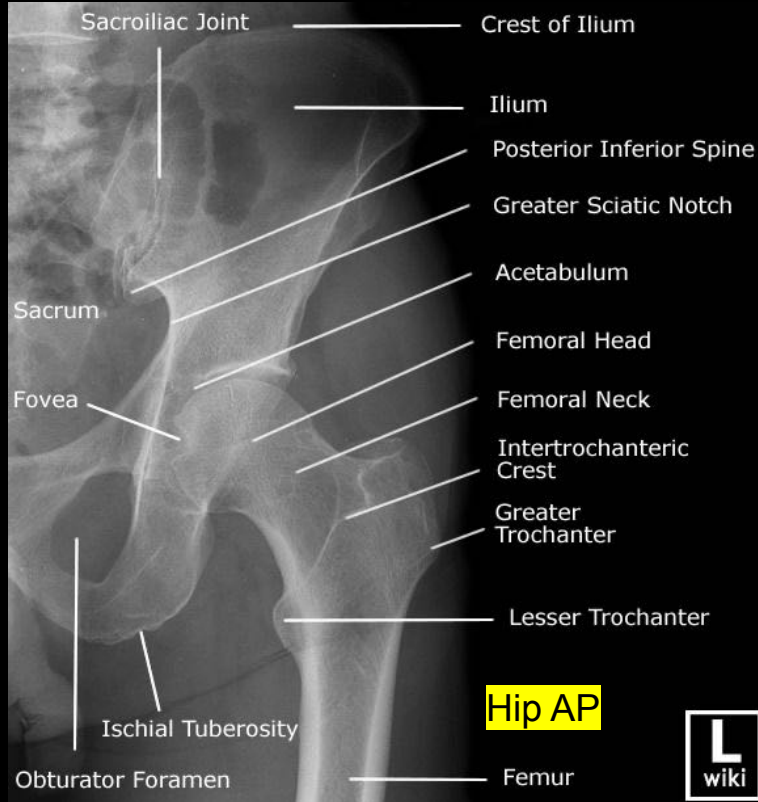


🕒 19

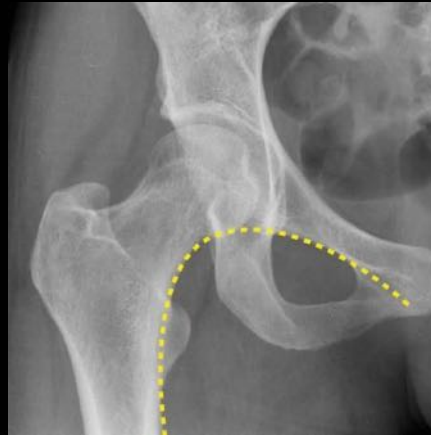
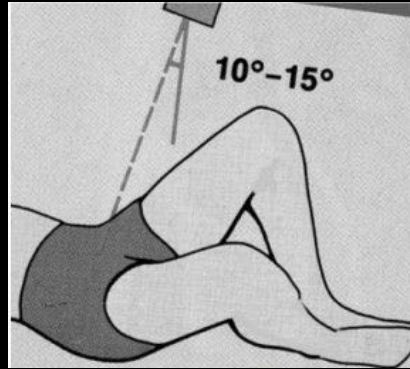
Hip XR: What is the diagnosis?

- Intertrochanteric Fracture
- Subtrochanteric Fracture
- Femoral head fracture
- Neck of Femur Fracture
- Hip Dislocation

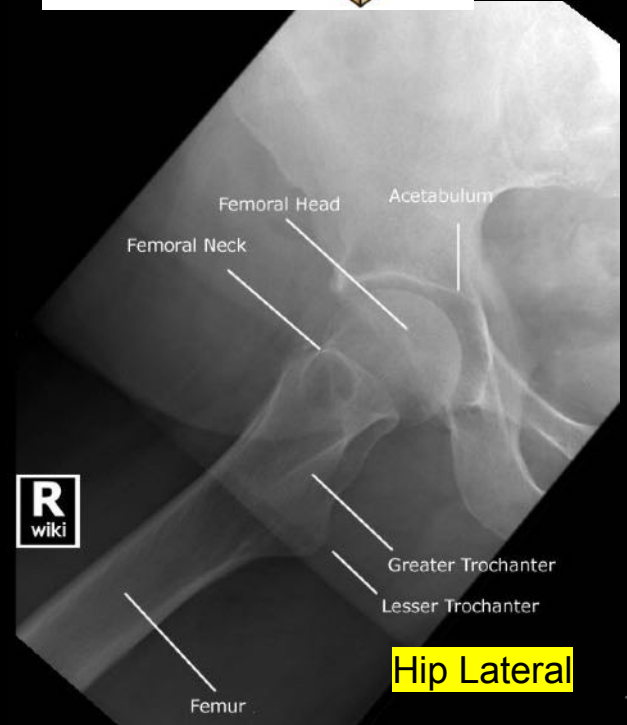
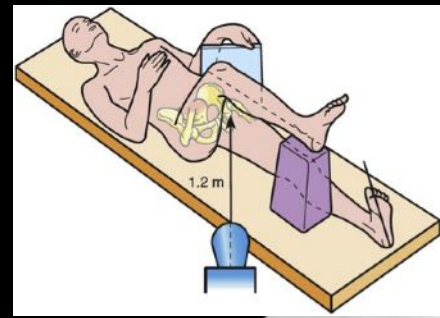
Hip XR



Hip AP



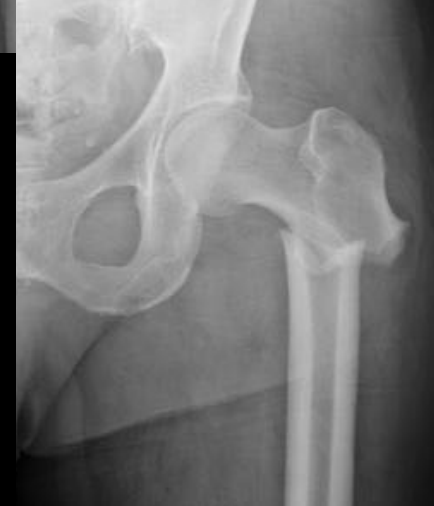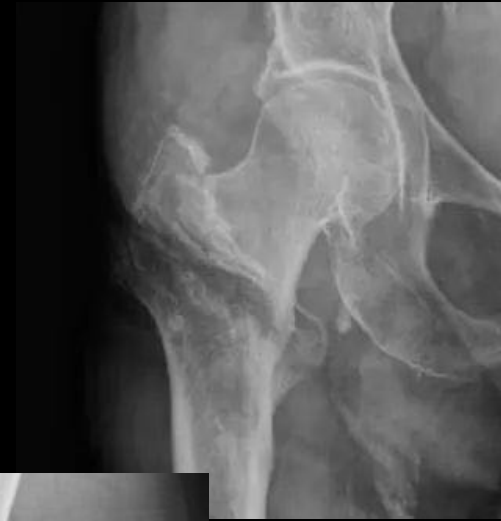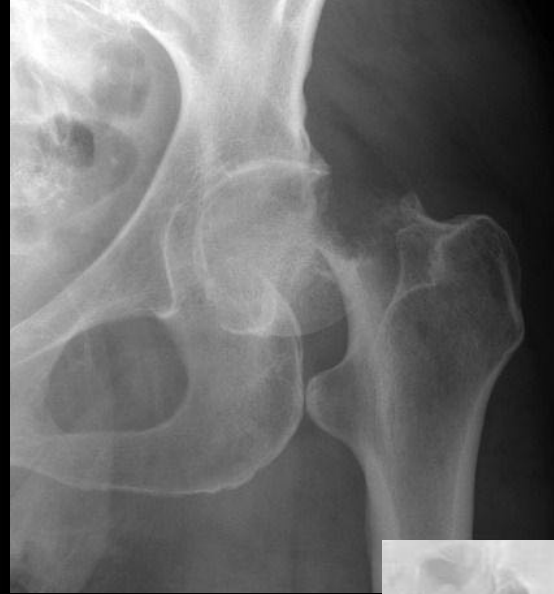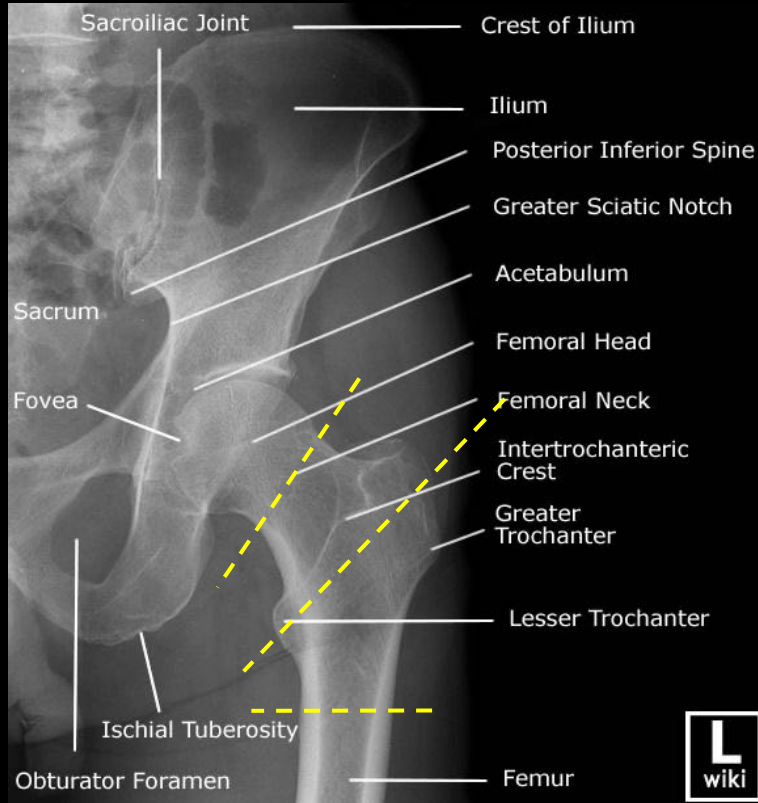
Shenton's Line



Hip Lateral



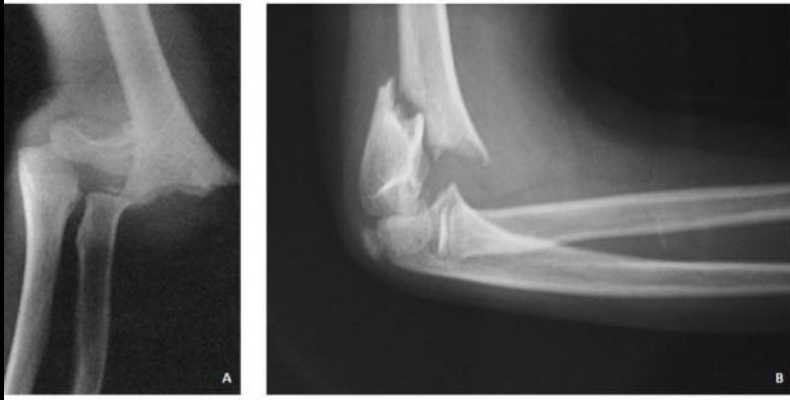Hip Fractures





Elbow: What is the diagnosis?

Q3

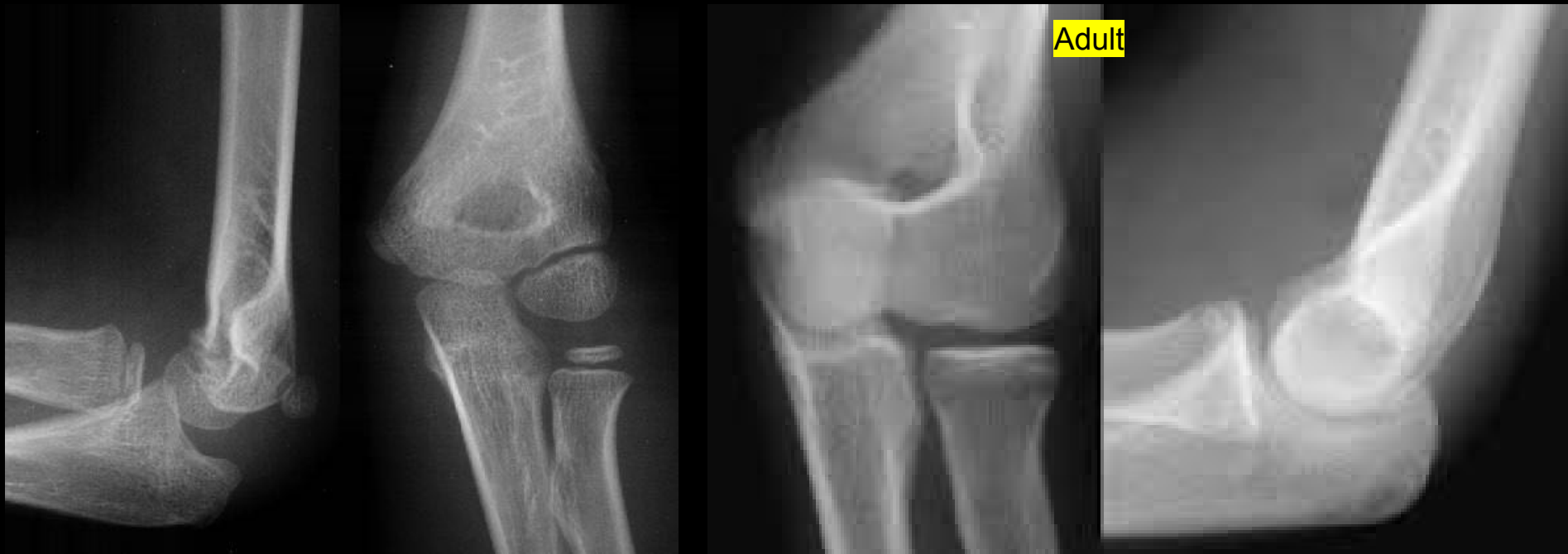

🕒 19

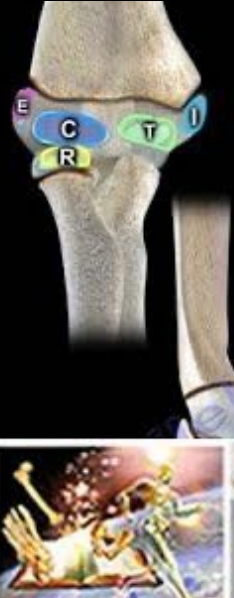Elbow: What is the diagnosis?

- Lateral Condyle Fracture
- Terrible Triad
- Posterior Elbow Dislocation
- Non Accidental Injury
- Supracondylar Fracture

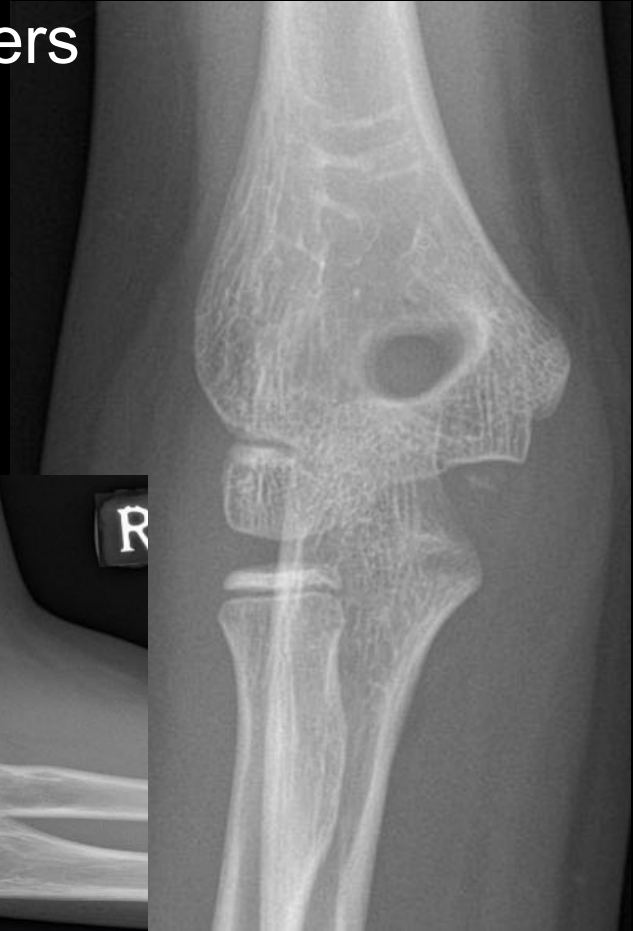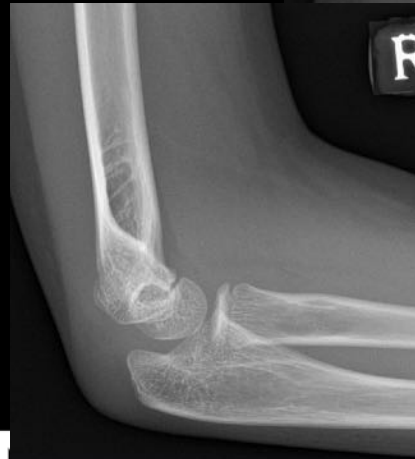Skeletally Immature Upper Limb XR



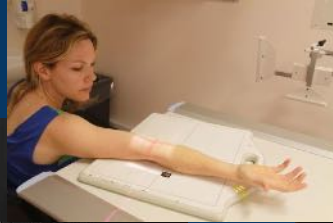How mature? Elbow Ossification Centers



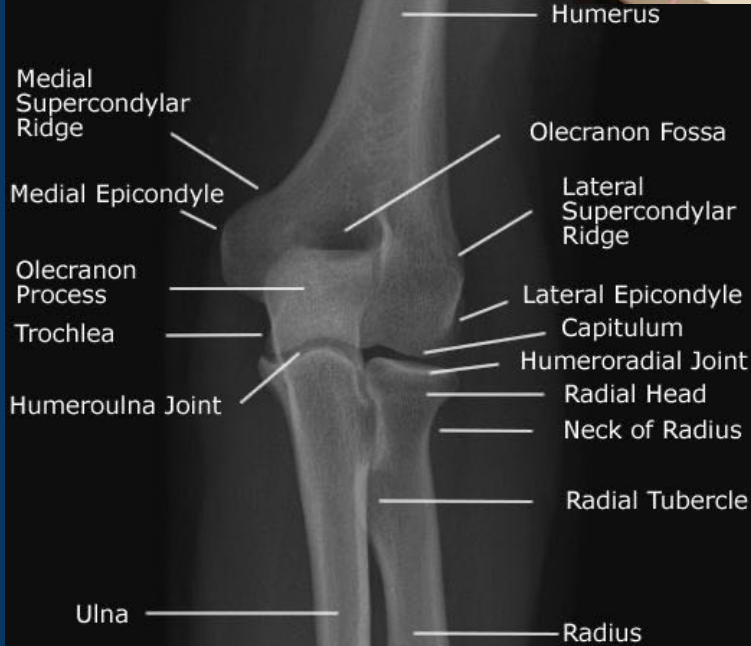- C**apitellum **1 yr.**
- R**adial Head **3 yrs.**
- I**nternal Epicondyle **5 yrs.**
(medial)
- T**rochlea **7 yrs.**
- O**lecranon **9 yrs.**
- E**xternal Epicondyle **11 yrs.**
(lateral)



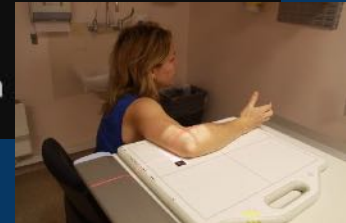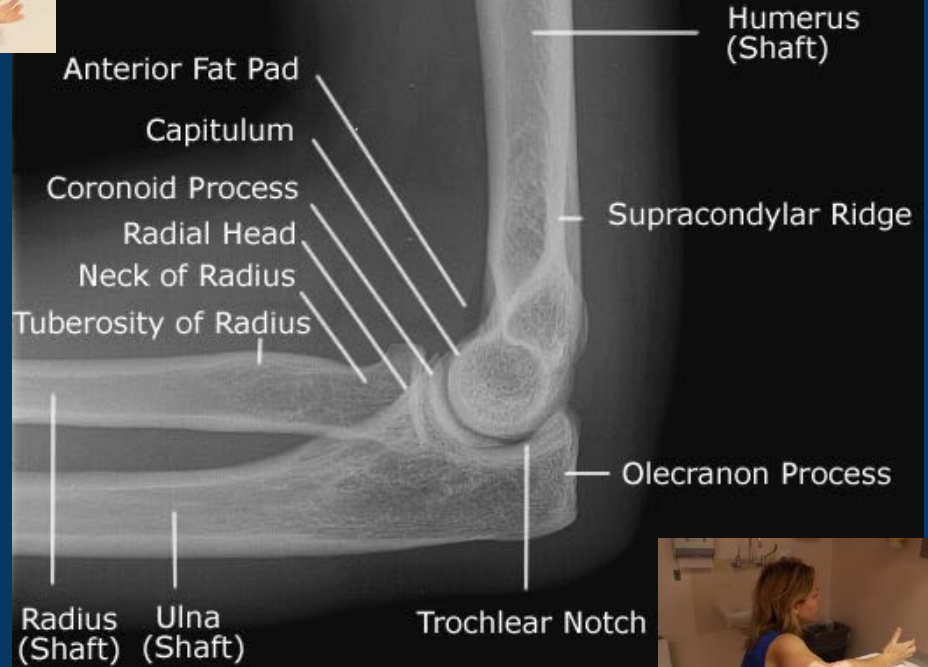
Normal Elbow XR



Elbow AP



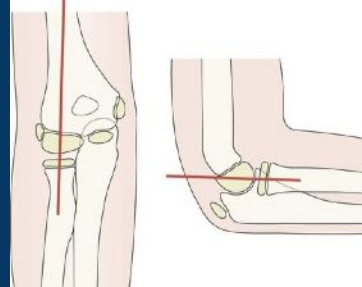
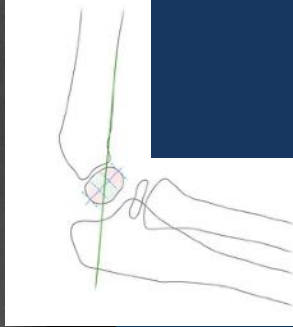
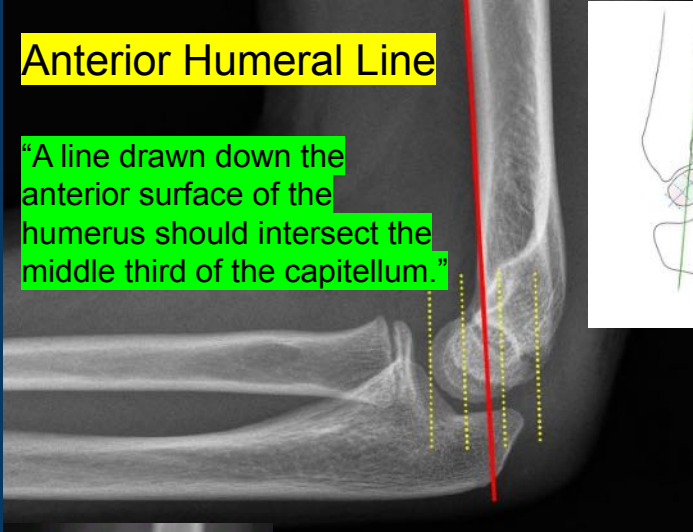
Elbow Lateral



2 Lines for Elbow (*Paeds*)

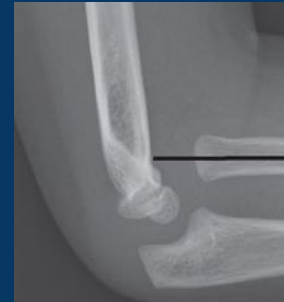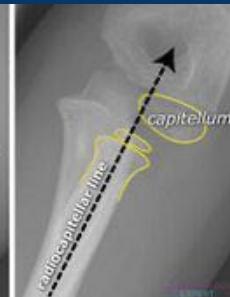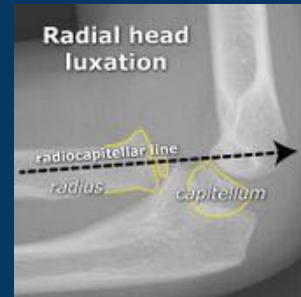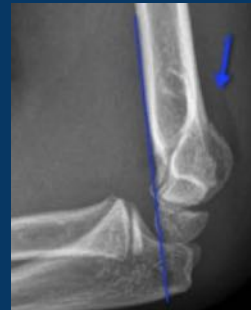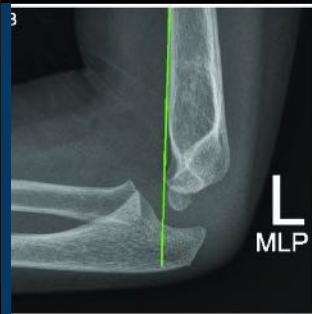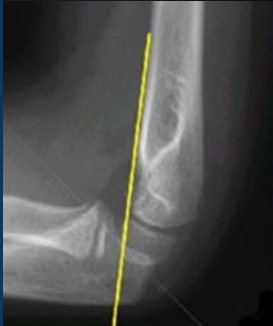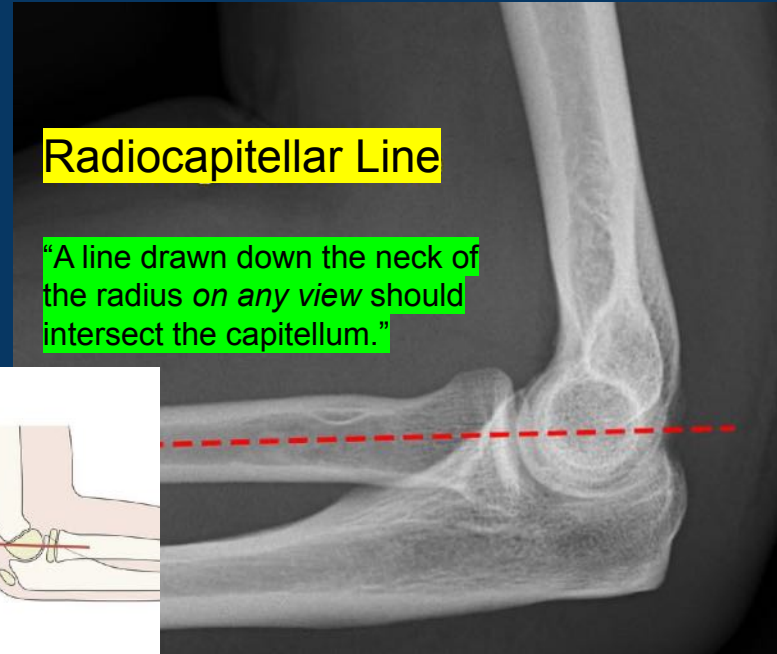
Anterior Humeral Line

"A line drawn down the anterior surface of the humerus should intersect the middle third of the capitellum."

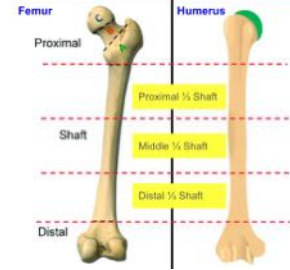

Radiocapitellar Line

"A line drawn down the neck of the radius on any view should intersect the capitellum."



Approach to Fracture XR



0. Primer [Think of the principles]

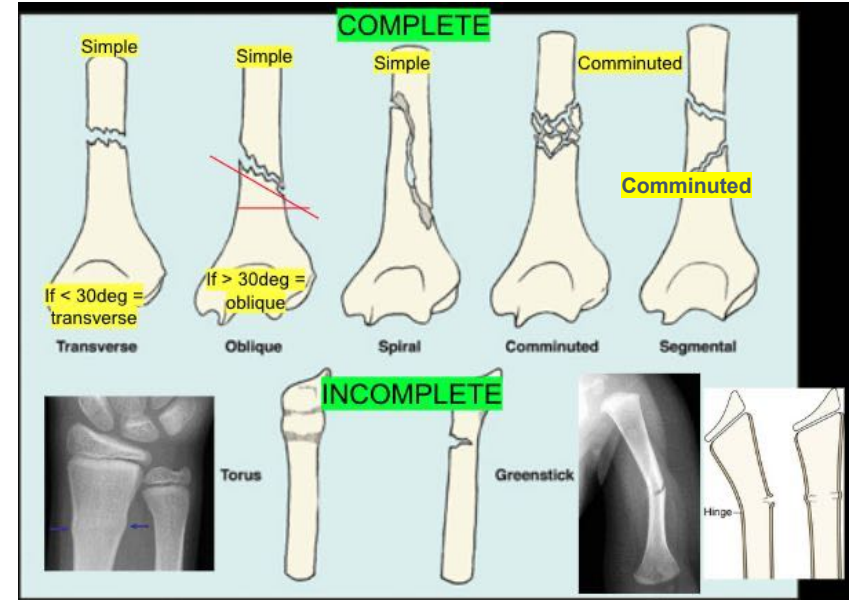
- XR of what?
- Skeletally mature?
- 2 views?

1. What Bone is fractured? Location of fracture?

- **Proximal** (intra/ extra-articular)/ **Shaft** (further by thirds)/ **Distal** (intra/ extra-articular)
- OR **Special anatomical names**
 - E.g. UL - Supracondylar #, Lateral condyle #, Medial condyle #, Olecranon #...
 - E.g. LL - Neck of femur #, Intertrochanteric #, Subtrochanteric #, Tibia plateau #, Pilon #...

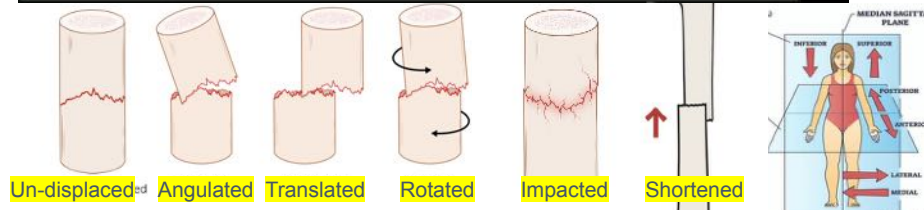
2. What is the Pattern of fracture?

- Complete/ Incomplete? [Is fracture through and through?]
- **Complete** - what pattern?
 - Simple - Transverse/ Oblique/ Spiral
 - Comminuted/ Segmental
- **Incomplete** - What pattern? (think paed)
 - Torus/ Greenstick



3. Displaced or Undisplaced? (Look for Lines or Symmetry)

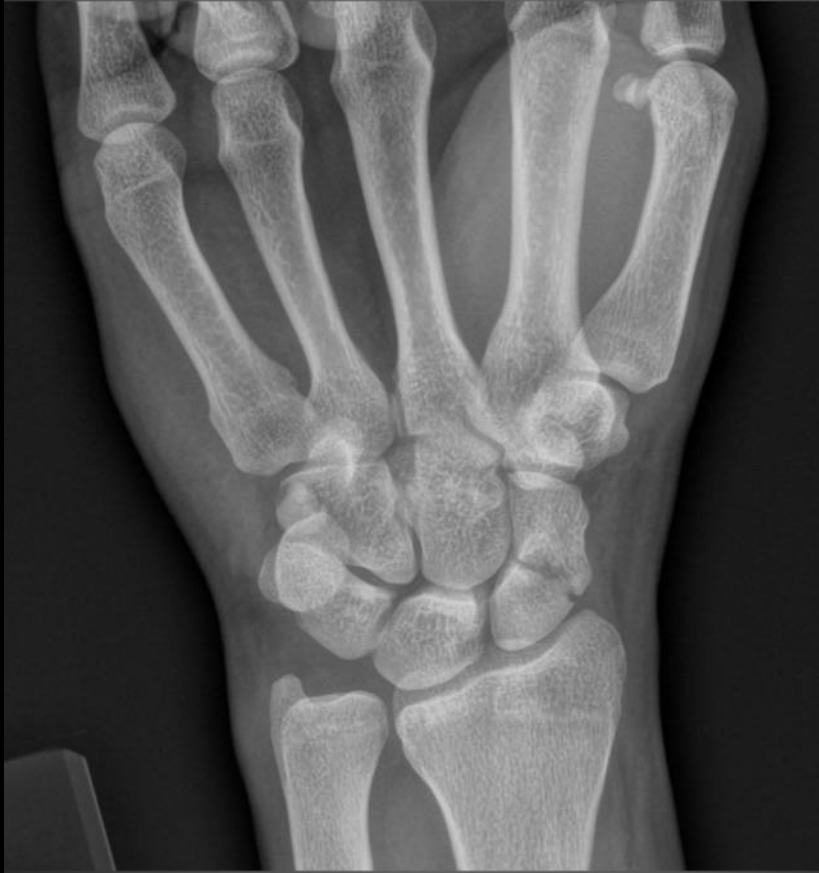- **Undisplaced** = lines not disrupted
- **Displaced** = Lines disrupted
 - **Type** of displacement?
 - Translated/ Angulated/ Rotated/ Shortened/ Impacted
 - What **direction** is it displaced?
 - Reference from distal fragment
 - Anterior/ Posterior/ Medial/ Lateral





Wrist: What is the diagnosis?

Q4



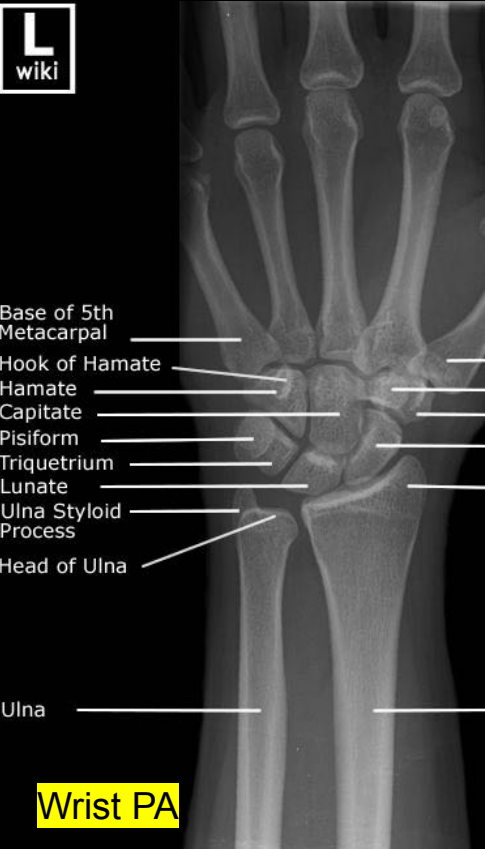🕒 18

Wrist: What is the diagnosis?

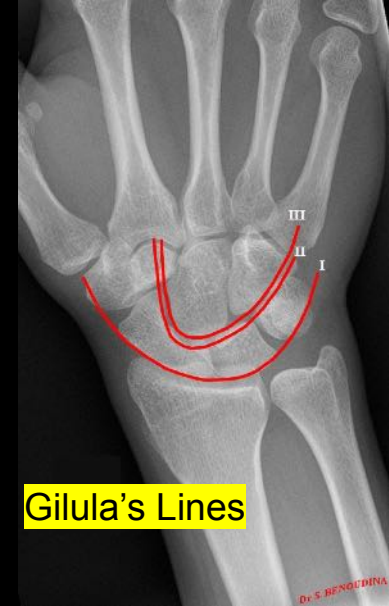
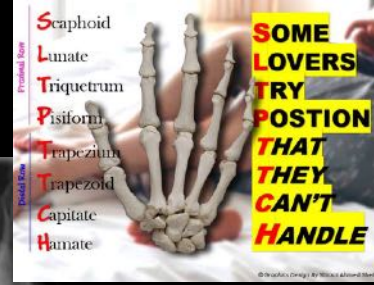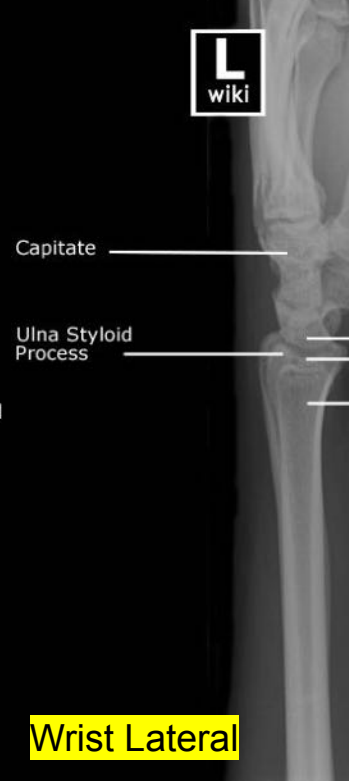- Perilunate dislocation
- Distal Radius Fracture
- Scaphoid Fracture
- Boxer's Fracture
- First CMCJ Arthritis

Normal Wrist XR

L
wiki

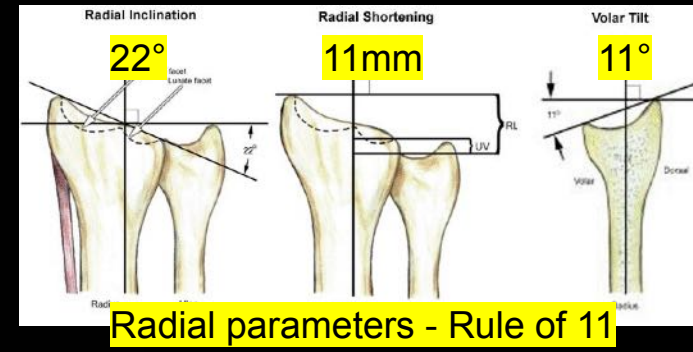


L
wiki




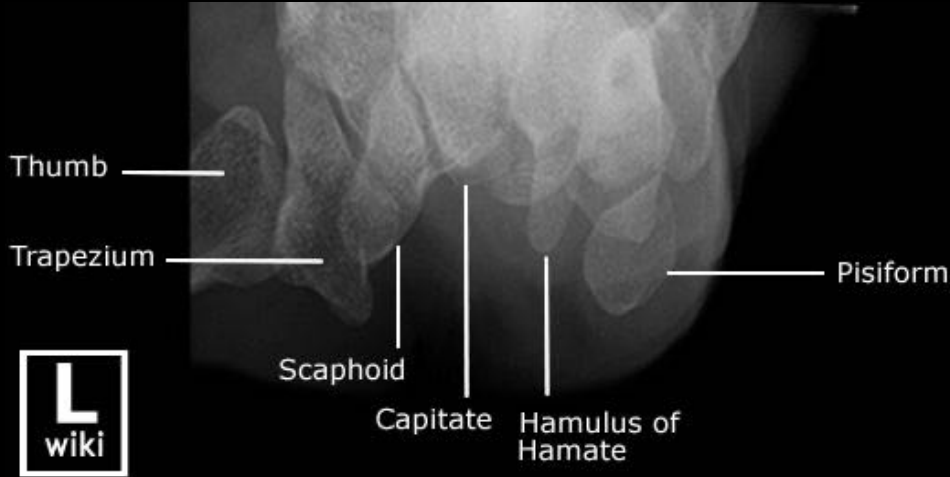
- Base of 5th Metacarpal
- Hook of Hamate
- Hamate
- Capitate
- Pisiform
- Triquetrum
- Lunate
- Ulna Styloid Process
- Head of Ulna
- Ulna
- Base of 1st Metacarpal
- Trapezoid
- Trapezium
- Scaphoid
- Radial Styloid Process
- Radius
- Capitate
- Ulna Styloid Process

- 1st Metacarpal
- Trapezium
- Scaphoid
- Pisiform
- Lunate
- Radius
- Ulna

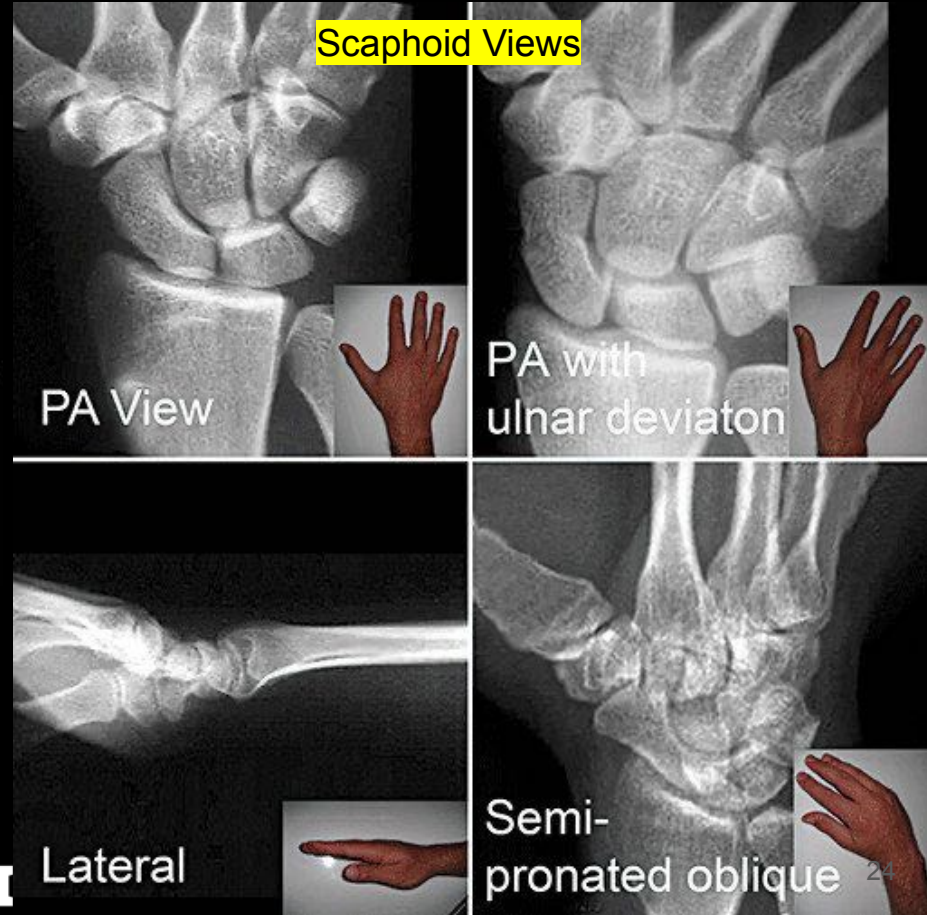


Radial parameters - Rule of 11

Wrist Special Views



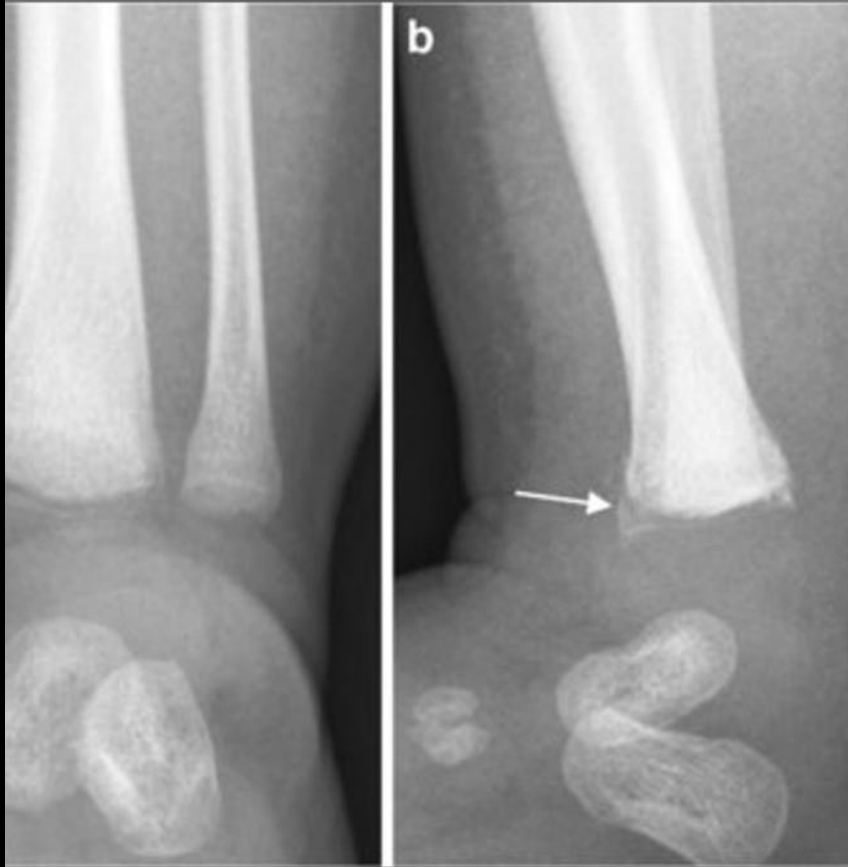Carpal Tunnel View





Ankle: What is the diagnosis?

Q5

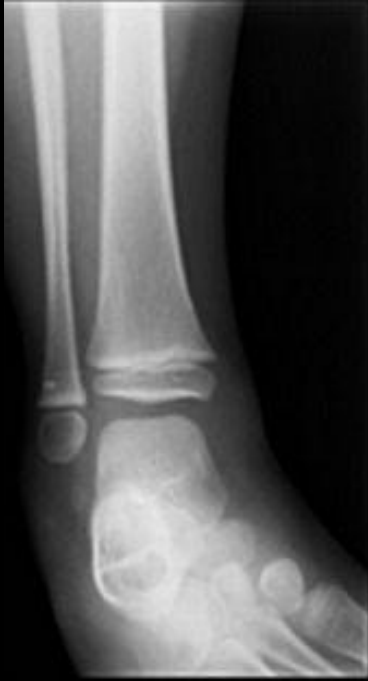

⌚ 15

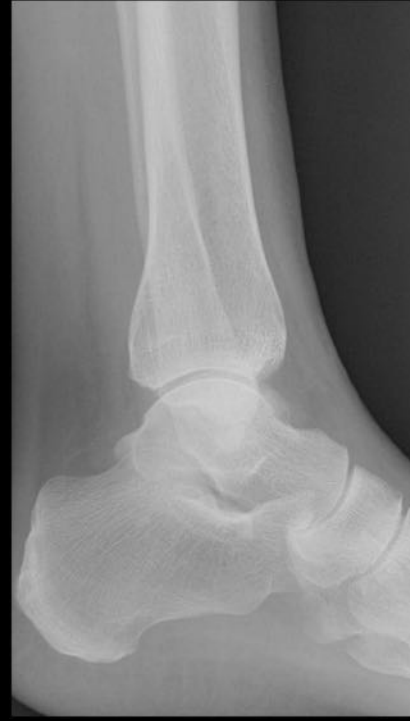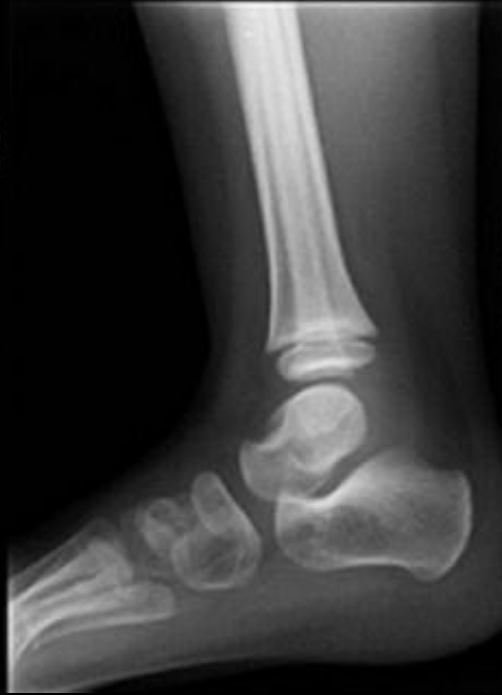Ankle: What is the diagnosis?

- Talar Neck Fracture
- Non-accidental Injury
- Ankle Dislocation
- Septic Arthritis
- Stress Fracture

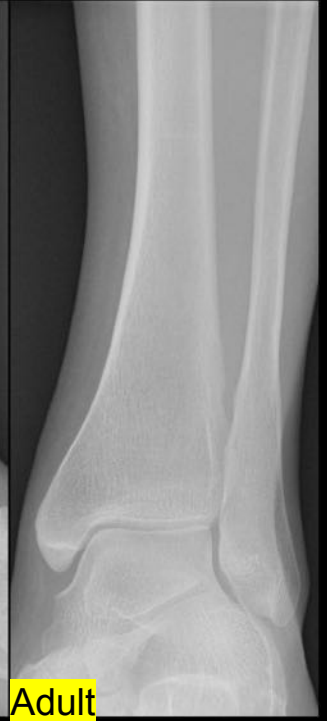Skeletally Immature Lower Limb XR



R



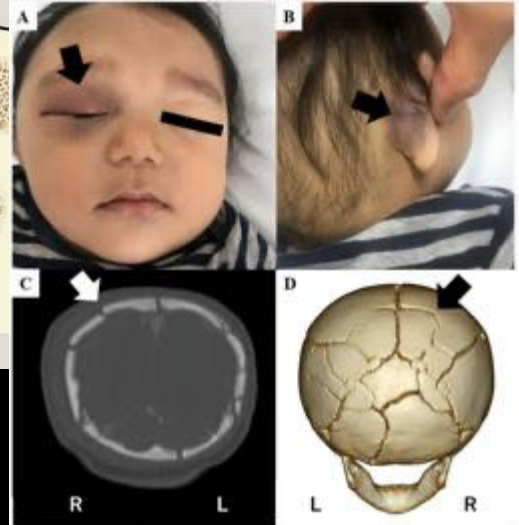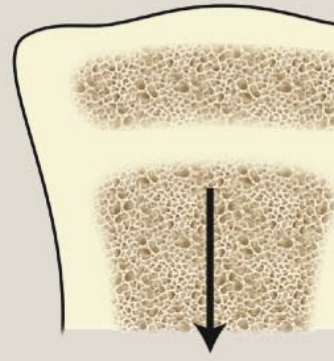
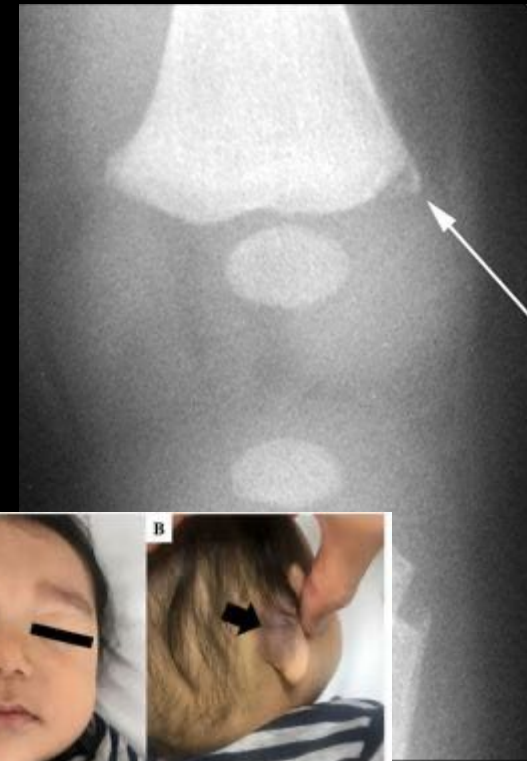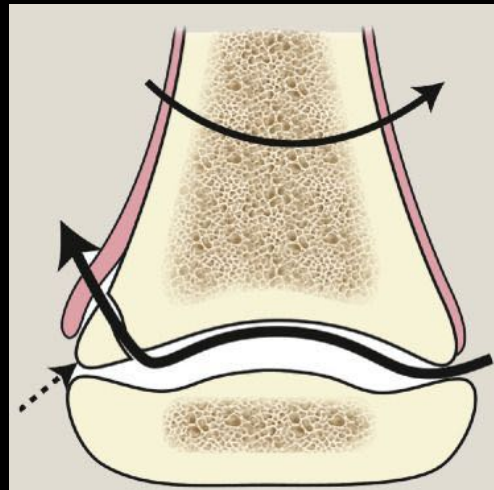
Adult



Corner Fractures

What's next?

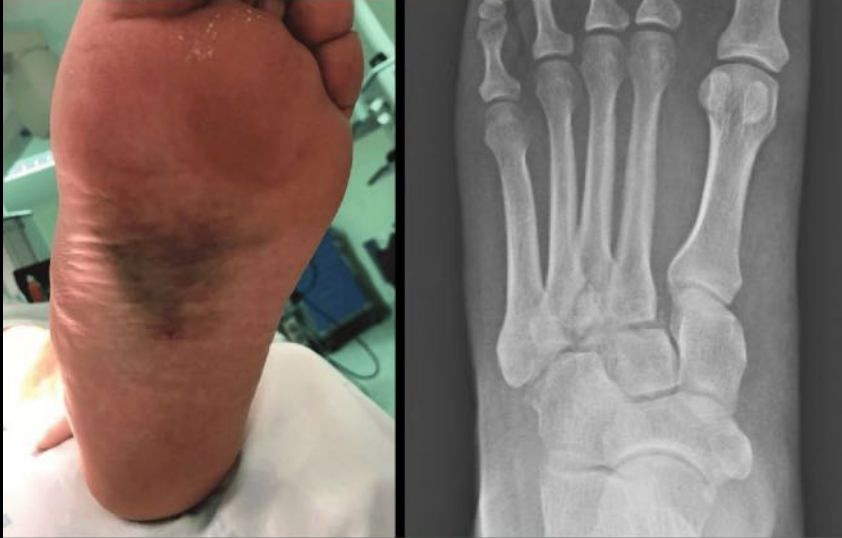- History → High index of suspicion
- Examine for other features
 - Eye - retinal hemorrhages
 - Bruises of different ages
 - Base of skull fractures - battles sign, raccoon eyes
- Investigate
 - Skeletal Survey looking for further injuries
 - AP/Lateral skull, Lateral of C/T/L spine, AP Pelvis and extremities, AP chest
- Management
 - Bring in Social worker for comprehensive assessment, Police, Foster Care





Foot: What is the diagnosis?

Q6

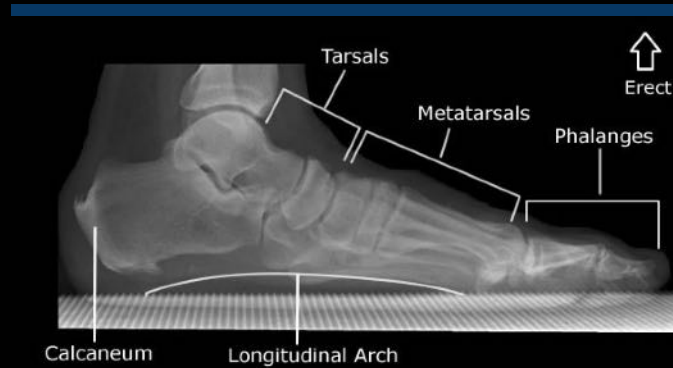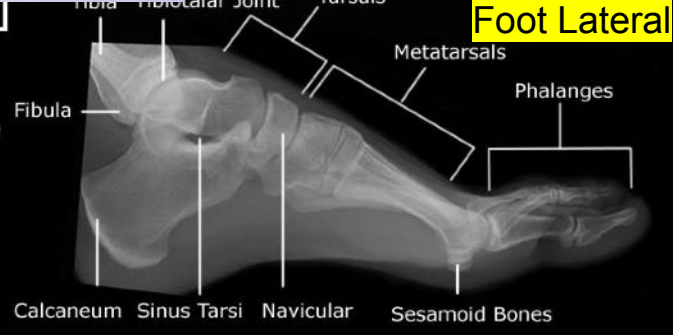

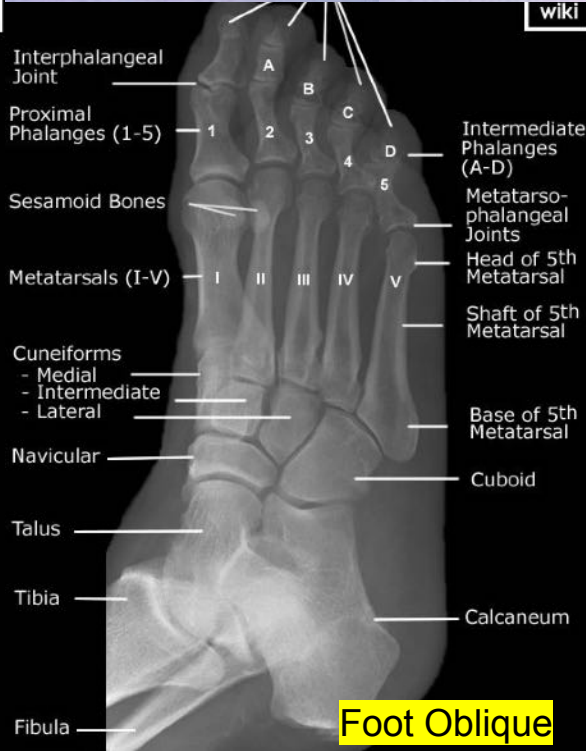
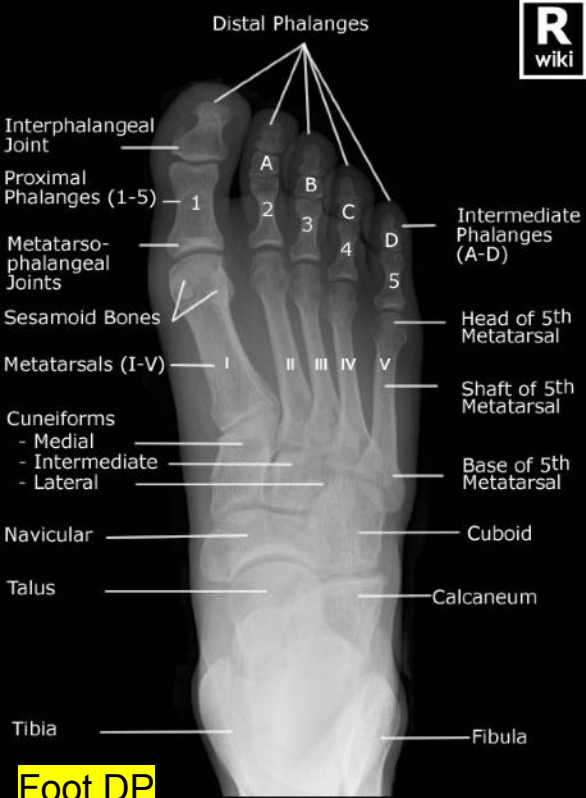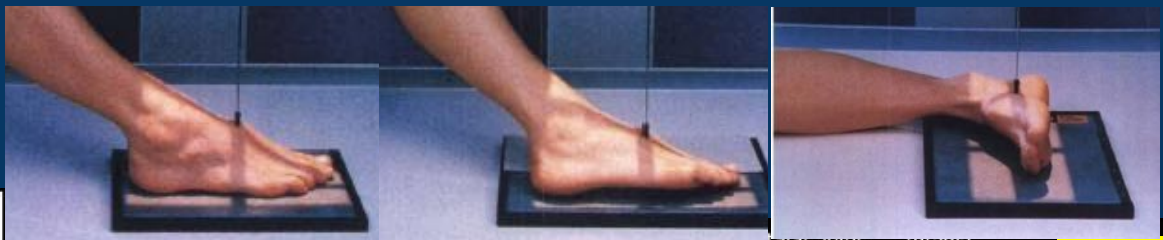🕒 16

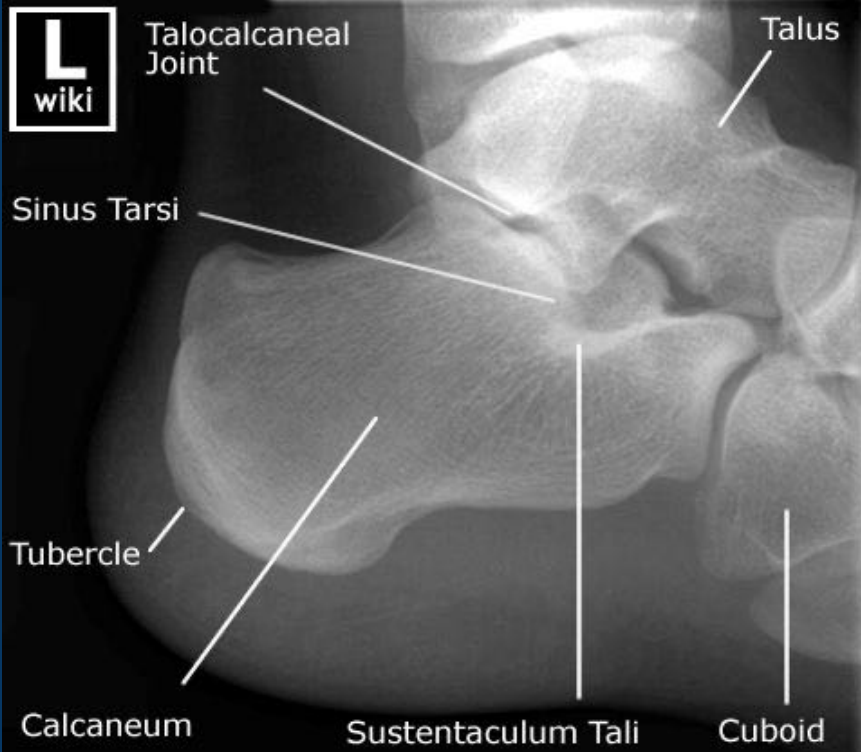
Foot: What is the diagnosis?

- Jones Fracture
- Nutcracker Fracture
- Navicular Stress Fracture
- Lis Franc Injury
- Middle Cuneiform Fracture

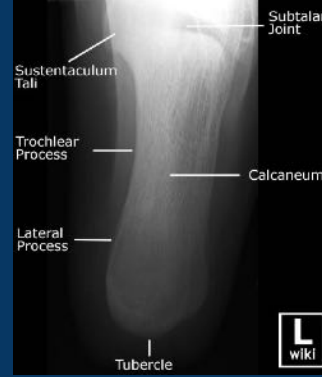
Normal Foot XR



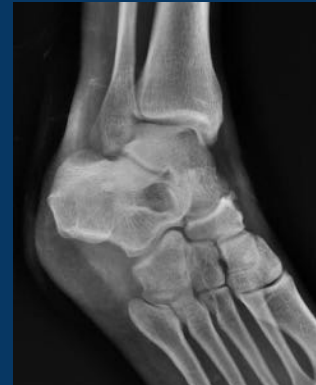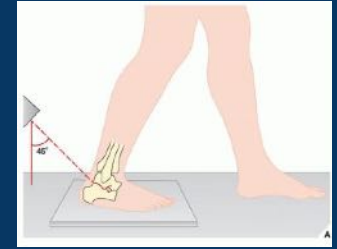
Normal Calcaneus XR



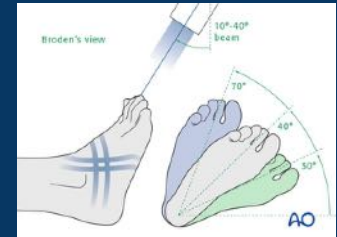
Calcaneum Lateral



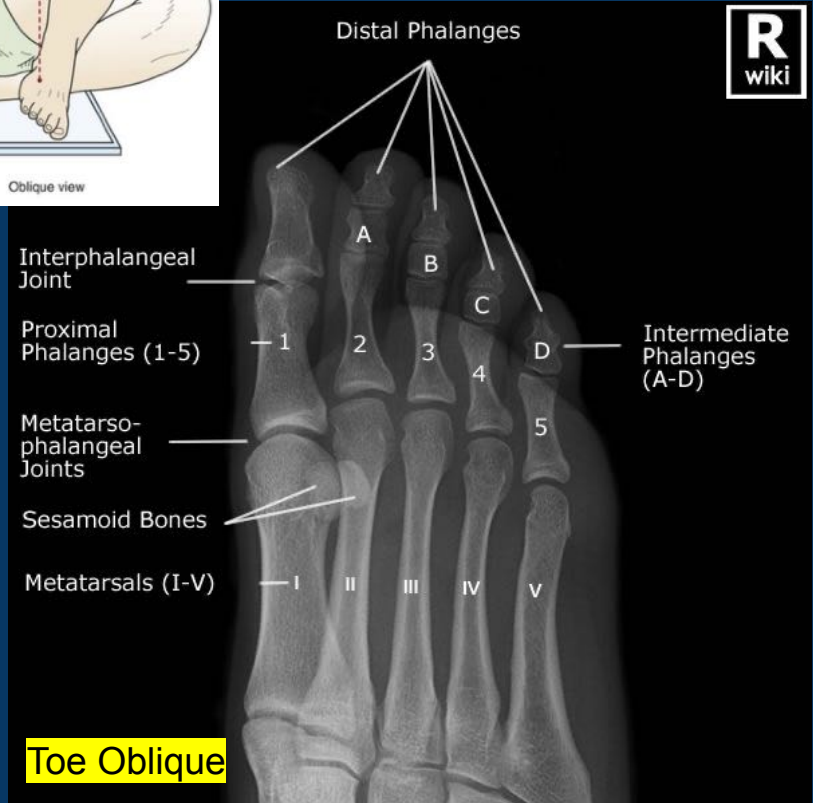
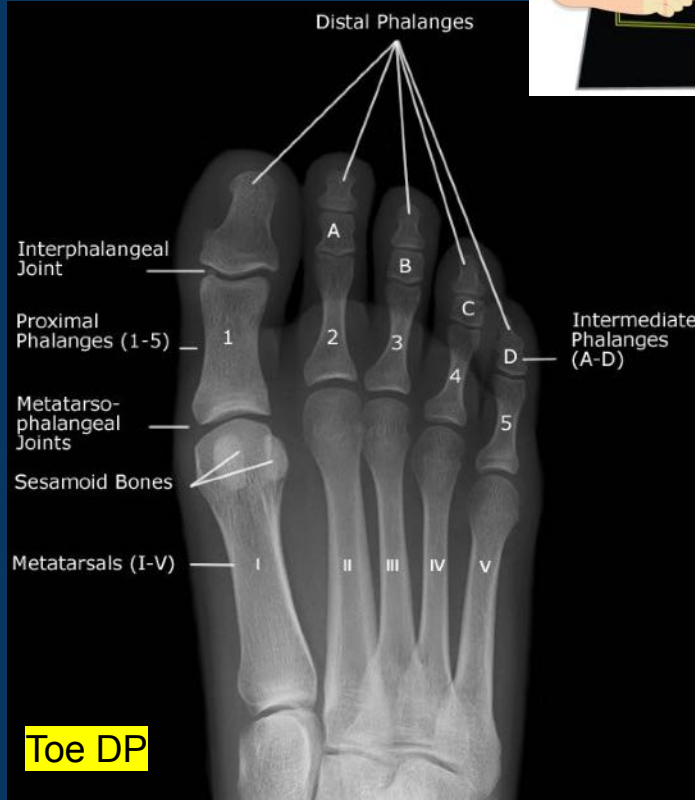
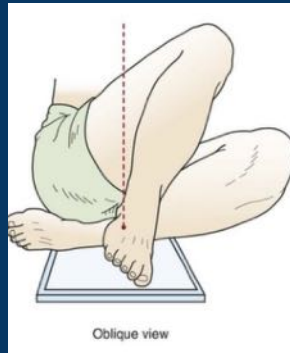
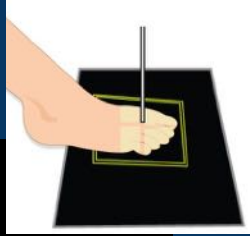
Calcaneum Axial Harris View



Calcaneum Oblique Broden's View



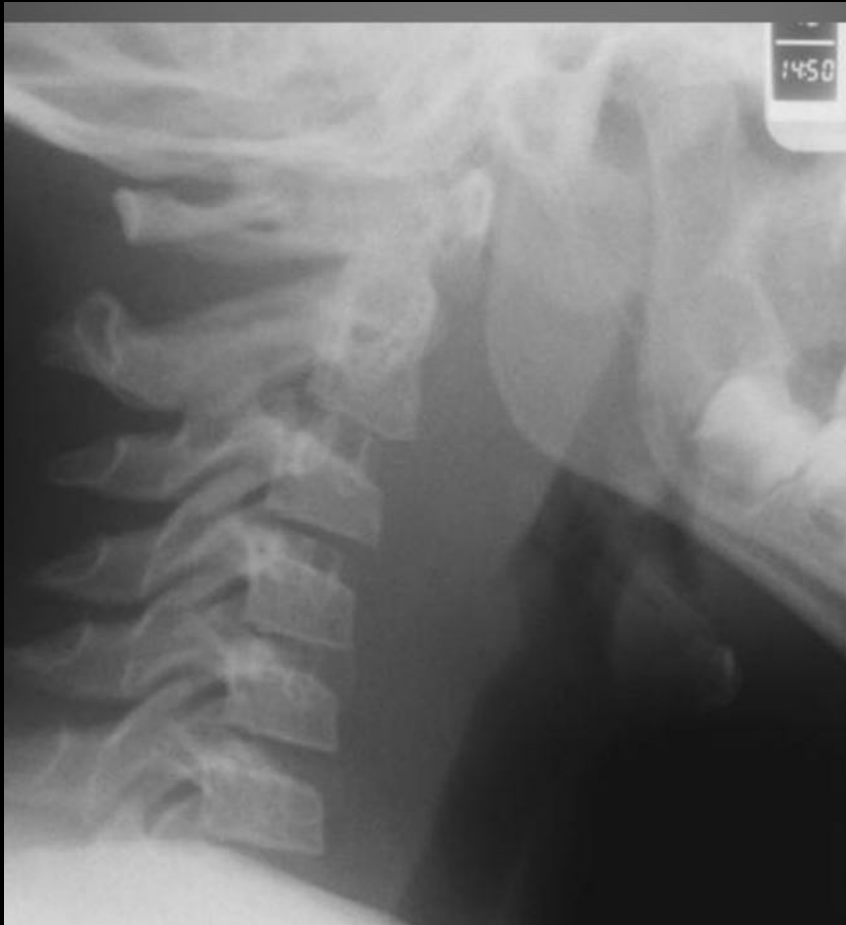Normal Toe XR





Spine: What is the diagnosis?

Q7



Spine: What is the diagnosis?

C5 Chance Fracture

0%

C6 Burst Fracture

0%

Retropharyngeal Swelling

0%

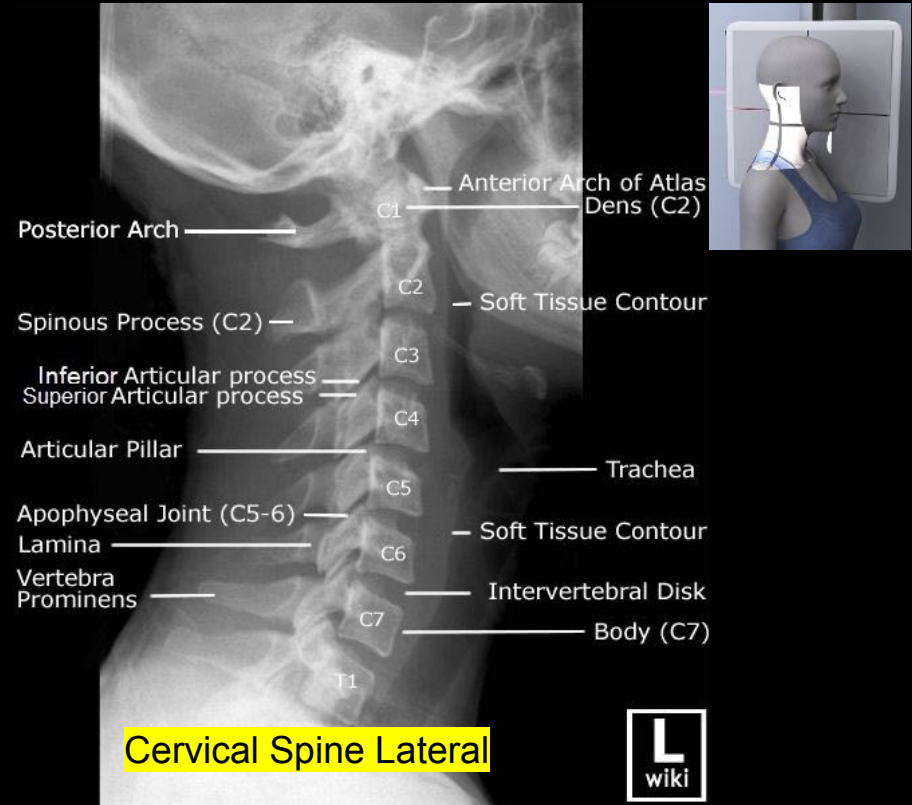
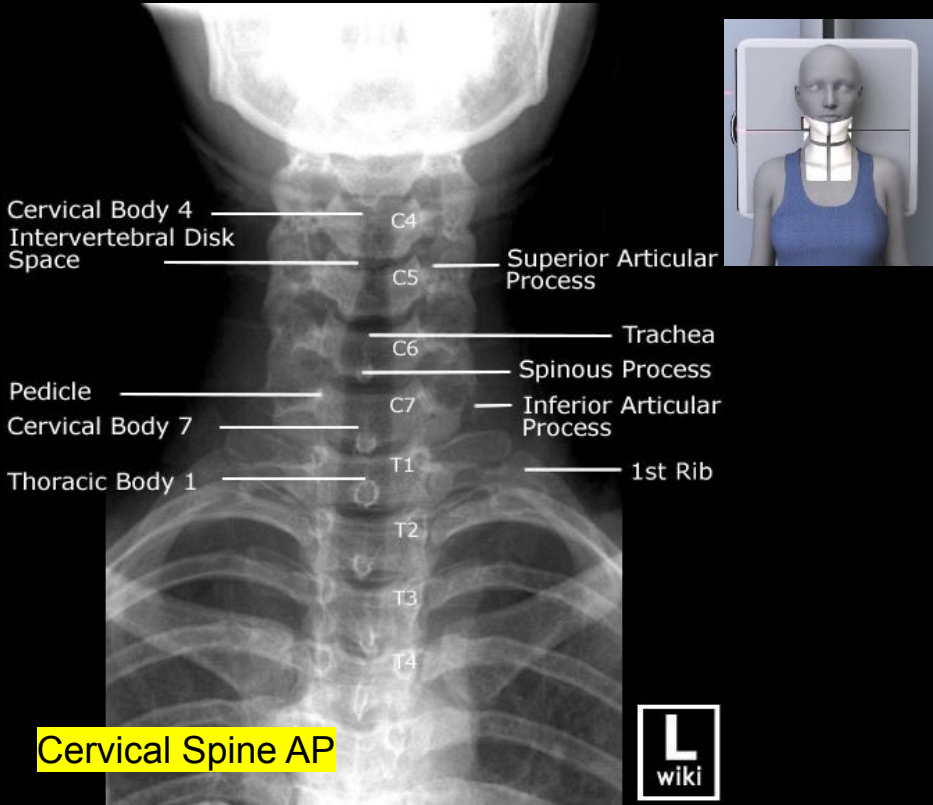
C4/5 Spondylolisthesis

0%

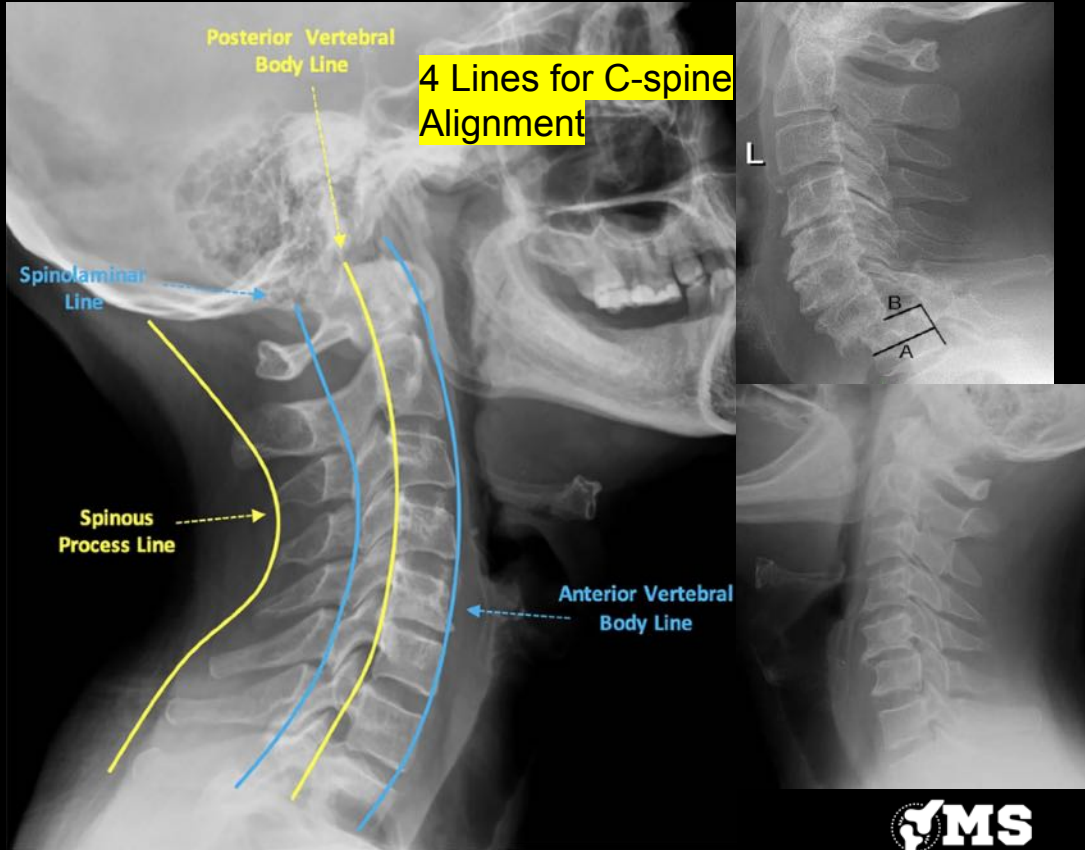
Hangman Fracture

0%

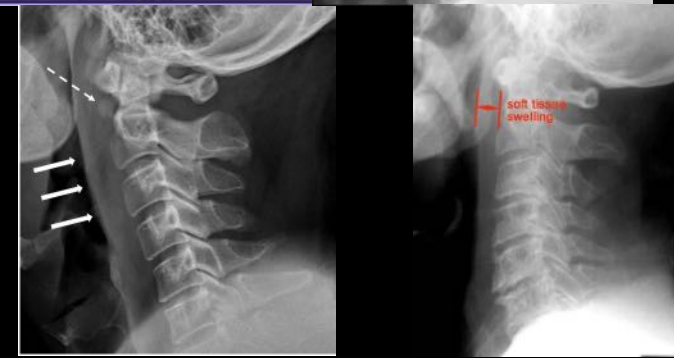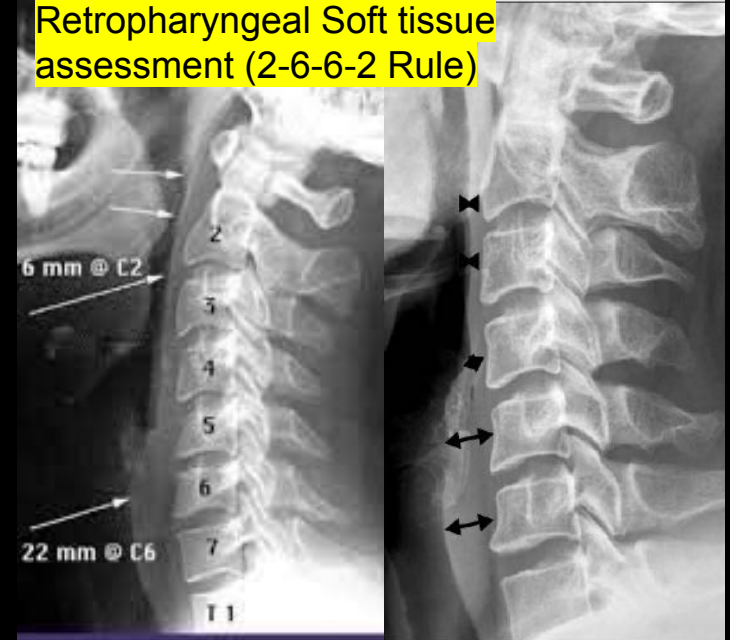
Cervical Spine Normal XR



Important Lines for Cervical Spine



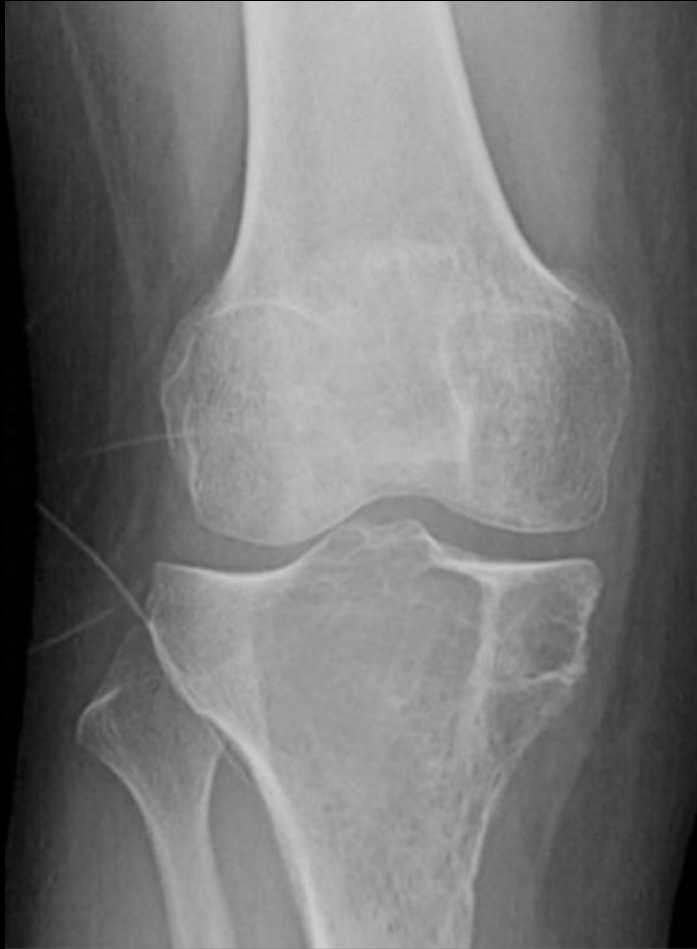Retropharyngeal Soft tissue assessment (2-6-6-2 Rule)





Knee: What is the diagnosis?

Q8



🕒 17

Knee: What is the diagnosis?

- Osteosarcoma
- Knee Osteoarthritis
- Giant Cell Tumor
- Osteoid osteoma
- Osteochondroma

Approach to Tumor XR

0. Primer [Think of the principles]

- XR of what?
- Skeletally mature?
- 2 views?

1. Where is the lesion?

- **Epiphysis** (only in immature skeleton)
- **Metaphysis** (Müller Box)
- **Diaphysis**
- In the Middle? "Meta-diaphyseal/ Epi-metaphyseal"

2. What is the Zone of Transition?

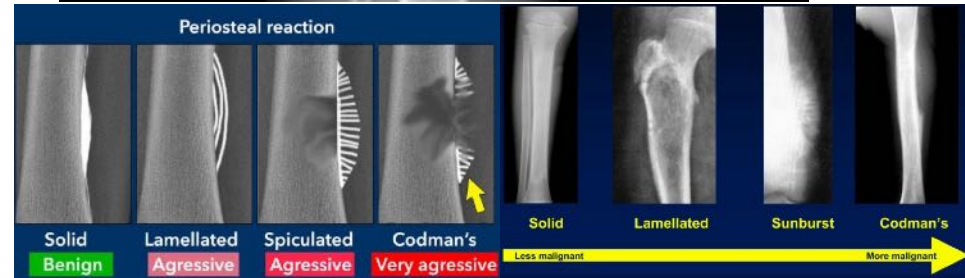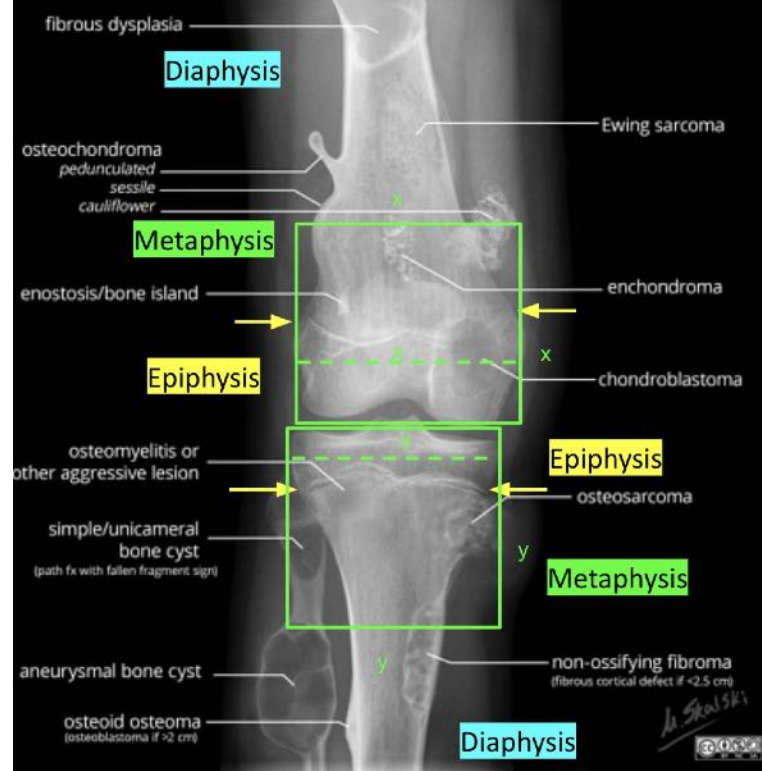
- **Wide zone** of transition aka "Diffuse", "Poorly-demarcated", "Moth-eaten", "Permeative" = **Implies malignant**
- **Narrow zone** of transition aka "Well-demarcated", "Geographical" = **Implies benign**
 - **"Expansile"** - Specific for ABC

3. Is there Periosteal Reaction?

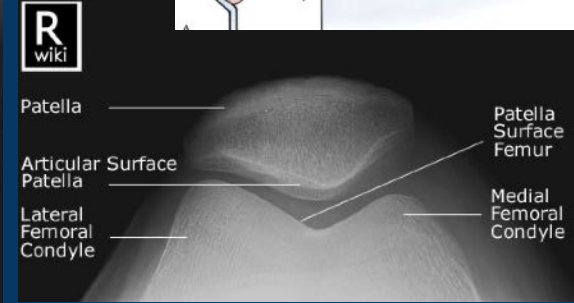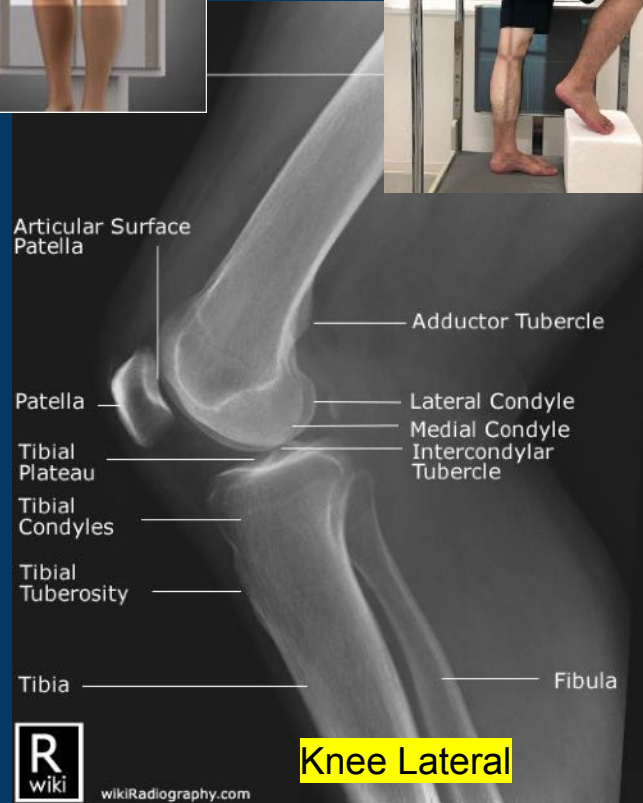
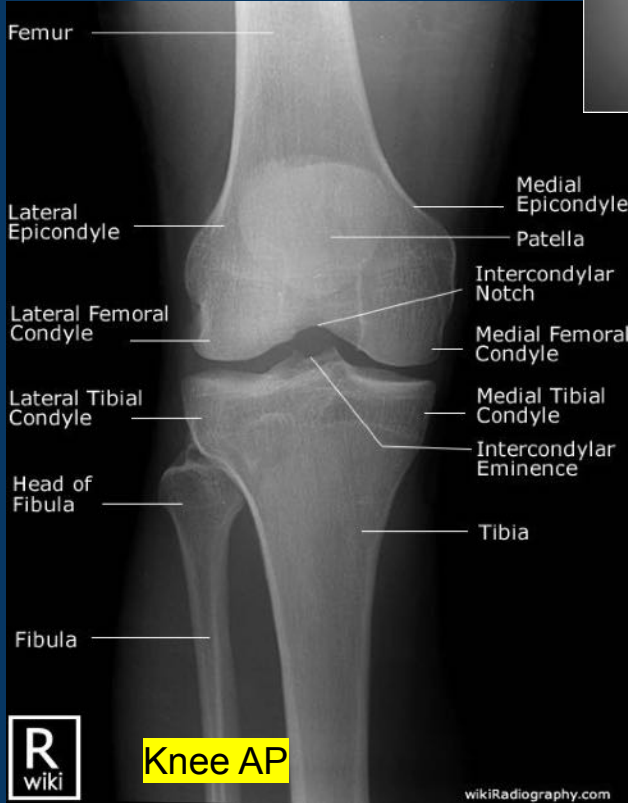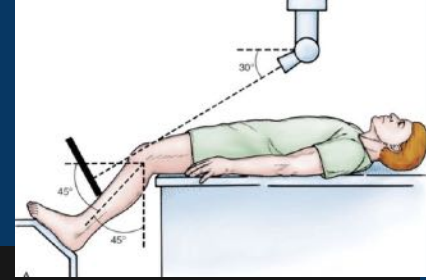
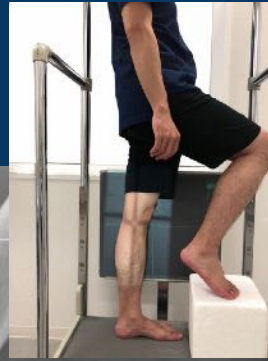
- Usually seen in **lesions with a wide zone of transition** (malignant)
- Reflects rate of growth = Solid < **Onion Skinning**/ Lamellated < **Sunburst**/ Spiculated < **Codman's Triangle**

4. What is the Matrix?

- **Lytic** = bone eaten away
- **Blastic** = new bone laid down
- **"Ground-glass"** = Bone replaced by fibre
- **"Rings and Arcs/ Popcorn"** → Bone replaced by cartilage



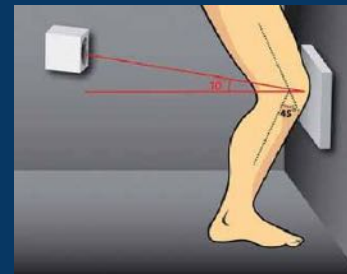
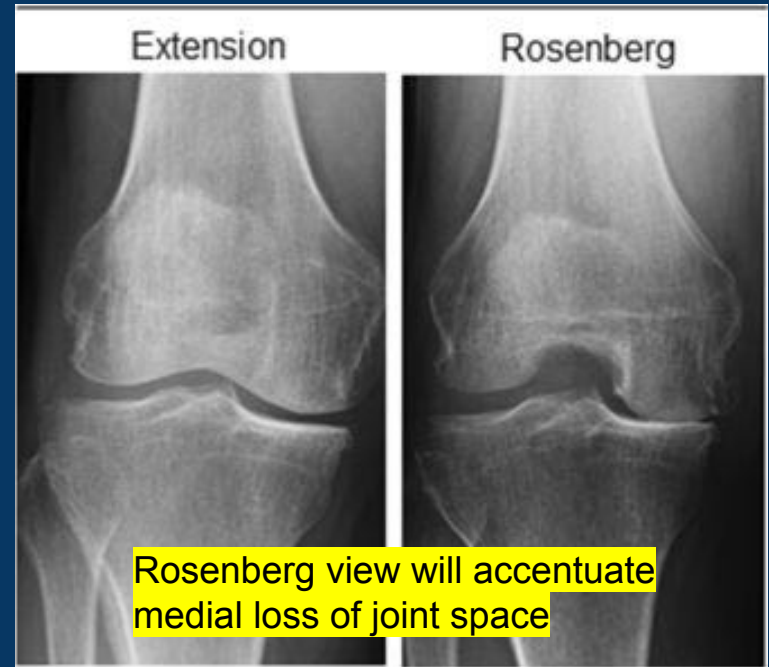
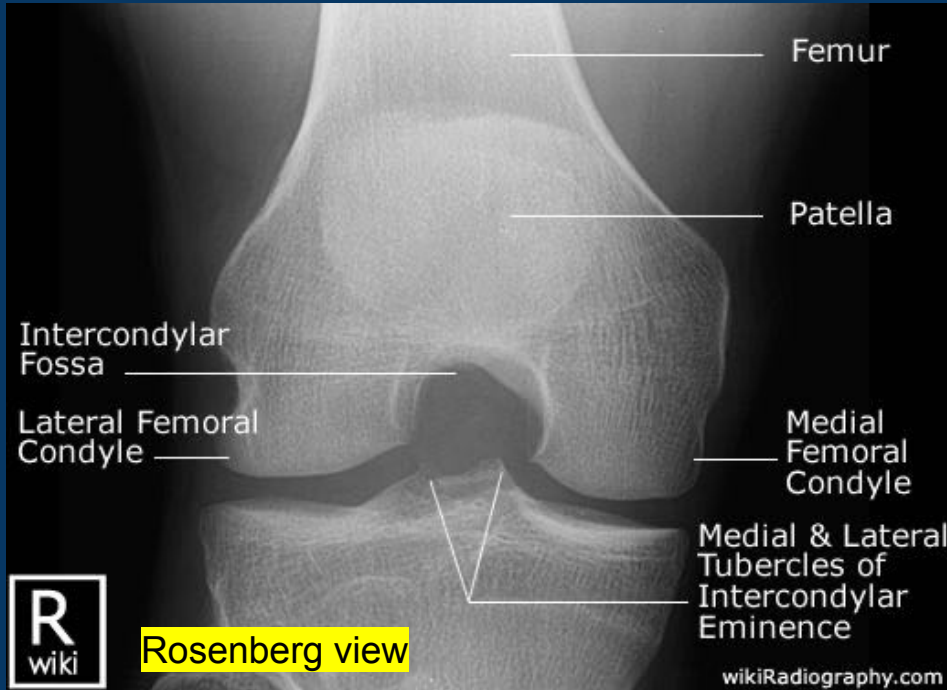
Normal Knee XR



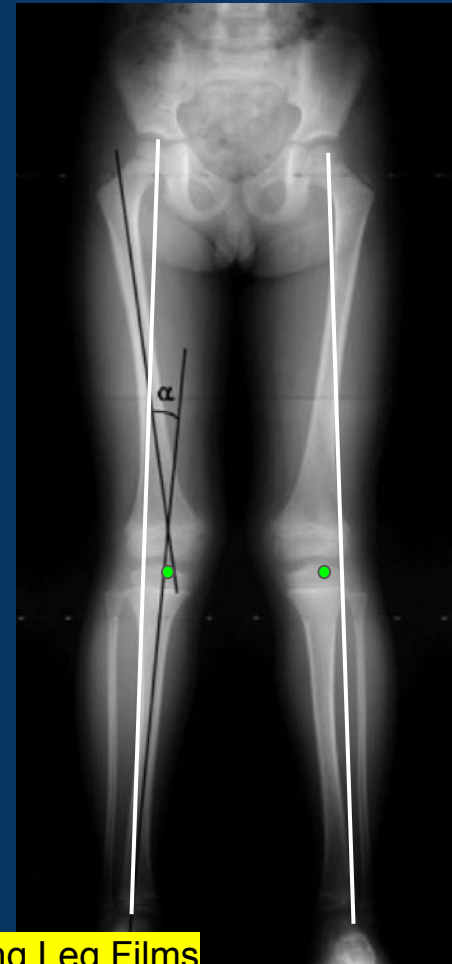
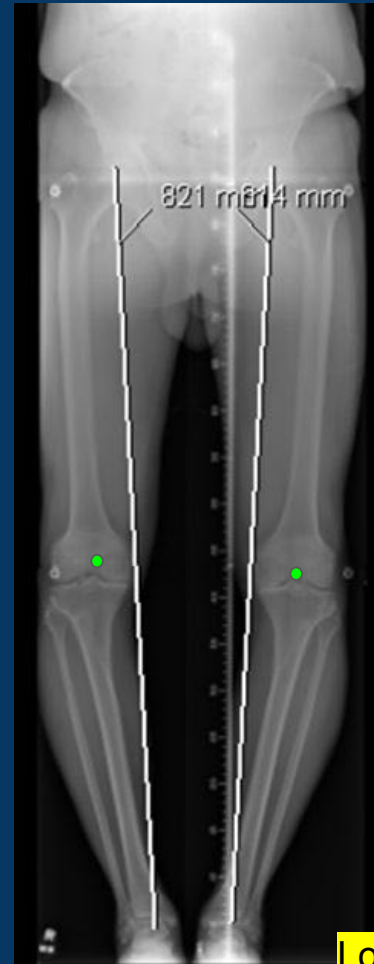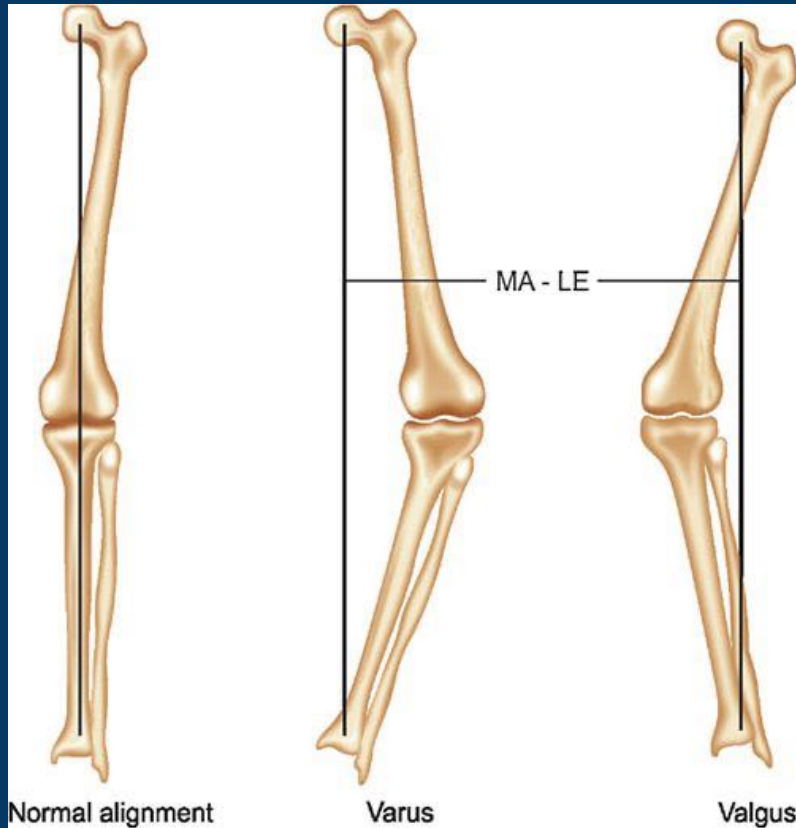
Skyline

Weight bearing will reveal loss of joint space better

Knee XR Special Views



Knee XR Special Views

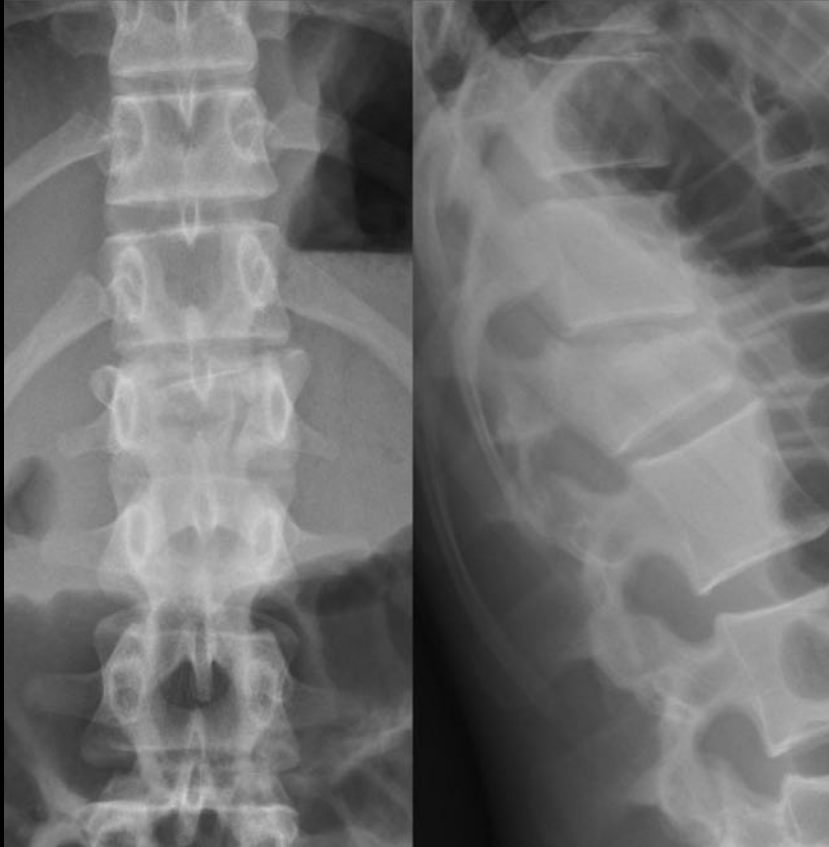


Long Leg Films



Spine: What is the diagnosis?

Q9

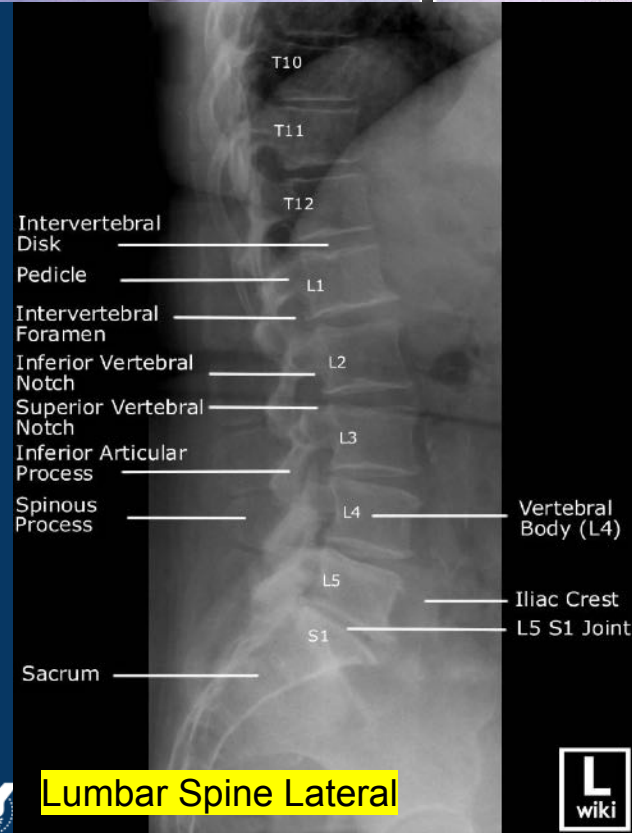
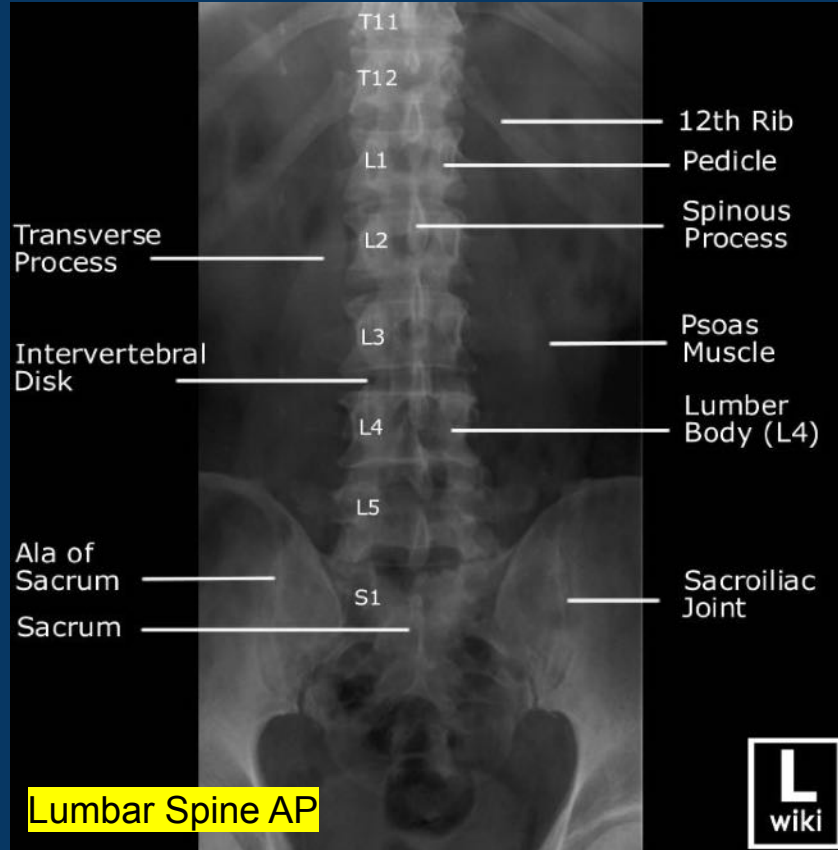
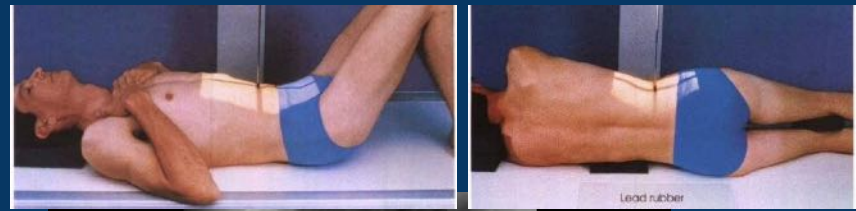


🕒 17

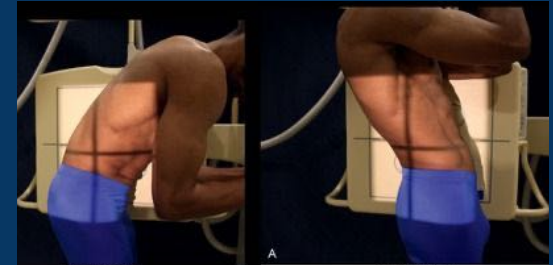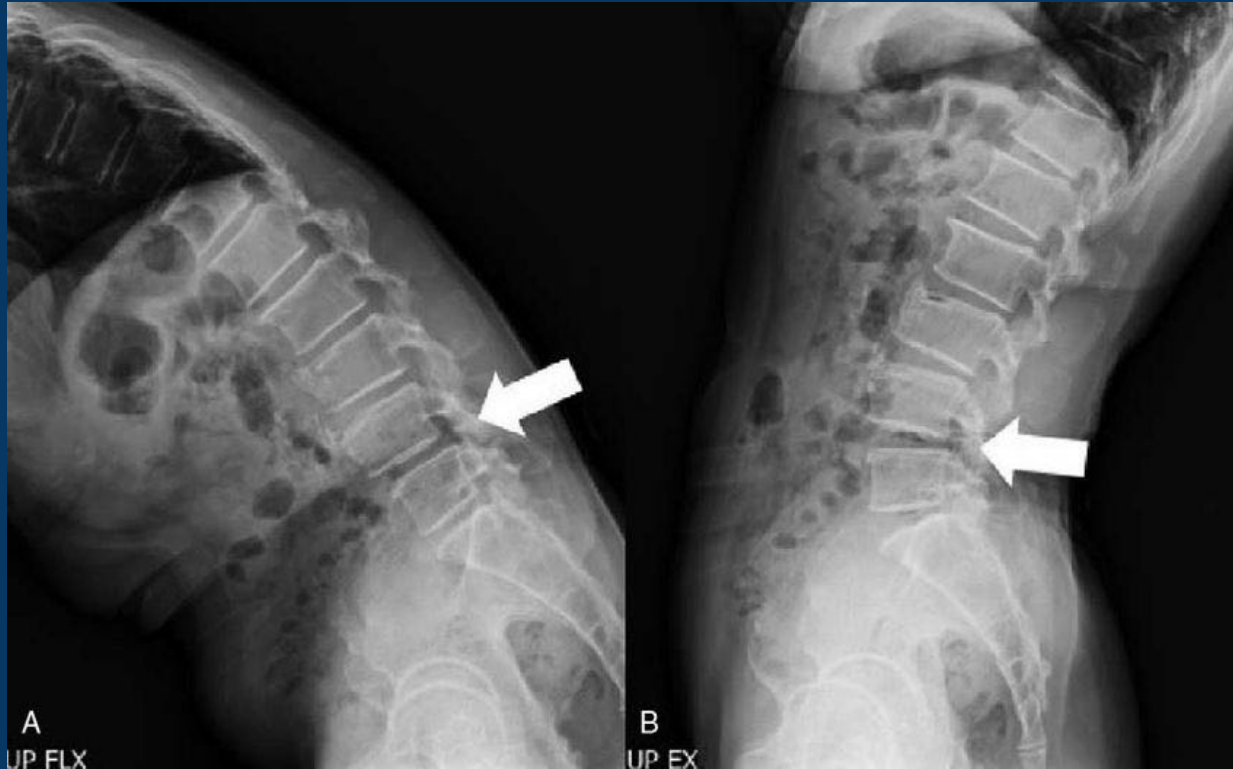Spine: What is the diagnosis?

- Spondylolisthesis
- Compression Fracture
- Spondylosis
- Burst Fracture
- Chance Fracture

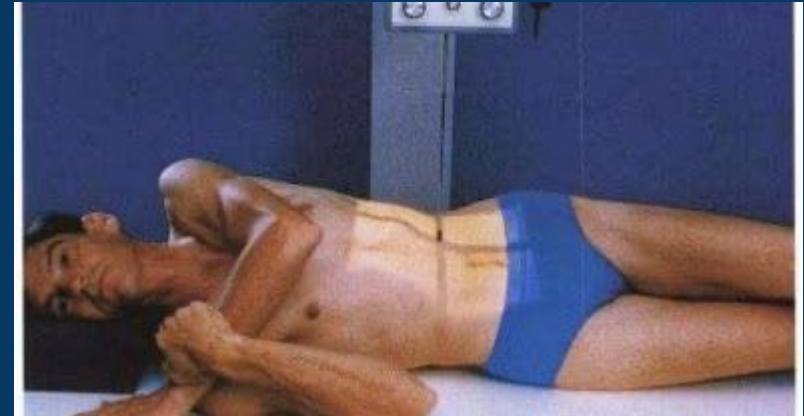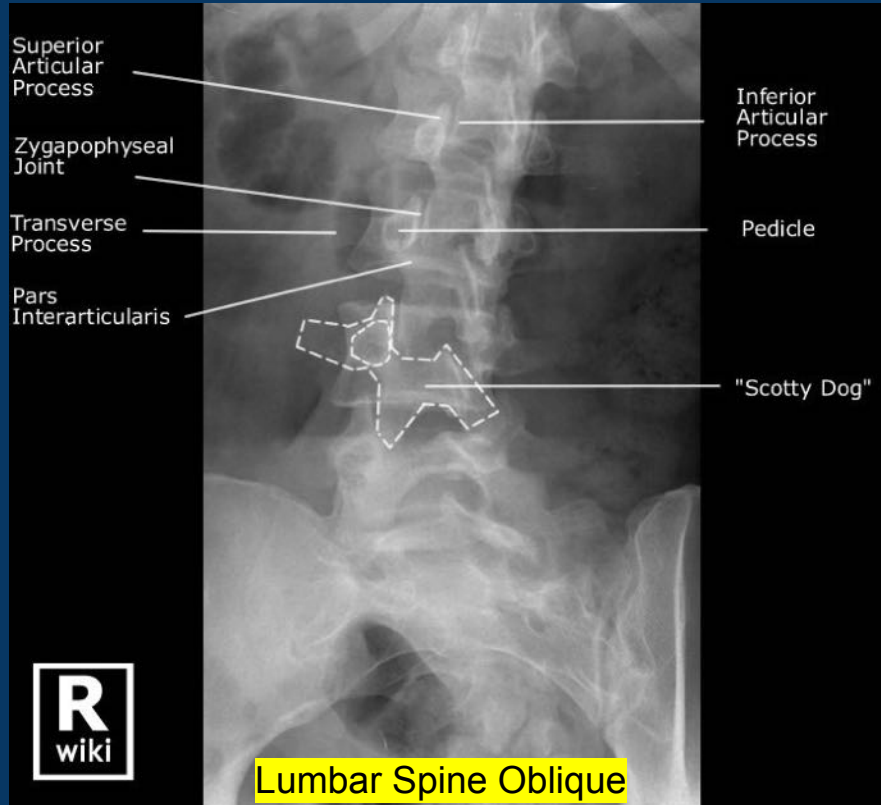
Lumbar Spine Normal XR



Lumbar Spine Flexion/ Extension Views

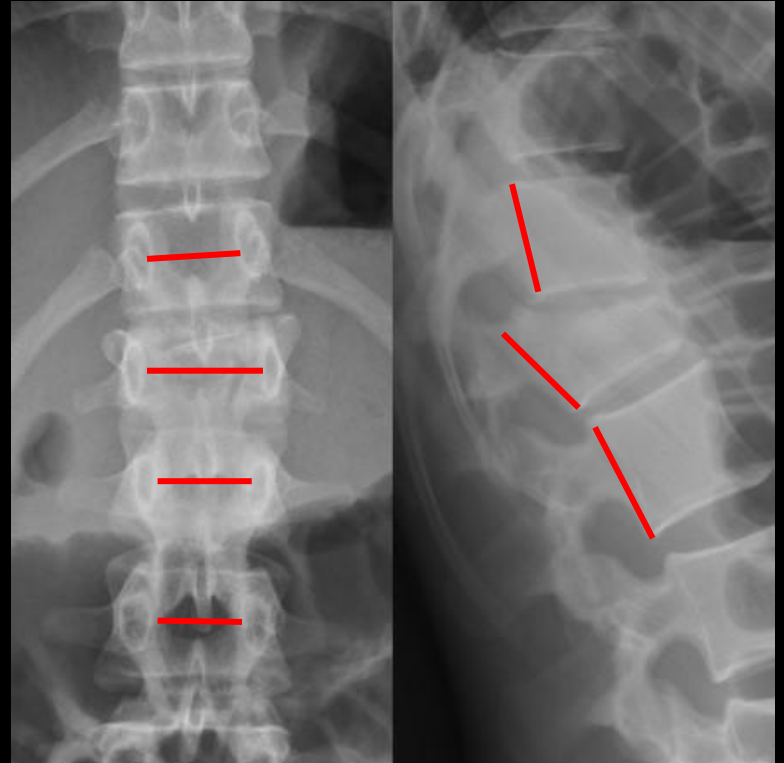


Lumbar Spine Special Views (largely replaced with CT)

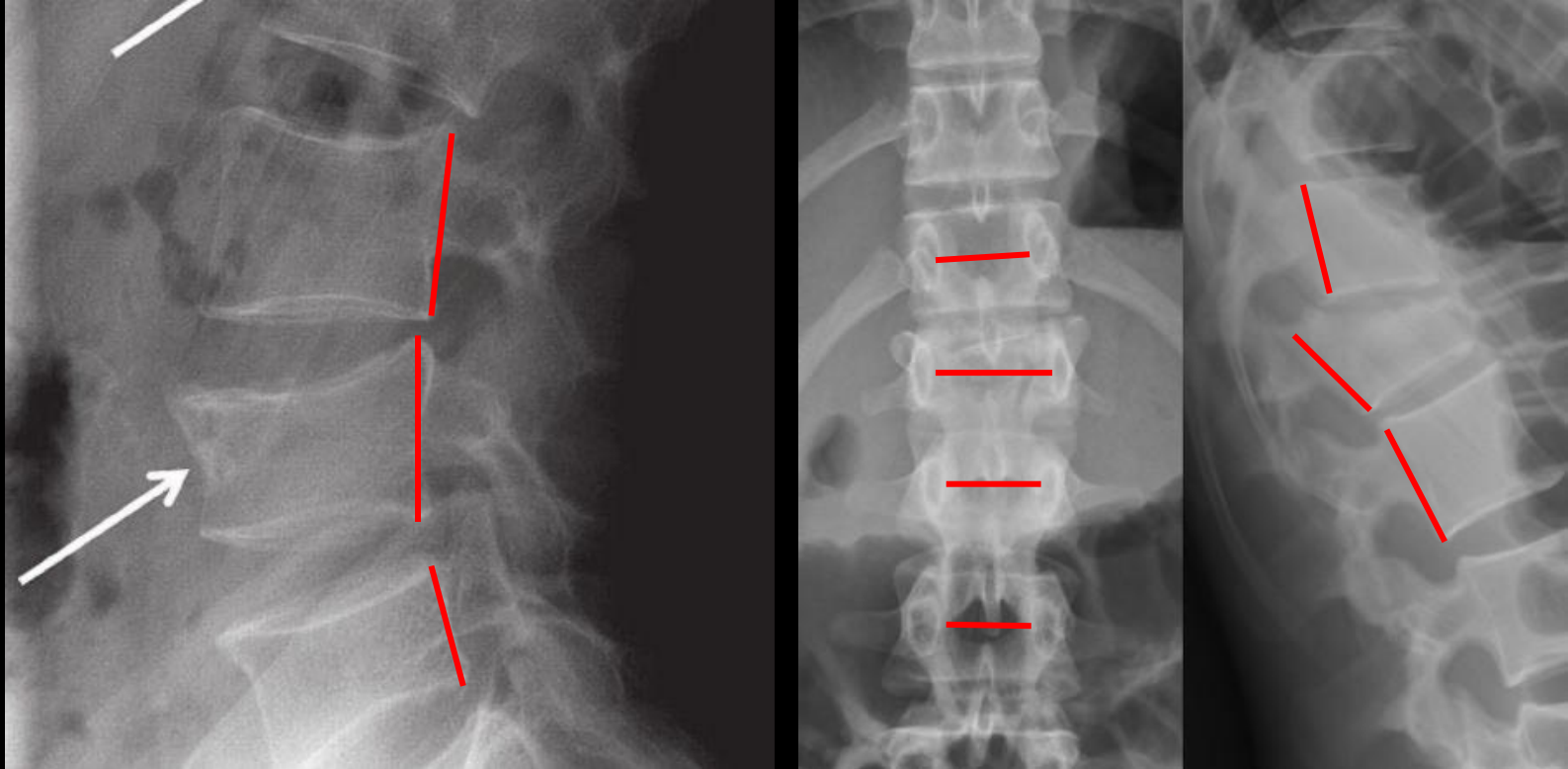


2 Must-Know Features of Burst Fractures

- Burst fractures
 - Involve 2 columns - Anterior and Middle Columns
 - 2 Keywords
 - Retropulsion on lateral view
 - Widened inter-pedicular distance on AP view
- Wedge compression fractures
 - Only anterior column involved



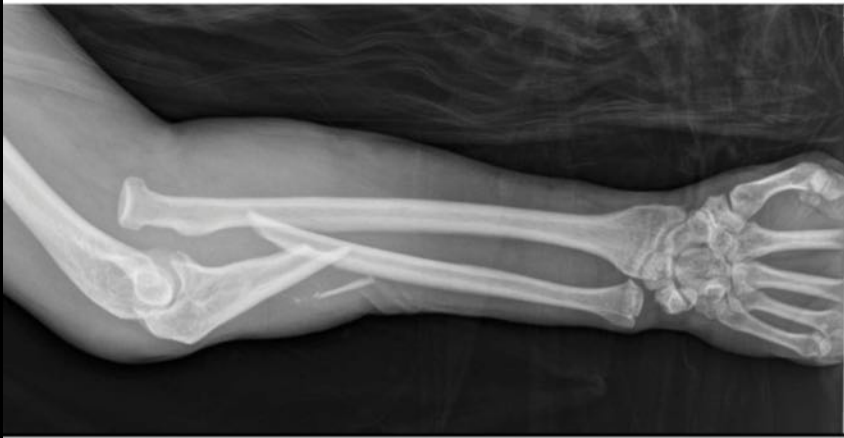Compression Fractures vs Burst Fracture





Forearm: What is the diagnosis?

Q9



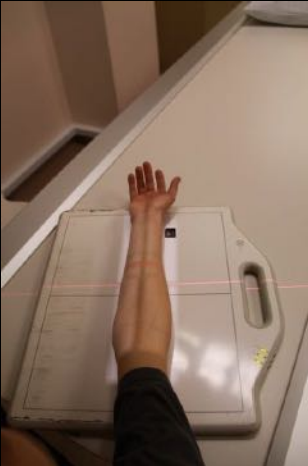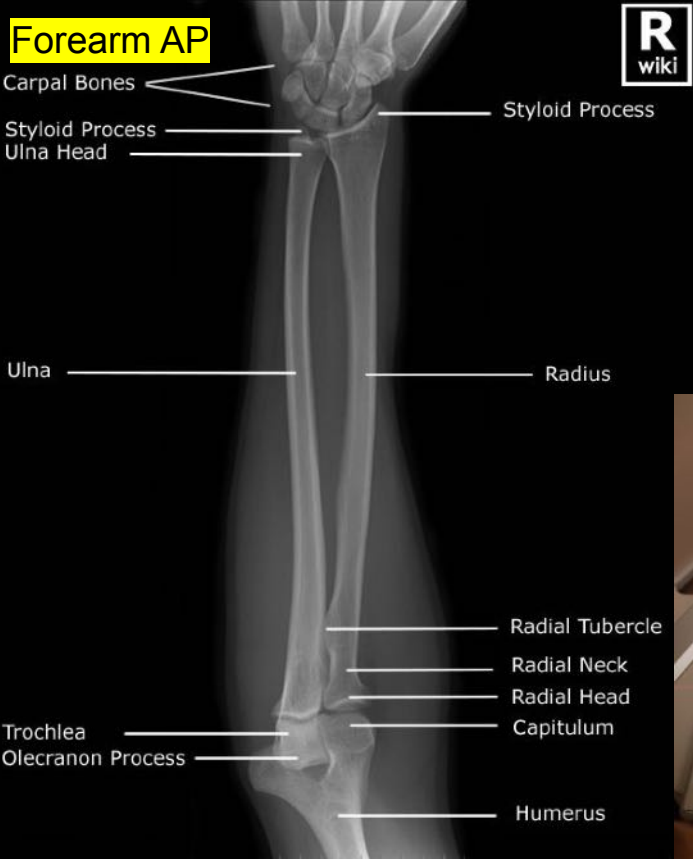🕒 18

Forearm: What is the diagnosis?

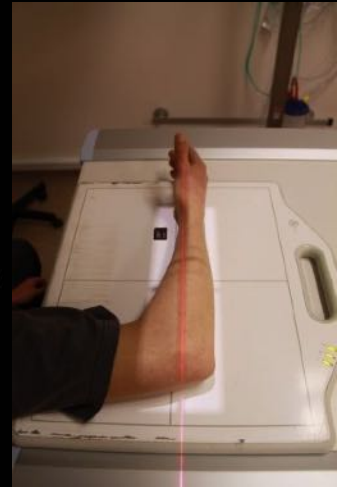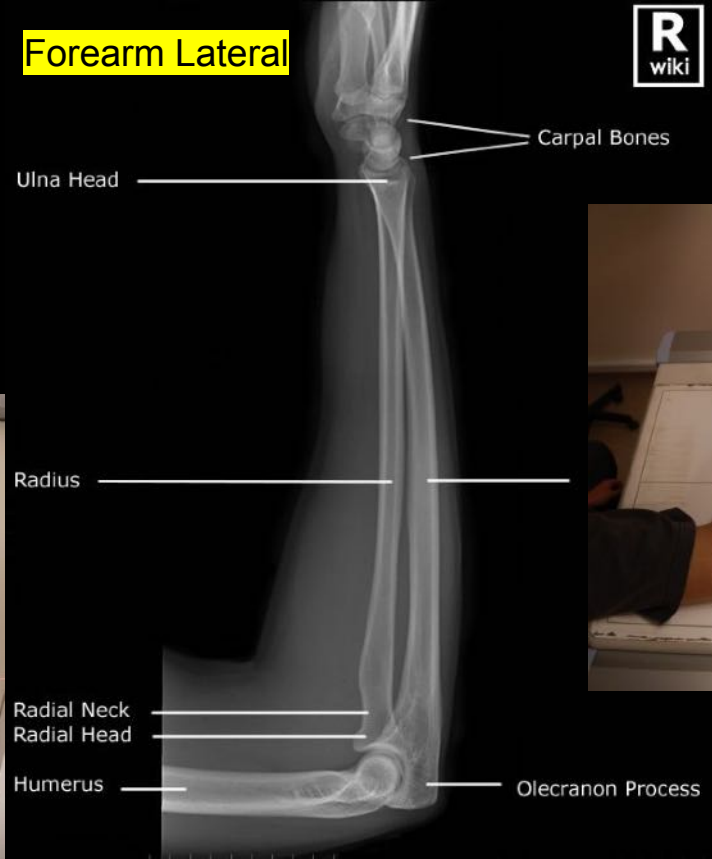- Terrible Triad
- Monteggia Fracture
- Galeazzi Fracture
- Transolecranon Fracture Dislocation
- Essex Lopresti injury

Normal Forearm XR

Forearm AP

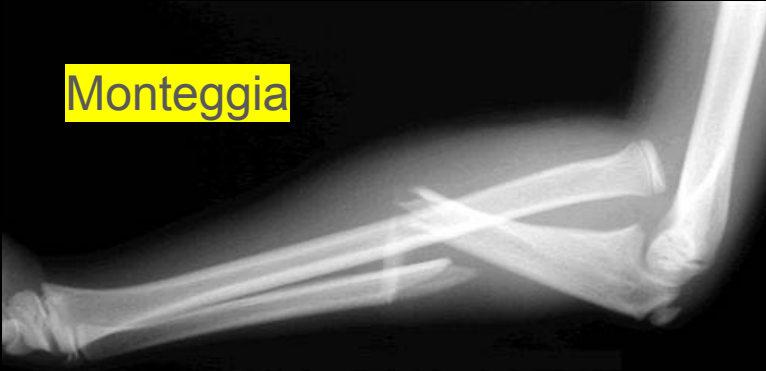

Forearm Lateral

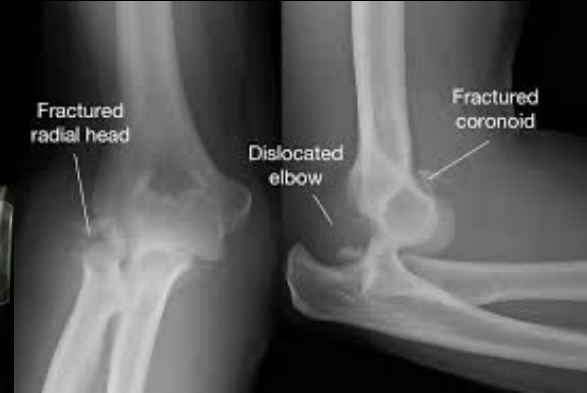
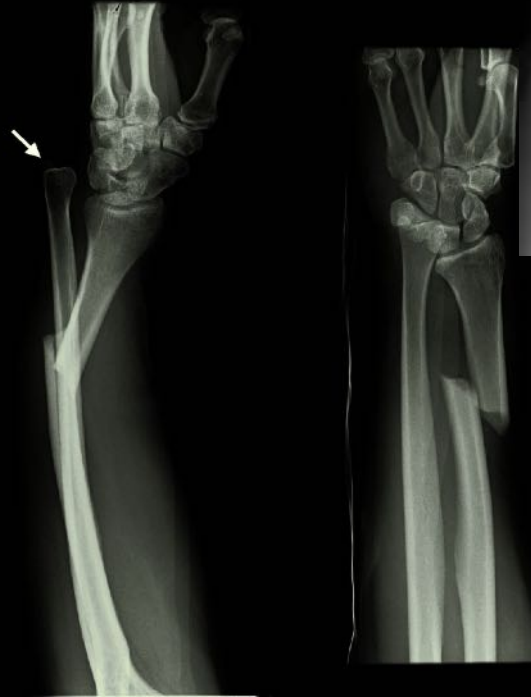
Fractures of the Forearm

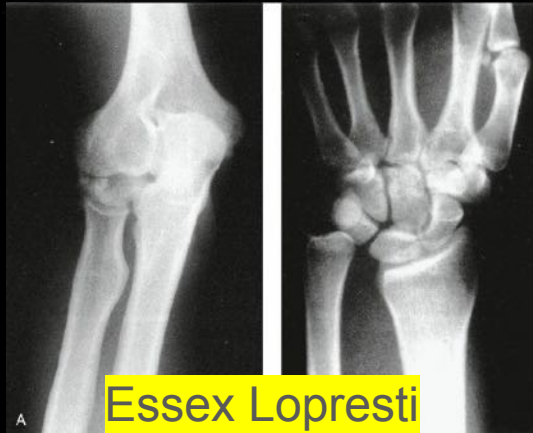Monteggia



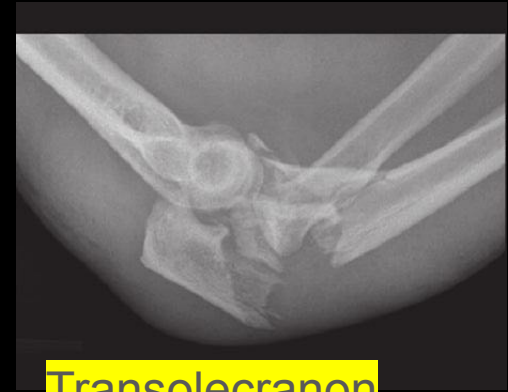Galeazzi



Terrible Triad








Essex Lopresti



Transolecranon

What we went through ; Revise the rest - Watch Video!

Region (Lines)	Orthogonal Sets	Special Views
Shoulder (<i>Moloney's Arch</i>) 	AP/ Axial	Y-Scapula, Velpeau Zanca (ACJ)
Humerus	AP/ Lateral	
Elbow (<i>Anterior Humeral, Radiocapitellar Lines</i>) 	AP/ Lateral	Greenspan (Radial head) Internal Oblique (Lateral Condyle #)
Forearm 	AP/ Lateral	
Wrist (<i>Gilula Lines, Radial Parameters</i>) 	PA/ Lateral	Scaphoid Carpal Tunnel
Hand	PA/ Lateral/ Oblique	
Finger	PA/ Lateral/ Oblique	
Pelvis (<i>Acetabular Lines</i>)	AP	Inlet/ Outlet Iliac/Obturator Oblique
Sacroiliac Joint	AP Sacrum lateral	

Region (Lines)	Orthogonal Sets	Special Views
Hip (<i>Shenton's Line</i>) 	AP/ Lateral	
Femur	AP/ Lateral	
Knee 	AP/ Lateral (Weight bearing for OA)	Skyline (PFJ) Rosenberg (Medial Joint Space) Long Leg (Mech axis)
Tibia	AP/ Lateral	
Ankle	AP/ Lateral/ Mortise	
Foot 	AP/ Lateral/ Oblique	Harris, Broden's (Calcaneum)
Toes	AP/ Lateral/ Oblique	
Cervical Spine (<i>4 Lines for alignment (Retropharyngeal Swelling 2-6-6-2)</i>) 	AP/ Lateral	Open mouth (C2) Swimmer's (C7) Flexion/ Extension
Lumbar Spine 	AP/ Lateral	Flexion/ Extension

Struggled to remember? 90min Lecture here.



OMS XR Review Course



X-ray (XR) reading can be daunting for undergraduate exams, especially if you haven't seen a fracture XR in years. Your ability to spot abnormalities in an XR depends on how familiar you are with normal XRs. It's crucial to start your final posting or exam preparation by thoroughly familiarising yourself with what's normal. This course aims to provide just that.

▶ Course Info

▶ Step 1. Download Slides

▶ Step 2. Course Video

▶ Step 3. Review Quiz

▶ Step 4. Anki Flashcards

▶ Step 5. Questions and Answers



Post Lecture Quiz

- 20 must-know Abnormal XRS

https://docs.google.com/forms/d/e/1FAIpQLScV7UAPkGUNvdMdsf3xmz2AL0qfKG2bDPn-5TQ9irEEyG8vRq/viewform?usp=sf_link

M5 SIP XR Reading Quiz



M3 Loading Week

- M3 Loading Week Lectures
 - Applied Radiology
 - Part 1: Normal XR
 - Part 2: Abnormal XR
 - Part 3: Advanced Imaging
 - Framework Approaches
 - Trauma
 - Chronic Pain
 - Infection
 - Approach to Shoulder Elbow
- Password: ***OMS2025***



OMS Foundational Series (Password Only)

- ▶ **⚠ READ FIRST ⚠** Instructions & Slides
- ▶ OMS Applied Radiology (3 Parts)
- ▶ OMS Framework Approach (2 Parts)
- ▶ OMS Approach to Shoulder and Elbow

Maximise the next few weeks!

- Revise Physical Examination skills - watch and practise on one another again and again.
- Refine your own sequence/ technique

Ortho Made Simple - Physical Examination of the Knee



1. Inspection <ul style="list-style-type: none"> Expose, on Standing <ul style="list-style-type: none"> Front - Varus/ Valgus/ Scars, Patella squint Side - Flexion deformities Back - Popliteal swelling On Walking (Gait) <ul style="list-style-type: none"> Comment on presence/ use of walking aid Type of gait e.g., varus thrust, antalgic 	2. Special Tests I <ul style="list-style-type: none"> On Sitting at edge of bed <ul style="list-style-type: none"> J-sign (individually) Creptus On lying Supine <ul style="list-style-type: none"> Temp/ Warmth Fluid bulge test (only do cross fluctuance and patellar tap if positive) Patella OA tests - Medial and lateral facet pain, Patella grind, Clark's Test (optional) Apprehension test 	3. Range of Motion <ul style="list-style-type: none"> Self Active SLR First - look at side for flexion deformity <ul style="list-style-type: none"> If not full extension, extend passively <ul style="list-style-type: none"> If still cannot extend fully = "Fixed Flexion Deformity" (FFD) If can extend fully passively = "extension lag" Check Flexion At the end of flexing knee, do Hip IR and ER, comment hip screen no pain 	4. Palpation <ul style="list-style-type: none"> Put knees back to 90 deg on couch Look from side - comment on posterior sag Sit on feet Then palpate knee systematically <ul style="list-style-type: none"> Tibial Tuberosity → Patellar tendon → Patella → Superior Pole → Medial and Lateral joint Line → Gerdy's Tubercle → Fibula Head
5. Power <ul style="list-style-type: none"> NIL 	6. Special Tests II <ul style="list-style-type: none"> Knees still bent <ul style="list-style-type: none"> Medial tibial step off Posterior Drawer Test Anterior Drawer Test Extend Leg <ul style="list-style-type: none"> Lachman at 30 deg MCL at 0 and 30 degrees LCL at 0 and 30 deg If ACL/ PCL tests positive (Postgrad) <ul style="list-style-type: none"> Recurvatum Test Turn Prone for Dial Test 	7. Neurovascular <ul style="list-style-type: none"> DP and PT pulses Ask patient to dorsiflex foot against you - "no foot drop" 	8. Complete/ Offer <ul style="list-style-type: none"> Hip examination

OMS Physical Examination

What you see here is my own synthesis of the various physical examinations for my own Exams. You will definitely see variations among surgeons. Feel free to modify and come up with your own sequence! 😊

- OMS PE Summaries Compiled
- OMS Shoulder Examination
- OMS Elbow Examination
- OMS Knee Examination
- OMS Hip Examination
- OMS Cervical Spine Examination
- OMS Lumbar Spine Examination
- OMS Hand Examination



Knee - Physical Examination Explanation

www.youtube.com

Knee - Physical Examination Run-Through

