

Systematic Review

Surgical Techniques for the Reconstruction of Medial Collateral Ligament and Posteromedial Corner Injuries of the Knee: A Systematic Review

Jeffrey M. DeLong, B.S., and Brian R. Waterman, M.D.

Purpose: To systematically review reconstruction techniques of the medial collateral ligament (MCL) and associated medial structures of the knee (e.g., posterior oblique ligament). **Methods:** A systematic review of Medline/PubMed Database (1966 to November 2013), reference list scanning and citation searches of included articles, and manual searches of high-impact journals (2000 to July 2013) and conference proceedings (2009 to July 2013) were performed to identify publications describing MCL reconstruction techniques of the knee. Exclusion criteria included (1) MCL primary repair techniques or advancement procedures, (2) lack of clear description of MCL reconstruction technique, (3) animal models, (4) nonrelevant study design, (5) and foreign language articles without available translation. **Results:** After review of 4,600 references, 25 publications with 359 of 388 patients (92.5%) were isolated for analysis, including 18 single-bundle MCL and 10 double-bundle reconstruction techniques. Only 2 techniques were classified as anatomic reconstructions, and clinical and objective outcomes ($n = 28$; 100% <3 mm side-to-side difference [SSD]) were superior to those with nonanatomic reconstruction ($n = 182$; 79.1% <3 mm SSD) and tendon transfer techniques ($n = 114$; 52.6% <3 mm SSD). **Conclusions:** This systematic review demonstrated that numerous medial reconstruction techniques have been used in the treatment of isolated and combined medial knee injuries in the existent literature. Many variations exist among reconstruction techniques and may differ by graft choices, method of fixation, number of bundles, tensioning protocol, and degree of anatomic restoration of medial and posteromedial corner knee restraints. Further studies are required to better ascertain the comparative clinical outcomes with anatomic, non-anatomic, and tendon transfer techniques for medial knee reconstruction. **Level of Evidence:** Level IV, systematic review of level IV studies and surgical techniques.

Surgical approaches to repair or reconstruction of the medial collateral ligament (MCL) and associated medial structures are typically highly invasive, have potential adverse effects associated with allograft

and autograft use, and are technically demanding. The literature supports both conservative, nonsurgical treatment and operative management, with several studies reporting mixed outcomes.¹⁻¹⁴ The robust intrinsic healing capability of the MCL is well documented, largely owing to its extracapsular location.^{7,15-17} In animal models, a transected MCL demonstrates greater potential for spontaneous healing than intra-articular cruciate ligaments.^{18,19} Similarly, one prospective randomized study of 47 consecutive patients with combined ACL and grade III MCL injuries reported no additional benefits with early, concomitant MCL repair and ACL reconstruction when compared with nonoperative MCL management.⁵ However, other studies have reported that residual laxities remained when acute anterior cruciate ligament reconstructions (ACLR) were performed concurrently with nonoperative management of grade II MCL injuries.⁶ Moreover, nonoperative, conservative treatments of combined or isolated severe (grade III) acute midsubstance MCL tears may yield worse outcomes with increased risk of

From the College of Medicine, Medical University of South Carolina (J.M.D.), Charleston, South Carolina; and the Department of Orthopaedic Surgery and Rehabilitation, William Beaumont Army Medical Center (B.R.W.), El Paso, Texas, U.S.A.

The opinions or assertions contained herein are the private views of the authors and are not to be construed as official or reflecting the views of the Department of Defense or the U.S. government. The corresponding author is an employee of the U.S. government.

The authors report that they have no conflicts of interest in the authorship and publication of this article.

Received February 4, 2015; accepted May 19, 2015.

Address correspondence to Major Brian R. Waterman, M.D., Department of Orthopaedic Surgery and Rehabilitation, William Beaumont Army Medical Center, 5005 North Piedras Street, El Paso, TX 79920-5001, U.S.A. E-mail: brian.r.waterman@gmail.com

Published by Elsevier Inc. on behalf of the Arthroscopy Association of North America

0749-8063/15104/\$36.00

<http://dx.doi.org/10.1016/j.arthro.2015.05.011>

post-traumatic osteoarthritis and other functional limitations.²⁰

Repair or reconstruction of the medial knee injuries continues to evolve and is increasingly recognized as an effective treatment to restore significant valgus and rotatory instability. Surgical intervention may be indicated with the presence of a Stener-type lesion of the distal MCL overlying the pes anserine attachment, an avulsion fracture with sizeable osseous fragment, and/or an isolated or combined grade III MCL injury that is unresponsive to conservative treatment and demonstrates excessive medial joint gapping or valgus laxity.^{21,22} Operative treatment may also be necessary to avoid associated pathologic changes that can impede healing, such as ligament contracture and scar tissue formation.²²

When nonoperative treatment fails to resolve medial knee instability, there is a risk of damaging associated ligamentous structures, primarily the ACL. It has been shown that with external tibial rotation of an MCL-deficient knee, there is a significant load increase on the ACL during anterior tibial translation.²³ Additionally, knee flexion at 45° and a valgus force applied to the MCL-deficient knee resulted in significant load increases on the ACL, potentially increasing the risk for secondary ACL injuries²³ and accelerated articular degeneration due to abnormal shear stress and loading patterns. When operative management is indicated, it has been recommended to repair or reconstruct all injured medial knee structures through the restoration of native anatomy and attachment sites.^{1,22,24,25}

Traditional surgical techniques lacking precise reattachment of the medial knee structures may not restore native anatomy and proper biomechanics.²⁶⁻²⁹ Currently, there are numerous surgical techniques that have been developed for repair or reconstruction of the superficial medial collateral ligament (sMCL), deep medial collateral ligament, and posterior oblique ligament (POL; Fig 1): primary repair, advancement, or imbrication; tendon transfers, or single- and double-bundle autograft/allograft soft tissue reconstructions with specified graft routing methods; and bone-patellar tendon-bone and Achilles bone plug inlay techniques with varying methods of fixation. Despite the abundance of operative techniques, there is still a need for less invasive surgical approaches that preserve soft tissue integrity and are more reproducible and less technically challenging than those currently available.³⁰⁻³⁴ The purpose of this study was to systematically evaluate surgical reconstruction techniques of the MCL and posteromedial corner of the knee. We hypothesized that anatomic medial knee reconstruction would result in superior measures of valgus laxity and functional patient-reported

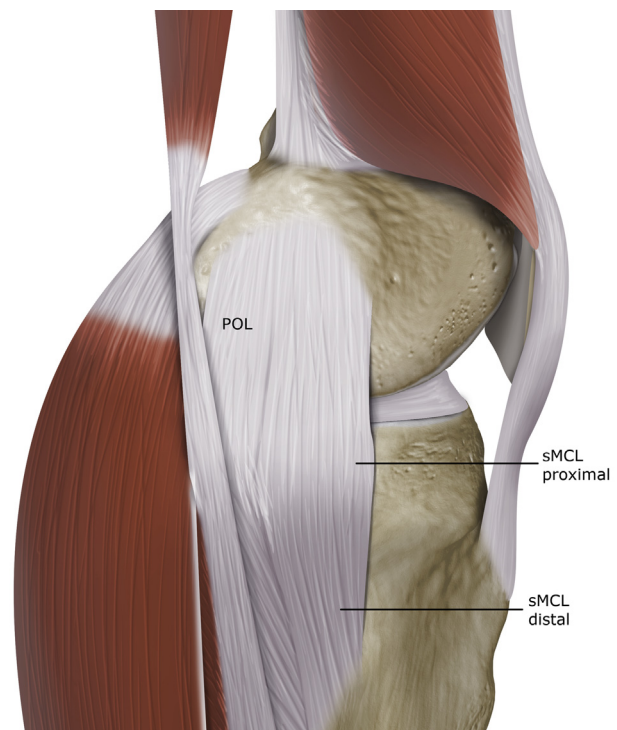


Fig 1. Native medial ligamentous anatomy of the knee. (POL, posterior oblique ligament; sMCL, superficial medial collateral ligament.)

outcomes when compared with other nonanatomic surgical techniques.

Methods

Search Strategy

A systematic review was conducted to identify all published literature describing MCL and posteromedial corner reconstruction techniques of the knee. A comprehensive literature search was performed using a computer-based search within the online Medline/PubMed Database (U.S. National Library of Medicine, National Institutes of Health) from 1966 to November 11, 2013. The electronic database algorithm search was not limited by study design or language of publication and intentionally used broad terms to maximize capture of literature. The following terms were used as keywords and medical subject headings and appeared in the title, abstract, or keyword fields: (1) medial collateral ligament knee (n = 1,613); (2) MCL knee (n = 505); (3) medial collateral ligament reconstruction knee (n = 333); (4) POL knee (n = 129); (5) POL knee (n = 615); (6) medial knee instability (n = 1,371); (7) posteromedial corner (n = 81).

Study selection for inclusion in the systematic review was determined by examining the title and/or abstract of all articles obtained from the database search. Duplicates and nonrelevant articles were excluded; foreign

language articles were assessed, and it was determined whether translation was possible. Full text was retrieved from all remaining potentially relevant abstracts.

Further studies were identified by examining reference lists of all included investigations and review articles captured by the database search. In addition, to ensure complete coverage and identification of recent publications not yet included and indexed by the electronic database, hand searches of high-impact-factor orthopaedic sports medicine journals (2000 to November 2013) and abstracts of highly attended conference proceedings (2009 to July 2013) were also performed (Appendix 1).

All authors subsequently analyzed each included study. Surgical technique was evaluated for several descriptive parameters, including reconstruction graft choice, method of femoral and tibial fixation, use of a single- (sMCL) or double-bundle technique (sMCL and POL), isometry, tensioning protocol, and overall recreation of native medial side anatomy. For the purposes of this study, a reconstruction technique was deemed anatomic if it independently recapitulated native medial-sided ligamentous anatomy, principally the sMCL and POL, and reestablished the femoral and tibial-sided footprint attachments as specified by Wijdicks et al.²² Conversely, nonanatomic techniques may encompass nonanatomic or inadequate femoral- or tibial-sided reconstruction, including single-point fixation and tendon transfer from the pes anserinus attachment.

Clinical studies were descriptively analyzed and assessed for multiple outcomes of interest: level of evidence, concomitant ligamentous procedures, duration and extent of patient follow-up, laxity on radiographic and/or manual stress valgus testing, International Knee Documentation Committee (IKDC) objective form valgus stability subscore, Lysholm scores, and other patient-reported outcome measures. To further quantify the outcomes of individual reconstruction techniques, absolute or relative medial joint space widening on valgus stress testing with the knee flexed to 20° to 30°, percentage of patients with relative medial joint space widening less than 3 mm on valgus stress, and percentage of patients with an IKDC valgus stability grade A (normal) or B (near normal) were recorded.

Eligibility Criteria

Articles were excluded based on the following criteria: (1) techniques describing only primary repair of the MCL, (2) no detailed description of MCL reconstruction technique, (3) animal models, (4) narrative reviews, (5) nonrelevant study design, (6) and foreign language articles that could not be translated. Articles were included in the systematic review if reconstruction techniques of the MCL were clearly described.

Results

Literature Selection

The online Pubmed/Medline database search produced an overall total of 4,600 publications (Fig 2). After exclusion of duplicate and nonrelevant articles, 372 abstracts were assessed for eligibility. Fourteen articles were published in Chinese medical journals and could not be further translated beyond the abstract. One article, published in a German medical journal, was translated and included in the systematic review. Full-text articles were obtained for 128 articles and were evaluated for inclusion and exclusion criteria. An additional 31 publications were identified through secondary screening measures. After applying exclusion criteria, a total of 25 unique references with 28 described medial knee reconstruction techniques were included in the final systematic review.

Surgical Technique

Surgical technique was systematically examined, and the results are shown in Table 1. Autograft use was described in 19 studies, including 15 semitendinosus, 2 indeterminate hamstring, 1 gracilis, and 1 fascia lata. Alternatively, allograft was used in 12 investigations, with 7 soft tissue grafts and 5 tendo-Achilles bone block allografts. One study documented use of a synthetic graft.³⁵ Femoral graft fixation constructs included interference screw (n = 14), spiked staple (n = 6), screw and spiked washer (n = 3), cortical button (n = 2), anchor (n = 2), bone tunnel (n = 2), and steel wire (n = 1), whereas tibial fixation included interference screw (n = 11), suture (n = 10), screw and spiked washer (n = 5), staple (n = 4), cortical button (n = 2), bone tunnel (n = 2), and anchor (n = 1). The majority of sMCL reconstructions were manually tensioned in 20° to 30° of flexion, slight varus stress, and neutral axial rotation. However, tensioning of POL reconstruction limbs was significantly more varied in terms of knee flexion, with positioning in full extension (n = 3), 30° (n = 2), 45° (n = 1), and 60° (n = 2) reported.

In total, 18 techniques were identified as single-bundle MCL reconstructions, and 10 studies describe double-bundle surgical technique with concomitant POL reconstruction. On the basis of defined criteria, only 2 studies^{1,36} were classified as anatomic medial-sided reconstructions, while 26 techniques were nonanatomic, including 8 hamstring tendon transfers (5 single-bundle, 3 double-bundle).

Clinical Outcomes

After the exclusion of surgical techniques without clinical data, 14 level IV retrospective case series were isolated for further review. A total of 359 of 388 patients (92.5%) with a mean age of 33.7 ± 4.7 were identified at an average clinical follow-up of 34.5 ± 12.4 months. Mean patient sample size at final follow-up was 25.6.

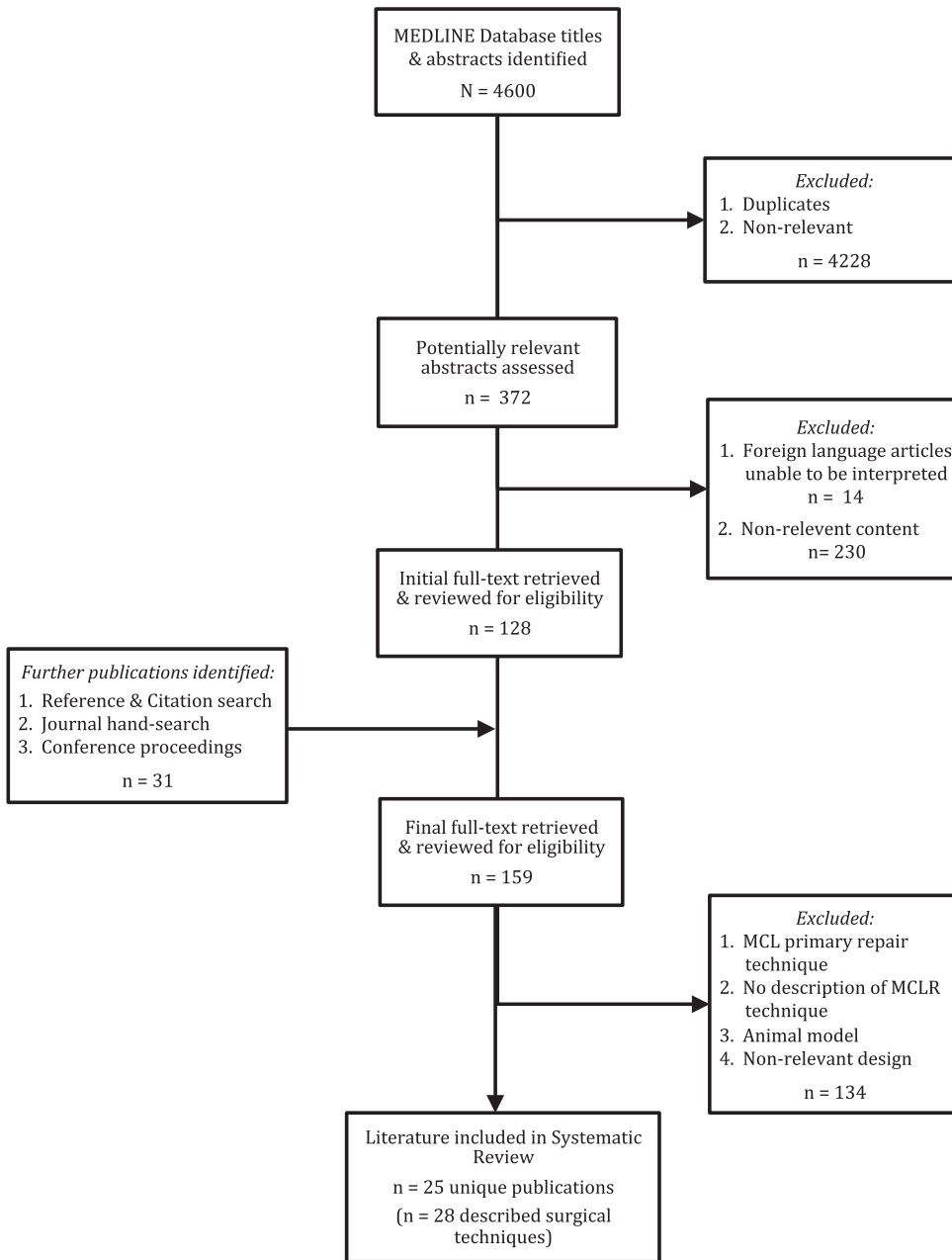


Fig 2. Literature selection process algorithm.

Owing to the heterogeneity of the patient population, varying degrees and chronicity of coexisting knee pathology, concomitant ligamentous and intra-articular surgery, and different surgical techniques, summative evaluations were limited. Three separate categories of surgical techniques were evaluated: anatomic medial knee reconstructions, nonanatomic medial knee reconstructions, and nonanatomic tendon transfer medial knee reconstructions.

Anatomic Medial Knee Reconstruction. Only 1 study met the stated criteria for anatomic medial knee

reconstruction. LaPrade et al. reported on 28 patients undergoing anatomic, hamstring, double-bundle posteromedial corner reconstruction of the MCL and POL (Fig 3) alongside cruciate or bicruciate ligament reconstruction.¹ Mean subjective IKDC score improved from 44 to 76 postoperatively, and all patients noted resolution of side-to-side instability symptoms, with none reporting recurrent laxity. Valgus stress radiographs also demonstrated improvement from 6.3 to 1.3 mm of increased medial joint space widening when compared with the contralateral side. Similarly, all patients had reported medial joint space widening less than 3 mm. The

Table 1. Medial Collateral Ligament and Posteromedial Corner Surgical Techniques

Lead Author	Year	Graft Type		Fixation Technique			Bundle		Nonanatomic Criteria	POL Recon?	Tension Protocol
		Autograft	Allograft	Femur	Tibia	SB	DB	Anatomic?			
Kitamura et al. ³⁷	2013	2ST [*]	—	CB	Staple	+	-	NA	Isolated sMCL	-	NR; maximum manual tension
Zhang et al. ⁴⁹	2013	—	AB	IFS	SW	+	-	NA	Isolated sMCL	-	sMCL: 20° flexion, neutral rotation, varus stress; POL: full extension; manual tension
LaPrade and Wijdicks ¹	2012	± ST (2)	± ST (2)	IFS	IFS, Anchor	-	+	A		+	sMCL: 20° flexion, neutral rotation, varus stress manual tension
Liu X et al. ⁷	2013	—	AB	IFS	SW	+	-	NA	Isolated sMCL	-	NR
Liu H et al. ³⁶	2012	—	TA	IFS	Suture	-	+	A		+	sMCL: 20° flexion, neutral rotation, varus stress; POL: full extension; manual tension
Dong et al. ⁵⁷	2014	—	HS/TA	IFS	Suture	-	+	NA	Single femoral tunnel, nonanatomic tibial tunnels	+	sMCL/POL: 30° flexion, neutral rotation, varus stress; manual tension
Weimann et al. ⁴²	2012	2ST	—	CB	IFS	-	+	NA	Single femoral tunnel, medial epicondyle femoral attachment	+	sMCL: full extension; POL: 45° flexion; manual tension
Koga et al. ¹⁰	2012	2ST	—	Anchor, staple	Suture	+	-	NA	Single femoral tunnel	-	sMCL: 30° flexion; maximum manual tension
Preiss et al. ³⁹	2012	2ST	—	IFS	IFS	-	+	NA	Single femoral tunnel	+	sMCL: 30° flexion; POL: full extension; manual tension
Marx and Hetsroni ¹¹	2012	—	AB	IFS	SW	+	-	NA	Isolated sMCL	-	sMCL: 20° flexion, varus stress; manual tension
Stannard ⁵⁸	2010	± ST	± ST	SW	Suture	-	+	NA/TT	Single femoral attachment, nonanatomic tibial attachment	+	sMCL: 30-40° flexion, varus stress; manual tension
Lind et al. ¹³	2009	ST	—	IFS	IFS	-	+	NA/TT	Pes attachment, single femoral tunnel	+	sMCL: 10° flexion, neutral rotation; POL: 60° flexion, neutral rotation; manual tension
Feeley et al. ⁴³	2009	ST	—	Staple	IFS	+	-	NA	Proximal sMCL reconstruction only	-	sMCL: 30° flexion; 44 N tension
Bosworth		ST	—	Staple	—	+	-	NA/TT	Nonanatomic tibial attachment	-	sMCL: NR; 44 N tension
Modified Bosworth		ST	—	Staple	IFS	+	-	NA/TT	Nonanatomic tibial attachment	-	sMCL: 30° flexion; 44 N tension
DSB		2ST	—	Staple	IFS	+	-	NA	Isolated sMCL	-	sMCL: 30° flexion; 44 N tension
Kim et al. ²⁷	2008	ST	—	SW	Suture	-	+	NA/TT	Nonanatomic single femoral attachment, nonanatomic tibial attachment	+	sMCL: 30° flexion, varus stress; POL: 30° flexion; manual tension
Ibrahim et al. ³⁵	2008	—	†	BT	BT, Suture, Staple	+	-	NA	Nonanatomic femoral attachment	-	sMCL: 90° flexion
Wahl and Nicandri ⁵⁰	2008	—	AB	IFS	IFS	+	-	NA	Nonanatomic single femoral attachment, non-anatomic tibial attachment	-	sMCL: 30-45° flexion; manual tension
Rue et al. ⁴⁸	2007	—	AB	IFS	Staple, SW	+	-	NA	Isolated sMCL	-	sMCL: 30° flexion, varus stress; manual tension

(continued)

Table 1. Continued

Lead Author	Year	Graft Type		Fixation Technique		Bundle			Nonanatomic Criteria	POL Recon?	Tension Protocol
		Autograft	Allograft	Femur	Tibia	SB	DB	Anatomic?			
Adachi et al. ⁵⁶	2006	2HS	—	Bone plug, [‡] staple	Suture	+	-	NA/TT	Nonanatomic tibial attachment	-	sMCL: NR; 50 N tensiometer
Yoshiya et al. ¹⁴	2005	3HS/4HS	—	IFS	IFS, CB	+	-	NA	Nonanatomic femoral attachment	-	sMCL: 30° flexion, varus stress; manual tension
Azar ⁵⁹	2006	± ST	± 2ST/2 TA/AB	IFS	Suture/ staple/IFS	-	+	NA	Nonanatomic single femoral attachment, non-anatomic tibial attachment	+	NR
Gorin et al. ⁴⁵	2003	G	—	Anchor	Suture	+	-	NA/TT	Nonanatomic single femoral attachment, non-anatomic tibial attachment	-	sMCL: 30° flexion
Fanelli and Edson ³⁸	2002	± 2ST	± HS/TA/A	IFS/SW	IFS/SW	+	-	NA	Isolated sMCL	-	sMCL: 30° flexion, varus stress; NR
Borden et al. ⁴⁴	2002	—	TA	IFS	IFS (2)	-	+	NA	Nonanatomic femoral attachment	+	sMCL: 30° flexion, internal rotation; POL: 60° flexion, internal rotation; manual tension
Fenton ⁶⁰	1957	ST	—	Steel wire, bone flap	—	+	-	NA/TT	Nonanatomic single femoral attachment, nonanatomic tibial attachment	-	NR
Umansky ⁶¹	1952	TFL	—	BT, suture	BT, suture	+	-	NA	Isolated sMCL	-	sMCL: varus stress; manual tension

NOTE. The plus/minus (±) sign indicates optional use. The slash mark (/) denotes interchangeable graft use.

2ST, double-looped semitendinosus; 2TA, double-looped tibialis anterior; 3HS/4HS, triple- or quadruple-looped hamstring tendon; A, Achilles soft tissue; AB, Achilles bone block; ASB, anatomic single bundle; BT, bone tunnel; CB, cortical button; DSB, doubled single bundle; G, gracilis; HS, hamstring tendon; IFS, interference screw; LARS, Ligament Advanced Reinforcement System; NA, nonanatomic reconstruction technique; NA/TT, nonanatomic tendon transfer technique from the pes anserinus; NR, not reported; POL, posterior oblique ligament; SB, single bundle; sMCL, superficial medial collateral ligament; ST, semitendinosus; ST (2), 2 semitendinosus grafts; SW, cortical or cancellous screw with spiked washer; TA, tibialis anterior; TFL, tensor fascia lata.

*Augmented with polyester tape.

†Indicates LARS artificial graft.

‡Indicates use of press-fit, autogenous bone plug fixation.

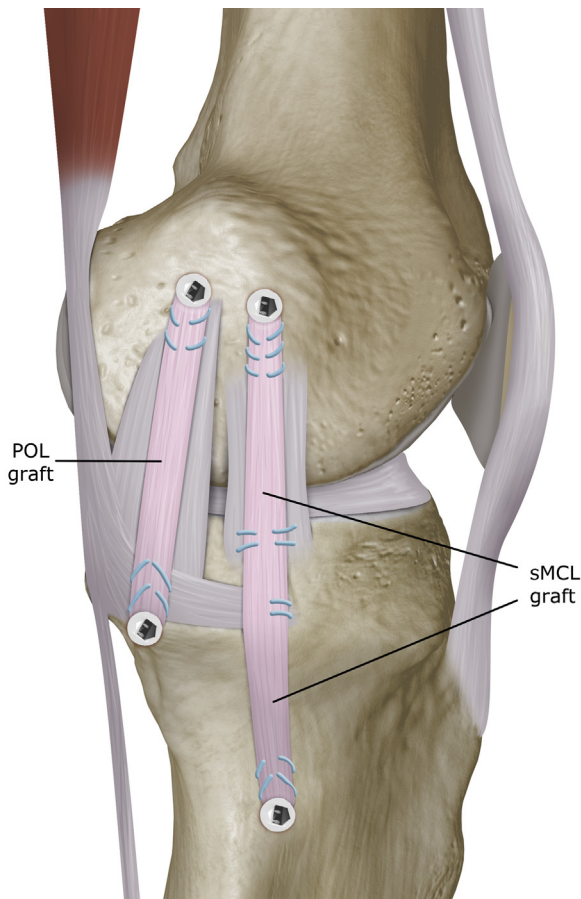


Fig 3. Anatomic double-bundle posteromedial corner reconstruction. (POL, posterior oblique ligament; sMCL, superficial medial collateral ligament.)

investigators concluded that a more anatomic technique effectively restores valgus stability and knee function at short-term follow-up.

Nonanatomic Medial Knee Reconstruction. Nonanatomic medial knee reconstructions were performed in 237 patients across 10 studies, including both single- and double-bundle techniques (Figs 4 and 5). Of those reporting medial joint space widening, the cumulative average of patients with a nonanatomic medial knee reconstruction and less than 3 mm on valgus stress was 79.1% (144 of 182 patients). Kitamura et al. revealed no difference in absolute mean medial joint opening between the operative knee and the intact knee after single-bundle sMCL reconstruction, and 86.7% of patients has a valgus opening of less than 3 mm versus the contralateral knee.³⁷ Koga et al. performed concomitant MCL and POL repair with single-bundle sMCL reconstruction in 18 patients, resulting in an average of 1 mm relative medial opening on radiographic studies and only 1 patient with widening up to 3 mm.¹⁰ Marx and Hetsroni showed similar success with single-bundle Achilles allograft reconstruction of the sMCL; all 14 patients in

this series had firm endpoints on manual valgus stress, with only 3 patients having grade 1+.¹¹ Similarly, Yoshiya et al. showed excellent results in 24 patients with a mean stress widening of 0.2 ± 0.5 mm after triple- or quadruple-looped hamstring sMCL reconstruction with a nonanatomic medial epicondylar tunnel.¹⁴ These results were also reproduced by Fanelli and Edson in their single-bundle sMCL reconstruction of 7 patients with equivalent side-to-side tension on manual stress testing.³⁸ Ibrahim and coauthors revealed slightly greater laxity in 5 of 15 patients with grade 1+ laxity on manual examination after sMCL reconstruction with a nonanatomic femoral attachment.³⁵

Using a double-bundle technique with a single femoral tunnel, Liu et al. reported a relative increase of 1.1 mm medial widening compared with normal, with 14 of 16 patients having less than 3 mm on radiographic stress views.⁷ In a similar technique, Dong et al. revealed a slightly greater mean of 2.9 ± 1.2 mm on valgus stress testing among 56 patients, and 9.4% of patients had detectable anteromedial rotatory instability on Slocum test postoperatively.⁸ In a small series of 9 patients, Preiss et al. showed that all patients were stable on manual valgus stress after a double-bundle technique with a single femoral point of fixation.³⁹

Nonanatomic Tendon Transfer Medial Knee Reconstruction.

Three studies used a nonanatomic medial knee reconstruction technique with hamstring tendon transfer (Fig 6) in a total of 142 patients. In 2 studies with available data, only 52.6% of patients (60 of 114 patients) had medial joint spacing widening less than 3 mm on valgus stress testing. Kim et al. reported excellent results with their double-bundle technique, with an overall average of 1.1 mm and 22 of 24 patients demonstrating a side-to-side difference of less than 3 mm radiographic stress images.²⁷ Stannard and colleagues also reported excellent comparative results using his double-bundle technique with graft passage around the distal semimembranosus tendon. In this study, they showed a 4% failure rate after medial reconstruction (46 of 48 patients), with 2 patients experiencing 2+ or greater valgus laxity or instability on anteromedial rotatory drawer test.⁴⁰ Lastly, Lind et al. revealed greater laxity among their cohort after double-bundle reconstruction; only 25 of 50 patients had radiographic side-to-side valgus widening less than 3 mm, although 98% had normal or near normal grade on the IKDC valgus stability subscore.¹³

Discussion

Numerous surgical techniques have been performed among a diverse range of patients with concurrent knee injuries, making it difficult to correlate technique validity and outcome success (Tables 2 and 3). Key

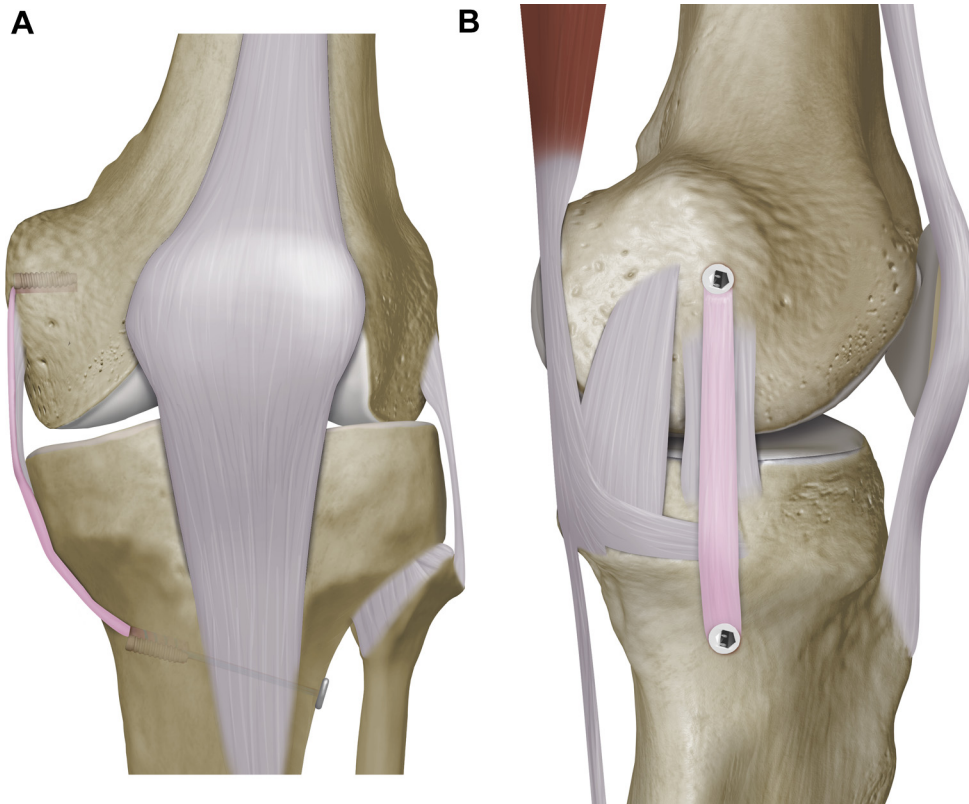


Fig 4. Single-bundle medial collateral ligament reconstruction.

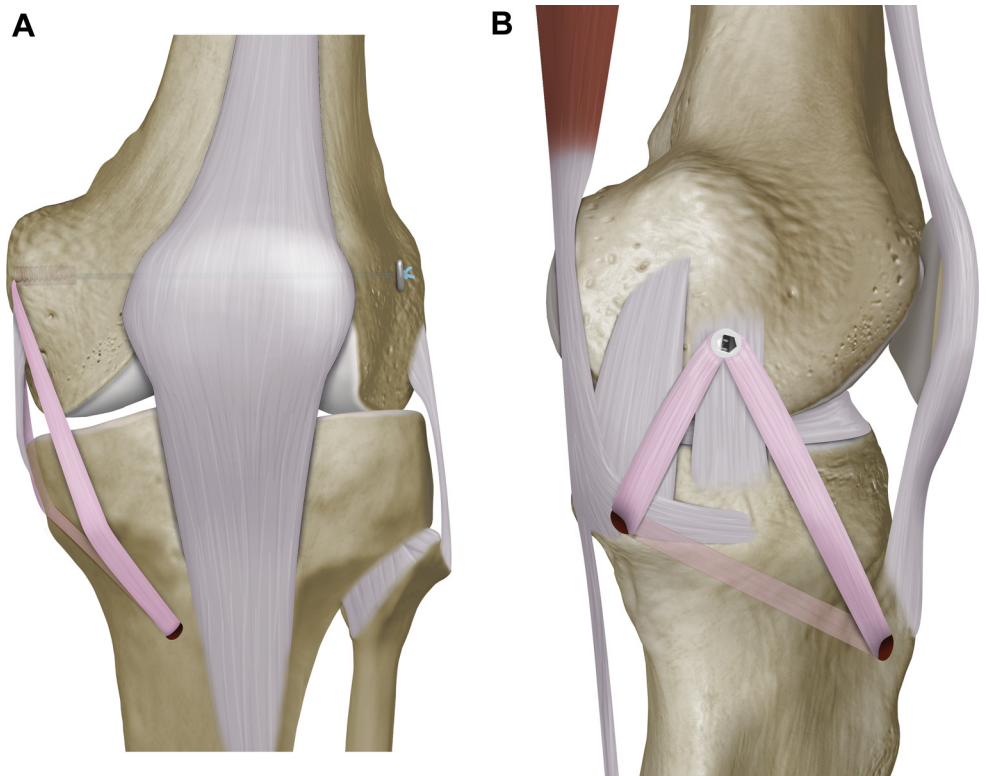


Fig 5. Nonanatomic double bundle posteromedial corner reconstruction.

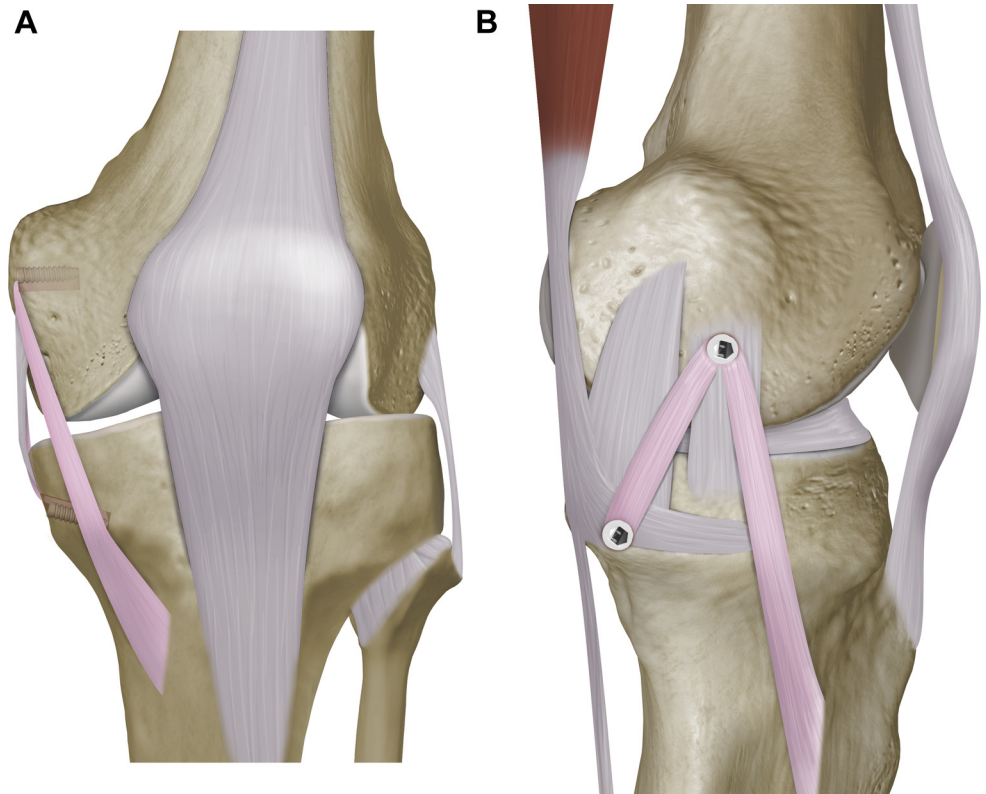


Fig 6. Nonanatomic tendon transfer.

findings are indicated in Table 4. These various techniques attempt to use various types of grafts and fixation methods. Allografts have the potential risk for complications such as infection and irradiation-associated biomechanical degradation, require additional surgical costs, and are not available in some countries.¹¹ Autograft harvest may further local tissue damage, risk donor site morbidity, and potentially weaken dynamic medial stabilizers when using semitendinosus and/or gracilis tendons.⁴¹ In addition, autologous tissue may have questionable tissue quality after acute knee dislocation. The use of double-bundle graft constructs^{8,42,36,39,43-45} increases technical complexity, often resulting in multiple bone tunnels and different points of fixation with additional hardware, which may add bulk to the final construct.¹¹

Triple and quadruple bundle semitendinosus/gracilis autografts involving various looping techniques, figure-of-8, or triangular routing configurations have also been described.^{8,14,45} Attempts to replicate the native sMCL anatomy have led to the use of grafts tunneled through the tibia in a triangular vector pattern.^{8,46} This innovative technique may also variably contribute stability through the recreation of the oblique fibers of the central arm of the POL and middle portion of the sMCL. However, chronic localized inflammation at the tibial bone-graft interface may result from graft excursion and repetitive shear stress without interference screw

fixation.⁸ Risk also lies in over-tensioning the central arm of the POL during graft tunneling, which can retract the posteromedial horn of the meniscus and negatively affect medial knee stability during flexion.⁴⁷ Similarly, knee stiffness remains the most common complication after reconstruction of the MCL⁴⁵ and may arise from aggressive anterior mobilization of the posteromedial joint capsule into the graft tissue.²²

Tendon transfer procedures of the semitendinosus obviate the need for allograft tissue and an additional bone tunnel and fixation site for the sMCL on the distal tibia. However, maintenance of the existing distal semitendinosus insertion results in an excessively anterior tibial position for the reconstructed sMCL. Furthermore, LaPrade et al. reported failure of all MCL grafts during pilot biomechanical testing where distal tibial reconstruction tunnels were placed slightly anterior to the pes anserinus vis-à-vis a more posterior anatomic attachment.¹

Techniques using quadriceps tendons,¹⁰ bone-patella-tendon-bone,¹⁰ and Achilles bone block allograft have been widely described, with the bone block fixation in the femur^{7,11,48} and tibia.^{49,50} While the Achilles does offer early osseous healing, a broad ligament reconstruction for recreation of the anterior and posterior aspects of the sMCL, and a potentially less-invasive 2-incision technique, it is not a comprehensive anatomic reconstruction because it does not fully restore

Table 2. Medial Collateral Ligament and Posteromedial Corner Surgical Outcomes

Author	Year	Level of Evidence	Technique	Mean Age	Age Range	Number of Patients (%)	Average Follow-up (Range)	Concomitant Ligamentous Procedures (N)	Valgus Laxity	Mean Side-to-Side Difference in Medial Joint Space Opening	Relative Valgus Stress Opening <3 mm or <1+	Outcome Measures	IKDC Valgus Stability A/B (%)	Lysholm Score
Kitamura et al. ³⁷	2013	IV	ASB	29	16-60	30/37 (81)	NR (24-151 mo)	ACLR (20), PLCR (6), ACLR/PLCR (11)	Radiographic	+0.5 ± 0.4 mm (range, -2 to 5)	26/30 (86.7%)	IKDC, Lysholm	30/30 (100)	94.8 ± 4.8 (85-100)
LaPrade and Wijdicks ¹	2012	IV	ADB	32	16-56	28/28 (100)	18 mo (6-36)	ACLR (8), PLCL (9), ACL/PCL (9)	Radiographic	+1.3 mm (range, -1.0 to 2)	28/28 (100%)	IKDC	NR	NR
Liu X et al. ⁷	2013	IV	NASB	37	19-53	16/19 (84)	34 mo (24-67)	PLCR (12), ACLR (5), PLCL (4), PF (3)	Radiographic	+1.1 mm (range, -1.1 to 3.2)	14/16 (87.5%)	IKDC, Lysholm	16/16 (100)	88.6 ± 5.0 (75-95)
Dong et al. ⁵⁷	2014	IV	NADB	36	18-60	56/56 (100)	33 mo (15-47)	ACLR (29)	Radiographic; slocum test	+2.9 ± 1.2 mm	33/56 (58.9%)	IKDC	53/56 (94.6)	NR
Koga et al. ¹⁰	2012	IV	ASB	24	17-44	18/18 (100)	26 mo (24-75)	ACLR (14), PLCL (1), ACLR/PLCL (3)	Radiographic	+1 mm (range, 0-3)	17/18 (94.4%)	Lysholm, VAS	NR	91 (70-100)
Preiss et al. ³⁹	2012	IV	NADB	39	18-70	9/9 (100)	16 mo (11-56)	ACL (3), ACL/PCL (3), ACL/PCL/PLC (1)	Manual stress	NR (range, 0-1+)	9/9 (100%)	lysholm, tegner	NR	90 (72-96)
Marx and Hetsroni ¹¹	2012	IV	ASB	34	19-60	14/14 (100)	36 mo (24-61)	ACLR (7), RACLR (5), PLCL (1), ACLR/PLCL/PLCL (1)	Manual stress	NR (range, 0-1+)	11/14 (78.6%)	IKDC, Lysholm, KOOS, Tegner, Marx	NR	NR
Stannard ⁵⁸	2012	IV	NATTDB	36	NR	48/48 (100)	43 mo (24-86)	ACLR/PCRL (4), ACLR/PLCL/PLCL (35), ACLR/PLCL/PLCL/ORIF (7)	Manual stress	NR	13/40 (32.5%)	IKDC, Lysholm, SF-36	33/40 (82.5)	87 (NR)
Lind et al. ¹³	2009	IV	NATTDB	34	14-61	50/61 (82)	40 mo (26-68)	ACLR (34), ACLR/PLCL (4), ACLR/PLCL (4), ACLR/PLCL/PLCL (2), PLCL (1), PLCL/PLCL (1), PLCL (1)	Manual stress	NR	25/50 (50%)	IKDC, KOOS	49/50 (98)	NR
Kim et al. ²⁷	2008	IV	NATTDB	36.00	17-54	24/24 (100)	53 mo (25-92)	ACLR (12), PLCL (6)	Radiographic	+1.1 mm (range, 0-5)	22/24 (92%)	IKDC, Lysholm	NR	91.9 (80-100)
Ibrahim et al. ³⁵	2008	IV	NASB	27	17-45	15/15 (100)	53 mo (36-96)	ACL/PCL (15)	Manual stress	NR	10/15 (67%)	NR	15/15 (100)	91 ± 4 (78-100)
Yoshiya et al. ¹⁴	2005	IV	NASB	28	16-54	24/24 (100)	27 mo (24-48)	ACLR (14), PLCL (8)	Radiographic	+0.2 ± 0.5 mm (range, -1 to 2)	24/24 (100%)	IKDC	NR	NR
Fanelli and Edson ³⁸	2002	IV	ASB	NR	NR	7/7 (100)	NR (24 - 120 mo)	ACL/PCL (7)	Manual stress	"Equivalent" v normal	NR	Tegner, Lysholm, HSS	NR	NR
Fenton ⁶⁰	1957	IV	NATTSB	NR	NR	20/28 (71)	NR (NR)	NR	NR	NR	NR	subjective rating	NR	NR

ASB, anatomic single bundle; ACLR, anterior cruciate ligament reconstruction; ADB, anatomic double bundle; HSS, Hospital for Special Surgery knee score; IKDC, International Knee Documentation Committee; KOOS, knee injury and osteoarthritis outcome score; mo, months; NASB, nonanatomic single bundle; NADB, nonanatomic double bundle; NATTDB, nonanatomic tendon transfer double bundle; NATTSB, nonanatomic tendon transfer single bundle; NR, not reported; ORIF, open reduction internal fixation; PCL, posterior cruciate ligament; PLCL, posterior cruciate ligament reconstruction; PF, patellofemoral; PLCL, posterolateral corner reconstruction; PLC, posterolateral corner; RACLR, revision ACLR; SF-36, Short Form-36; VAS, visual analog scale.

Table 3. Medial Collateral Ligament and Posteromedial Corner Surgical Outcomes by Surgical Technique

Surgical Technique	Number of Patients (%)	Graft Type	Concomitant Ligamentous Procedures (n)	Outcome Measures	Valgus Laxity	Mean Side-to-Side Difference in Medial Joint Space Opening	Relative Valgus Stress Opening <3 mm or <1+ (%)	IKDC Valgus Stability A/B (%)
Anatomic double bundle	28/28 (100)	ST (2) Allograft/Autograft	ACL (8), PCL (9), ACL/PCL (9)	IKDC, Lysholm	Radiographic	+1.3 mm (range, -1.0 to 2)	28/28 (100)	28/28 (100)
Anatomic single bundle	69/76 (91)	AB, Soft Tissue autograft/Allograft	ACL (41), ACLR/PCLR (21) PLCR (6), Revision ACL (5), PCLR (2), ACLR/PCLR/PLCR (1)	IKDC, Lysholm, KOOS, Tegner, Marx, HSS	Radiographic, manual stress	0.5-1 mm (range, -2 to 5)	54/62 (87)	30/30 (100)
Nonanatomic double bundle	65/65 (100)	Soft Tissue Autograft/Allograft	ACL (31), ACLR/PCLR (3), ACLR/PCLR/PLCR (1)	IKDC, Lysholm, Tegner	Radiographic, manual stress	2.9 mm (range, NR)	42/65 (65)	53/53 (100)
Nonanatomic single bundle	55/58 (95)	LARS, AB, 3HS/4HS autograft	ACL (12), PLCR (12), ACLR (14), ACLR (5), PF (3)	IKDC, Lysholm	Radiographic, manual stress	0.2-1.1 (range, -1 to 3.2)	48/55 (87)	31/31 (100)
Nonanatomic tendon transfer	122/133 (92)	Pes anserinus transfer	ACL (46), ACLR/PCLR/PLCR (37), ACLR/PCLR (8), ACLR/PCLR/PLCR/ORIF (7), PCLR (7), ACLR/PLCR (4), PCLR/PLCR (1), PLCR (1)	IKDC, Lysholm, KOOS, SF-36	Radiographic, manual stress	1.1 Mm (range, 0-5)	60/122 (49)	82/98 (84)

3HS, triple looped hamstring tendon; 4HS, quadruple looped hamstring tendon; AB, Achilles bone block; HSS, Hospital for Special Surgery knee score; IKDC, International Knee Documentation Committee; KOOS, knee injury and osteoarthritis outcome score; LARS, Ligament Advanced Reinforcement System; mo, months; NR, not reported; ORIF, open reduction internal fixation; PCL, posterior cruciate ligament; PCLR, posterior cruciate ligament reconstruction; PF, patellofemoral; PLC, posterolateral corner; PLCR, posterolateral corner reconstruction; SF-36, Short Form 36; ST (2), 2 semitendinosus grafts.

Table 4. Key Findings

Anatomy	<p>The adductor magnus tendon is useful landmark for identifying relevant femoral osteology (adductor tubercle, gastrocnemius tubercle, medial epicondyle) and locating native anatomic attachments of the medial ligamentous complex.</p> <p>The sMCL originates at an average 3.2 mm proximal and 4.8 mm posterior to the epicondyle and inserts at 2 separate proximal and distal attachments on the posterior third of the tibia (1.2 cm and 6 cm distal to the joint line, respectively).</p> <p>The POL attaches at an average 1.4 mm distal and 2.9 mm anterior to the gastrocnemius tubercle on the femur, and its central arm contributes most significantly to the stability of the posteromedial corner with its broad, fan-shaped insertion onto the semimembranosus tendon, capsular tissue, and sMCL.</p>
Epidemiology and Study Design	<p>Isolated medial and posteromedial corner reconstruction is rare given its robust healing environment and frequent association with other concomitant ligamentous knee injuries.</p> <p>Given the clinical heterogeneity and variable outcome measures, retrospective comparative analysis of clinical outcomes after surgical management may be limited by significant confounding and sources of bias.</p>
Surgical Technique	<p>A variety of graft choices (e.g., hamstring autograft, soft tissue allograft, Achilles bone block allografts) and methods of fixation have been used without superior clinical results.</p> <p>The majority of sMCL reconstructions were manually tensioned at 20°-30° of flexion with slight varus stress and neutral rotation. Conversely, there is no consensus on the optimal position for fixing the POL graft, with tension at either 0° or varying degrees of flexion.</p> <p>Single-bundle MCL reconstructions were most commonly described, and the majority of surgical techniques were deemed nonanatomic owing to nonanatomic or inadequate femoral- or tibial-sided reconstruction.</p>
Clinical Outcomes	<p>Of patients undergoing anatomic double-bundle reconstruction (e.g., MCL and POL), all knees (n = 28; 100%) had less than 3 mm of relative SSD in medial joint space opening with valgus stress (average +1.3 mm).</p> <p>Anatomic single-bundle reconstruction (n = 237; 87% SSD <3 mm), nonanatomic single-bundle reconstruction (n = 65; 87%), nonanatomic double-bundle reconstruction (n = 55; 65%), and pes anserine tendon transfers (n = 122; 49%) demonstrated greater laxity on manual or radiographic stress testing.</p>
Conclusions	<p>Anatomic medial and posteromedial corner reconstruction should be emphasized during the surgical treatment of complex ligamentous knee injuries to restore native valgus and rotatory stability.</p>

MCL, medial collateral ligament; POL, posterior oblique ligament; sMCL, superficial medial collateral ligament; SSD, side-to-side difference.

ligamentous restraints on the posteromedial corner, including the POL. Furthermore, despite its broad tissue attachment, it does allow for independent tensioning for more consistent valgus and rotational stability throughout the knee range of motion.

Among the current techniques, independent anatomic reconstruction of both the sMCL and POL to their precise, respective native attachment sites is infrequent. While some techniques claim to restore both the sMCL and POL to their respective anatomic footprint, inaccurate placement is particularly common at the femur. In the current review, a single femoral fixation site is used for attachment of different divisions of the sMCL and POL in the majority of reconstructions. Furthermore, outdated literature may propagate this nonanatomic surgical technique in medial knee reconstruction, including sources that errantly identify the medial epicondyle as the proximal sMCL attachment⁵¹⁻⁵³ and techniques that use it for femoral fixation or assessments of isometry.^{8,42,27,35,50,44,14} More contemporary anatomic and radiographic studies have more accurately characterized femoral-sided medial structures, which specifically indicate that the correct proximal femoral attachment of the sMCL is 3.2 mm proximal and 4.8 mm posterior to the medial epicondyle.^{28,29} Alternatively, other investigators have recommended the use of radiographic landmarks in isometric, femoral tunnel placement, referencing the

anterior aspect of the posterior femoral line as it intersects with Blumenstaats' line on a perfect lateral fluoroscopy image.^{40,28} Further complexity exists in attempting to replicate broad tibial insertion of the sMCL, which has been identified as 1.2 and 6 cm distal to the medial tibial joint line.⁴⁷

The use of 2 separate grafts provides the advantage of creating native anatomic distal and proximal attachment sites as well as individual tensioning of the sMCL and POL.^{1,25} However, this procedure requires extensive exposure, multiple drill tunnels with a risk for ligament transection when concurrent with cruciate ligament bone tunnel preparation. In addition, multiple graft usage is technically challenging and may potentially require more hardware than any other technique. More importantly, there is concern that this more comprehensive technique may contribute to stress shielding. Additionally, a dual graft construct may be significantly stronger and stiffer than the native medial ligamentous anatomy and result in altered knee mechanics.⁵⁴

More recent techniques have attempted to emulate both the form and function of the MCL and posteromedial corner. On the basis of biomechanical data, Wijdicks et al. ascertained that the sMCL was the primary restraint to valgus stress throughout the knee range of motion, while the distal division of the sMCL primarily counteracted external rotation torque with

increasing knee flexion.²⁴ By contrast, the POL was most critical in preventing valgus and internal rotation near a position of full extension. This is reflected in the tensioning protocol of the sMCL in most surgical techniques. In POL tensioning, however, there is a lack of consensus in the available literature, with fixation recommended in varying degrees of knee flexion and with or without varus stress or internal rotation. To avoid overconstraint of posteromedial capsule and resultant losses in knee extension, POL graft fixation has more recently been recommended at 0° of knee flexion.^{1,7,39}

Polyester suture tape or artificial ligament augments have also been described in the literature.^{37,35,55} These techniques may prove to be less technically challenging and more reproducible than many other available techniques, while avoiding the potential risks and complications from allograft and autograft use. Additionally, the sMCL and POL are individually tensioned and reconstructed through a synthetic augmentation, allowing for a more native anatomic repair at their precise attachment sites. The less invasive nature of the technique with less hardware may allow for an immediate postoperative range of motion and controlled weight bearing, ultimately leading to a faster recovery. However, the exclusive use of nonbiologic grafts is inadequately studied to date, and its role in future knee reconstruction techniques has yet to be determined.

Limitations

As with any systematic review, the authors acknowledge several potential limitations. Several non-English language studies describing MCLR techniques could not be translated and were therefore excluded. Although our primary purpose in this systematic review was to evaluate and compare various MCL reconstruction techniques, a meta-analysis comparing clinical outcomes among all techniques was not possible owing to the preponderance of described surgical techniques with limited reports of clinical outcomes after medial knee reconstruction. Of those modestly sized level IV case series available, clinical heterogeneity, variable outcome measures, coexisting knee injuries, and concomitant procedures preclude meaningful comparative analysis of various MCLR techniques.

Conclusions

This systematic review demonstrated that numerous medial reconstruction techniques have been used in the treatment of isolated and combined medial knee injuries in the existent literature. Many variations exist among reconstruction techniques and may differ by graft choices, method of fixation, number of bundles, tensioning protocol, and degree of anatomic restoration of medial and posteromedial corner knee restraints. Further studies are required to better ascertain the comparative clinical outcomes with anatomic,

nonanatomic, and tendon transfer techniques for medial knee reconstruction.

Acknowledgment

The authors would like to acknowledge Kelly Carvallis, B.F.A., M.A., for her significant contribution in developing the medical Illustrations.

References

1. LaPrade RF, Wijdicks CA. Surgical technique: development of an anatomic medial knee reconstruction. *Clin Orthop Relat Res* 2012;470:806-814.
2. Edson CJ. Conservative and postoperative rehabilitation of isolated and combined injuries of the medial collateral ligament. *Sports Med Arthrosc* 2006;14:105-110.
3. Gardiner JC, Weiss JA, Rosenberg TD. Strain in the human medial collateral ligament during valgus loading of the knee. *Clin Orthop Relat Res* 2001;391:266-274.
4. Millett PJ, Pennock AT, Sterett WI, Steadman JR. Early ACL reconstruction in combined ACL-MCL injuries. *J Knee Surg* 2004;17:94-98.
5. Halinen J, Lindahl J, Hirvensalo E, Santavirta S. Operative and nonoperative treatments of medial collateral ligament rupture with early anterior cruciate ligament reconstruction: a prospective randomized study. *Am J Sports Med* 2006;34:1134-1140.
6. Zaffagnini S, Bignozzi S, Martelli S, Lopomo N, Marcacci M. Does ACL reconstruction restore knee stability in combined lesions?: An in vivo study. *Clin Orthop Relat Res* 2007;454:95-99.
7. Liu X, Feng H, Zhang H, et al. Surgical treatment of subacute and chronic valgus instability in multiligament-injured knees with superficial medial collateral ligament reconstruction using Achilles allografts: A quantitative analysis with a minimum 2-year follow-up. *Am J Sports Med* 2013;41:1044-1050.
8. Dong JT, Chen BC, Men XQ, et al. Application of triangular vector to functionally reconstruct the medial collateral ligament with double-bundle allograft technique. *Arthroscopy* 2012;28:1445-1453.
9. Canata GL, Chiey A, Leoni T. Surgical technique: does mini-invasive medial collateral ligament and posterior oblique ligament repair restore knee stability in combined chronic medial and ACL injuries? *Clin Orthop Relat Res* 2012;470:791-797.
10. Koga H, Muneta T, Yagishita K, Ju YJ, Sekiya I. Surgical management of grade 3 medial knee injuries combined with cruciate ligament injuries. *Knee Surg Sports Traumatol Arthrosc* 2012;20:88-94.
11. Marx RG, Hetsroni I. Surgical technique: medial collateral ligament reconstruction using Achilles allograft for combined knee ligament injury. *Clin Orthop Relat Res* 2012;470:798-805.
12. Osti L, Papalia R, Del Buono A, Merlo F, Denaro V, Maffulli N. Simultaneous surgical management of chronic grade-2 valgus instability of the knee and anterior cruciate ligament deficiency in athletes. *Knee Surg Sports Traumatol Arthrosc* 2010;18:312-316.

13. Lind M, Jakobsen BW, Lund B, Hansen MS, Abdallah O, Christiansen SE. Anatomical reconstruction of the medial collateral ligament and posteromedial corner of the knee in patients with chronic medial collateral ligament instability. *Am J Sports Med* 2009;37:1116-1122.
14. Yoshiya S, Kuroda R, Mizuno K, Yamamoto T, Kurosaka M. Medial collateral ligament reconstruction using autogenous hamstring tendons: technique and results in initial cases. *Am J Sports Med* 2005;33:1380-1385.
15. Frank CB. Ligament structure, physiology and function. *J Musculoskelet Neuronal Interact* 2004;4:199-201.
16. Azar FM. Evaluation and treatment of chronic medial collateral ligament injuries of the knee. *Sports Med Arthrosc* 2006;14:84-90.
17. Woo SL, Vogrin TM, Abramowitch SD. Healing and repair of ligament injuries in the knee. *J Am Acad Orthop Surg* 2000;8:364-372.
18. Hannafin JA, Attia ET, Warren RF, Bhargava MM. Characterization of chemotactic migration and growth kinetics of canine knee ligament fibroblasts. *J Orthop Res* 1999;17:398-404.
19. Woo SL, Inoue M, McGurk-Burleson E, Gomez MA. Treatment of the medial collateral ligament injury. II. Structure and function of canine knees in response to differing treatment regimens. *Am J Sports Med* 1987;15:22-29.
20. Kannus P. Long-term results of conservatively treated medial collateral ligament injuries of the knee joint. *Clin Orthop Relat Res* 1988;226:103-112.
21. Miyamoto RG, Bosco JA, Sherman OH. Treatment of medial collateral ligament injuries. *J Am Acad Orthop Surg* 2009;17:152-161.
22. Wijdicks CA, Griffith CJ, Johansen S, Engebretsen L, LaPrade RF. Injuries to the medial collateral ligament and associated medial structures of the knee. *J Bone Joint Surg Am* 2010;92:1266-1280.
23. Shapiro MS, Markolf KL, Finerman GA, Mitchell PW. The effect of section of the medial collateral ligament on force generated in the anterior cruciate ligament. *J Bone Joint Surg Am* 1991;73:248-256.
24. Wijdicks CA, Griffith CJ, LaPrade RF, et al. Medial knee injury. Part 2. Load sharing between the posterior oblique ligament and superficial medial collateral ligament. *Am J Sports Med* 2009;37:1771-1776.
25. Coobs BR, Wijdicks CA, Armitage BM, et al. An in vitro analysis of an anatomical medial knee reconstruction. *Am J Sports Med* 2010;38:339-347.
26. Bosworth DM. Transplantation of the semitendinosus for repair of laceration of medial collateral ligament of the knee. *J Bone Joint Surg Am* 1952;34-A:196-202.
27. Kim SJ, Lee DH, Kim TE, Choi NH. Concomitant reconstruction of the medial collateral and posterior oblique ligaments for medial instability of the knee. *J Bone Joint Surg Br* 2008;90:1323-1327.
28. Wijdicks CA, Griffith CJ, LaPrade RF, et al. Radiographic identification of the primary medial knee structures. *J Bone Joint Surg Am* 2009;91:521-529.
29. LaPrade RF, Engebretsen AH, Ly TV, Johansen S, Wentorf FA, Engebretsen L. The anatomy of the medial part of the knee. *J Bone Joint Surg Am* 2007;89:2000-2010.
30. Mroz TE, Joyce MJ, Steinmetz MP, Lieberman IH, Wang JC. Musculoskeletal allograft risks and recalls in the United States. *J Am Acad Orthop Surg* 2008;16:559-565.
31. Baer GS, Harner CD. Clinical outcomes of allograft versus autograft in anterior cruciate ligament reconstruction. *Clin Sports Med* 2007;26:661-681.
32. Mahirogullari M, Ferguson CM, Whitlock PW, Stabile KJ, Poehling GG. Freeze-dried allografts for anterior cruciate ligament reconstruction. *Clin Sports Med* 2007;26:625-637.
33. Nagda SH, Altobelli GG, Bowdry KA, Brewster CE, Lombardo SJ. Cost analysis of outpatient anterior cruciate ligament reconstruction: autograft versus allograft. *Clin Orthop Relat Res* 2010;468:1418-1422.
34. Rice RS, Waterman BR, Lubowitz JH. Allograft versus autograft decision for anterior cruciate ligament reconstruction: an expected-value decision analysis evaluating hypothetical patients. *Arthroscopy* 2012;28:539-547.
35. Ibrahim SA, Ahmad FH, Salah M, Al Misfer AR, Ghaffer SA, Khirat S. Surgical management of traumatic knee dislocation. *Arthroscopy* 2008;24:178-187.
36. Liu H, Wang F, Kang H, Chen B, Zhang Y, Ma L. Anatomical reconstruction of the medial collateral ligament and the posterior oblique ligament of the knee. *Acta Orthop Belg* 2012;78:400-404.
37. Kitamura N, Ogawa M, Kondo E, Kitayama S, Tohyama H, Yasuda K. A novel medial collateral ligament reconstruction procedure using semitendinosus tendon autograft in patients with multiligamentous knee injuries: clinical outcomes. *Am J Sports Med* 2013;41:1274-1281.
38. Fanelli GC, Edson CJ. Arthroscopically assisted combined anterior and posterior cruciate ligament reconstruction in the multiple ligament injured knee: 2- to 10-year follow-up. *Arthroscopy* 2002;18:703-714.
39. Preiss A, Giannakos A, Frosch KH. [Minimally invasive augmentation of the medial collateral ligament with autologous hamstring tendons in chronic knee instability]. *Oper Orthop Traumatol* 2012;24:335-347 [in German].
40. Stannard JP, Black BS, Azbell C, Volgas DA. Posteromedial corner injury in knee dislocations. *J Knee Surg* 2012;25:429-434.
41. Creighton RA, Spang JT, Dahners LE. Basic science of ligament healing: Medial collateral ligament healing with and without treatment. *Sports Med Arthrosc* 2005;13:145-150.
42. Weimann A, Schatka I, Herbolt M, et al. Reconstruction of the posterior oblique ligament and the posterior cruciate ligament in knees with posteromedial instability. *Arthroscopy* 2012;28:1283-1289.
43. Feeley BT, Muller MS, Allen AA, Granchi CC, Pearle AD. Biomechanical comparison of medial collateral ligament reconstructions using computer assisted navigation. *Am J Sports Med* 2009;37:1123-1130.
44. Borden PS, Kantaras AT, Caborn DN. Medial collateral ligament reconstruction with allograft using a double-bundle technique. *Arthroscopy* 2002;18:E19.
45. Gorin S, Paul DD, Wilkinson EJ. An anterior cruciate ligament and medial collateral ligament tear in a skeletally immature patient: a new technique to augment primary repair of the medial collateral ligament and an allograft

- reconstruction of the anterior cruciate ligament. *Arthroscopy* 2003;19:E21-26.
46. Liu F, Yue B, Gadikota HR, et al. Morphology of the medial collateral ligament of the knee. *J Orthop Surg Res* 2010;5:69.
 47. Jacobson KE, Chi FS. Evaluation and treatment of medial collateral ligament and medial-sided injuries of the knee. *Sports Med Arthrosc* 2006;14:58-66.
 48. Rue JPH, Lewis PB, Detterline AJ, Verma N, Bach BR. Minimally invasive medial collateral ligament reconstruction using Achilles tendon allograft. *Tech Knee Surg* 2007;6:266-273.
 49. Zhang H, Bai X, Sun Y, Han X. Tibial inlay reconstruction of the medial collateral ligament using Achilles tendon allograft for the treatment of medial instability of the knee. *Knee Surg Sports Traumatol Arthrosc* 2014;22:279-284.
 50. Wahl CJ, Nicandri G. Single-Achilles allograft posterior cruciate ligament and medial collateral ligament reconstruction: a technique to avoid osseous tunnel intersection, improve construct stiffness, and save on allograft utilization. *Arthroscopy* 2008;24:486-489.
 51. Warren LF, Marshall JL. The supporting structures and layers on the medial side of the knee: an anatomical analysis. *J Bone Joint Surg Am* 1979;61:56-62.
 52. O'Donoghue DH. Surgical treatment of fresh injuries to the major ligaments of the knee:1950. *J Bone Joint Surg Am* 2007;454:23-26 (discussion 14).
 53. Sims WF, Jacobson KE. The posteromedial corner of the knee: Medial-sided injury patterns revisited. *Am J Sports Med* 2004;32:337-345.
 54. Van den Bogaerde JM, Shin E, Neu CP, Marder RA. The superficial medial collateral ligament reconstruction of the knee: Effect of altering graft length on knee kinematics and stability. *Knee Surg Sports Traumatol Arthrosc* 2011;19: S60-608 (suppl 1).
 55. Lubowitz JH, MacKay G, Gilmer B. Knee medial collateral ligament and posteromedial corner anatomic repair with internal bracing. *Arthrosc Tech* 2014;3:e505-508.
 56. Adachi N, Ochi M, Deie M, Izuta Y, Kazusa H. New hamstring fixation technique for medial collateral ligament or posterolateral corner reconstruction using the mosaicplasty system. *Arthroscopy* 2006;22:571.e1-571.e3.
 57. Dong J, Ji G, Zhang Y, Gao S, Wang F, Chen B. Single allograft medial collateral ligament and posterior oblique ligament reconstruction: a technique to improve valgus and rotational stability. *Eur J Orthop Surg Traumatol* 2014;24:1025-1029.
 58. Stannard JP. Medial and posteromedial instability of the knee: Evaluation, treatment, and results. *Sports Med Arthrosc* 2010;18:263-268.
 59. Azar FM. Surgical treatment of ACL/PCL/medial-side knee injuries. *Surg Tech Sports Med* 2003;4:248-256.
 60. Fenton RL. Surgical repair of a torn tibial collateral ligament of the knee by means of the semitendinosus tendon (Bosworth procedure); Report of twenty-eight cases. *J Bone Joint Surg Am* 1957;39-A(2):304-308.
 61. Umansky AL. The Milch fasciodesis for the reconstruction of the tibial collateral ligament. *J Bone Joint Surg Am* 1952;34-A(1):202-206.

Appendix 1. Manual Searches of High-Impact Orthopaedic Sports Medicine Journals and Highly Attended Conference Proceedings

High-Impact Journals (2000-2014)

American Journal of Sports Medicine (AJSM)
Arthroscopy: The Journal of Arthroscopic and Related Surgery
Journal of Bone & Joint Surgery—American Volume (JBJS-Am)
Journal of American Academy of Orthopaedic Surgeons (JAAOS)
Knee Surgery, Sports Traumatology, Arthroscopy (KSSTA)
Clinical Orthopaedics and Related Research (CORR)
American Journal of Orthopaedics
Journal of Orthopaedics
Operative Techniques in Sports Medicine
Techniques in Knee Surgery
Operative Techniques in Orthopaedics
Techniques in Orthopaedics
Journal of Orthopaedic Trauma

Meeting Abstracts (2009-2013)

American Academy of Orthopaedic Surgeons Annual Meeting (AAOS)
International Society of Arthroscopy, Knee Surgery and Orthopaedic Sports Medicine Biennial Congress (ISAKOS)
American Orthopaedic Society for Sports Medicine Annual Meeting (AOSSM)
Arthroscopy Association of North America Annual Meeting (AANA)
American Orthopaedic Society for Sports Medicine Specialty Day (AOSSM)
