



# Concomitant reconstruction of the medial collateral and posterior oblique ligaments for medial instability of the knee

S.-J. Kim,  
D.-H. Lee,  
T.-E. Kim,  
N.-H. Choi

From Yonsei  
University School of  
Medicine, Seoul,  
Korea

**We present the operative technique and clinical results of concomitant reconstruction of the medial collateral ligament (MCL) and the posterior oblique ligament for medial instability of the knee using autogenous semitendinosus tendon with preservation of the tibial attachment. The semitendinosus tendon graft between the screw on the medial epicondyle and the tibial attachment of the graft was overlapped by the MCL, while the graft between the screw and the insertion of the direct head of the semimembranosus tendon was overlapped by the central arm of the posterior oblique ligament. Assessment was by stress radiograph and the Lysholm knee scoring scale. After a mean follow-up of 52.6 months (25 to 92), the medial joint opening of the knee was within 2 mm in 22 of 24 patients. The mean Lysholm score was 91.9 (80 to 100).**

**Concomitant reconstruction of the MCL and posterior oblique ligament using autogenous semitendinosus tendon provides a good solution to medial instability.**

Conservative treatment for tears of the medial collateral ligament (MCL) of the knee usually gives a satisfactory outcome.<sup>1,2</sup> However, grade-3 injuries of the MCL, especially those associated with other ligamentous injuries, sometimes lead to chronic instability followed by disability.<sup>3,4</sup> In such cases, operative intervention is necessary. Our previous experience of performing repair of the MCL alone without reconstruction of the posterior oblique ligament has shown that the result was sometimes unsatisfactory.

The posterior oblique ligament-posterior medial corner complex has an important role in medial stability, repair of the medial ligaments without treatment of the posterior oblique ligament will often not re-establish static stability.<sup>5-8</sup>

Over the past years, various surgical techniques have been described for the treatment of chronic medial instability, such as proximal advancement of the MCL or reconstruction of the MCL with the pes anserinus, but there are no descriptions of concomitant reconstruction of the MCL and the posterior oblique ligament.<sup>9,10</sup>

Our hypothesis was that anatomical reconstruction of these two ligaments concomitantly using autogenous semitendinosus tendon with the tibial attachment preserved would give good results, even in patients with sagittal instability of the knee. We describe the operative technique and our clinical results.

## Patients and Methods

Between December 1995 and March 2003, 26 consecutive patients with symptoms of instability associated with an excessive opening of the medial joint underwent concomitant reconstruction of the MCL and posterior oblique ligament. In this retrospective study, 24 of these patients were available for a minimum follow-up of two years.

The inclusion criterion was a residual medial instability of more than 5 mm, as shown by stress radiographs, but without lateral or posterolateral rotatory instability of the knee. Patients were excluded if they had a previous operative intervention, vascular injury involving the knee, or injury to both knees.

There were 21 men and three women with a mean age of 36.3 years (17 to 54). The mean follow-up was 52.6 months (25.0 to 92.0). The mean pre-operative duration of symptoms was 11 months (3 to 53). Nine patients had been injured in a pedestrian accident, nine during sporting activities, four in a road traffic accident and the remaining two in motorcycle accidents. Six had an isolated medial instability and the others had another associated ligamentous injury, of the anterior cruciate in 12 and the posterior cruciate ligament (PCL) in six.

All the procedures were performed by the senior author (S-JK). Informed consent was obtained from each patient.

■ S.-J. Kim, MD, PhD, FACS,  
Professor  
■ D.-H. Lee, MD, Clinical Fellow  
■ T.-E. Kim, MD, Clinical Fellow  
Department of Orthopaedic  
Surgery  
Yonsei University School of  
Medicine, 134 Shinchon-Dong,  
Seodaemun-ku, 120-752 Seoul,  
Korea.

■ N.-H. Choi, MD, Professor  
Department of Orthopaedic  
Surgery  
Eulji Medical Centre, Hageye-  
Dong, Nowon-Ku, 139-872,  
Seoul, Korea.

Correspondence should be sent  
to Dr D.-H. Lee; e-mail:  
doolungee@hotmail.com

©2008 British Editorial Society  
of Bone and Joint Surgery  
doi:10.1302/0301-620X.90B10.  
20781 \$2.00

*J Bone Joint Surg [Br]*  
2008;90-B:1323-7.  
Received 21 January 2008;  
Accepted after revision 10 June  
2008

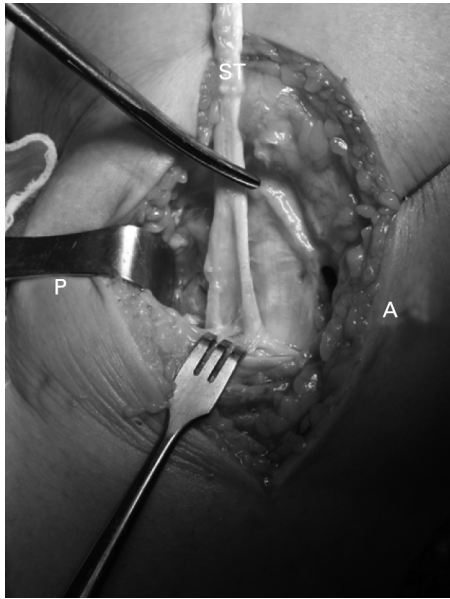


Fig. 1a

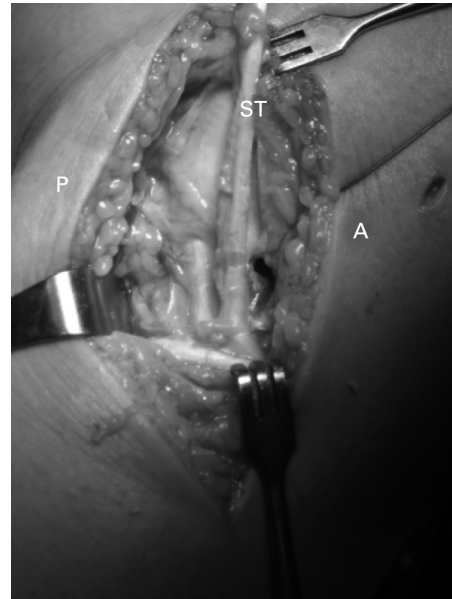


Fig. 1b

Photographs showing a) the semitendinosus tendon located posterior to the posterior bundle of the medial collateral ligament of a left knee and b) tibial insertion of the semitendinosus tendon overlapped by the anterior bundle of the medial collateral ligament by careful dissection of the posterior accessory insertion of the tendon (ST, semitendinosus; A, anterior aspect of the knee; P, posterior aspect of the knee).

### Operative techniques

**For medial instability of the knee.** A curvilinear skin incision was made from 3 cm above the medial femoral epicondyle to the insertion of the pes anserinus. The fascia was opened and sartorius and gracilis were retracted medially. After exposing the semitendinosus tendon, careful dissection of the tendon fibres attached to the medial head of gastrocnemius was performed in order to prevent premature cutting of the tendon. Following sectioning of the semitendinosus tendon at the musculotendinous junction, using a tendon stripper and with the tibial attachment preserved, the remnants of useless muscle of the tendon were removed with a periosteal elevator. The proximal end of the tendon was whip-stitched to a 2 cm length with a no. 2 non-absorbable suture. In order to allow overlapping of the tendon by the anterior bundle of the MCL, the posterior accessory tibial insertion of the tendon was dissected (Fig. 1). A 1.6 mm Kirschner wire was inserted tentatively on the anterosuperior border of the medial femoral epicondyle. After the semitendinosus tendon had been looped around the wire, isometricity was tested by pulling the suture at the tendon and moving the knee through a full range of movement. The isometric point was confirmed by the migration of the grafted tendon by less than 2 mm. Thereafter, a hole for screw-washer fixation 3.2 mm in diameter was drilled 9 mm (the radius of a washer) proximally from the isometric point. Decortication was performed around a drill hole 6 mm in radius on the femur. Then, a 6.5 mm cancellous screw and an 18 mm washer were placed through the

drill hole. While the knee was held in 30° of flexion with varus stress, the screw was tightened while the semitendinosus tendon looped around the shank was tensioned manually to allow fixation of the tendon at the distal edge of the washer, on the isometric point on the epicondyle (Fig. 2). The normal central arm of the posterior oblique ligament originates in the region of the adductor tubercle and courses posteriorly and obliquely to insert at the postero-medial corner of the tibia near the insertion of the direct head of the semimembranosus tendon (Fig. 3). After dissection to find the insertion of the direct head of the semimembranosus tendon, the free end of the grafted tendon was fixed proximally at the epicondyle and pulled under the dissected insertion of the direct head to overlap the central arm of the posterior oblique ligament. In 30° of knee flexion, the end of the semitendinosus tendon was tied by four non-absorbable sutures at the insertion of the direct head of the semimembranosus tendon (Fig. 4). The whip-stitched remnant of the semitendinosus tendon was then excised.

**For anterior and/or posterior instability.** Reconstruction of the anterior cruciate ligament (ACL) was performed using an autogenous bone-patellar tendon-bone graft and that of the posterior cruciate ligament by tendo-Achillis-bone graft allograft.

**Rehabilitation.** The exact post-operative rehabilitation protocol depended upon the patients and upon the particular injuries treated. In general, protected weight-bearing was enforced for approximately two weeks. The knee was braced in full extension for four or five weeks, followed by an unlocked functional brace which was worn until at

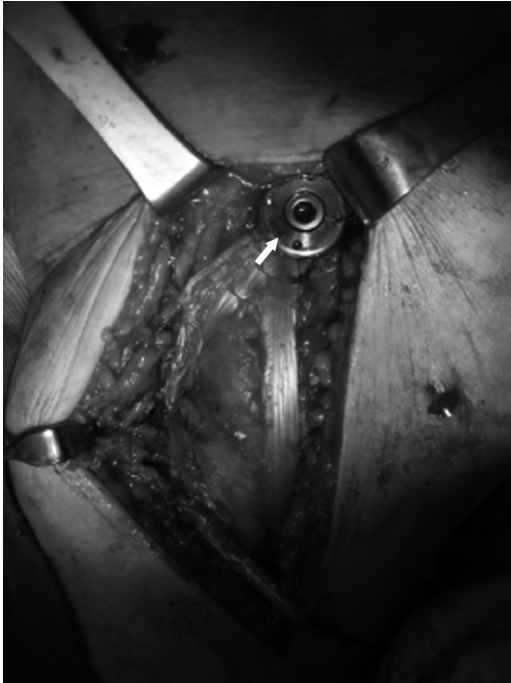

Fig. 2

Photograph showing a 6.5 mm cancellous screw with an 18 mm washer placed in the drill hole. The tendon graft was then looped around the shank of the screw to allow fixation at the distal edge of the washer on the isometric point (arrow) of the femur.

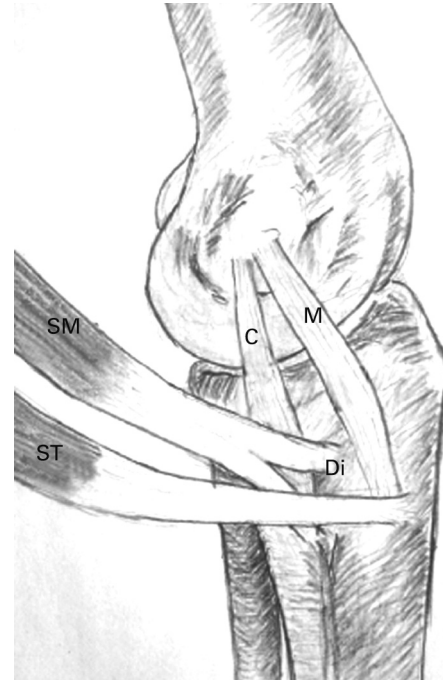


Fig. 3

Drawing showing that anatomically, the central arm (C) of the posterior oblique ligament originates in the region of the adductor tubercle and courses posteriorly and obliquely to insert at the posteromedial corner of the tibia near the insertion of the direct head (Di) of the semimembranosus tendon (SM, semimembranosus; ST, semitendinosus; M, medial collateral ligament).

least seven weeks after surgery. Passive and active-assisted exercises were started at four or five weeks after operation. Resistance exercises were increased at eight weeks. In most patients, full functional recovery was gained by six to 12 months.

**Functional assessment.** This was evaluated by the knee scoring scale of Lysholm and Gillquist<sup>11</sup> and the International Knee Documentation Committee (IKDC).<sup>12</sup> Physical examination included an assessment of the range of movement and instability of the knee by arthrometry or stress radiography. In the evaluation of stability, the measured value was compared with that of the contralateral normal knee, and a side-to-side difference in millimetres was used as an index. Medial instability was evaluated by stress radiographs in which the medial joint opening of the knee was measured with the knee in 20° of flexion. The stability was graded according to the IKDC form (normal, < 2 mm; nearly normal, 2 mm to 5 mm; abnormal, 5 mm to 10 mm; severely abnormal, > 10 mm). Instrumented testing of anterior stability was performed using a KT-1000 arthrometer (MEDmetric, San Diego, California) at 89 N with the knee flexed at 20°. Posterior translation with the knee flexed at 70° was measured on stress radiographs. The grading of sagittal instability was similar to that of medial instability. At every follow-up visit, the

evaluation methods were the same as those used at the initial assessment. The examiners were blinded to the patient records to eliminate bias.

**Statistical analysis.** We used the SPSS 13.0 ps.exe statistical program for the analysis (SPSS Inc, Chicago, Illinois). Descriptive statistics were computed for continuous data. For continuous variables, the statistical significance of the differences between the pre- and post-operative results was assessed using the Wilcoxon test. Comparisons were considered to be significant when the p-value was  $\leq 0.05$ .

## Results

**Medial instability.** Pre-operatively, the mean medial joint opening was 7.8 mm (5 to 12) on the valgus stress radiographs. At the latest follow-up, it was less than 2 mm (normal according to IKDC criteria) in 22 of 24 patients (92%), with a mean value of 1.1 mm (0 to 5). This change was significant (Wilcoxon test,  $p = 0.00$ ).

**Range of movement and functional results.** At the latest follow-up, the range of movement was normal (lack of extension or flexion of less than 5°) in 19 patients and nearly normal (lack of extension or flexion of less than 10°) in five. No patient had a lack of extension or flexion of more than 10°.

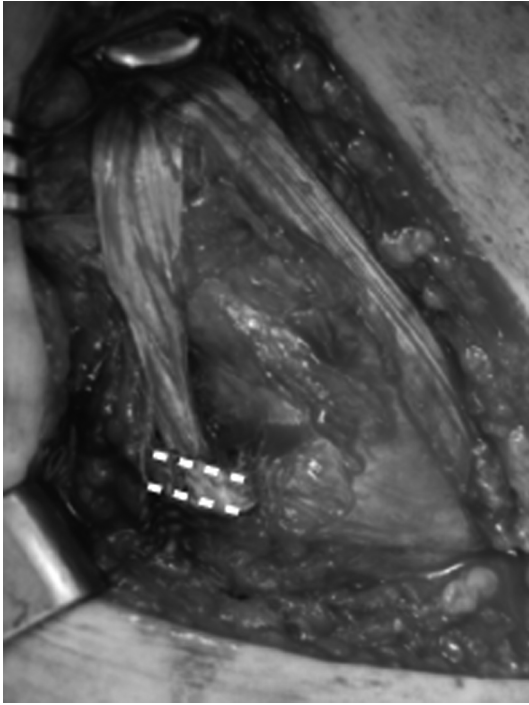


Fig. 4a

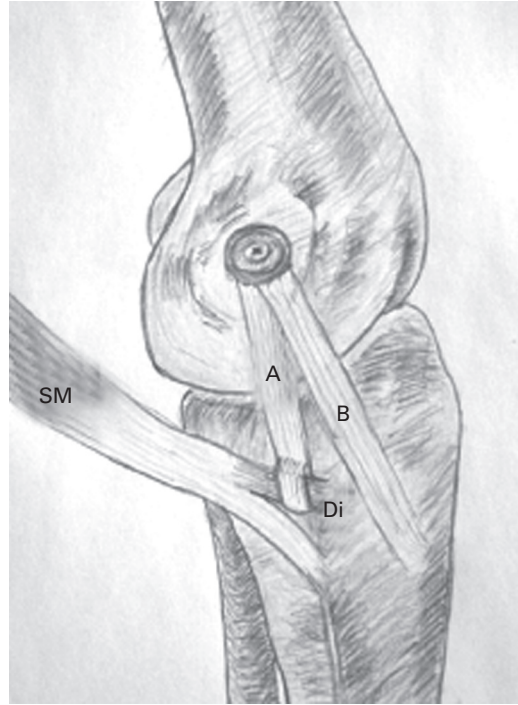


Fig. 4b

Figure 4a – Photograph showing the free end of the tendon graft pulled diagonally along the direction of the central arm of the posterior oblique ligament and sutured to the insertion of the direct head (Di) of the semimembranosus tendon (dotted line). Figure 4b – Drawing showing central arm of the posterior oblique ligament reconstructed by the semitendinosus tendon graft (A) and the medial collateral ligament reconstructed by semitendinosus tendon graft (B), and the semimembranosus tendon.

The mean post-operative Lysholm score was 91.9 (80 to 100). A post-operative IKDC score of normal was recorded in 12 patients (50%), of nearly normal in ten (42%) and of abnormal in two (8%).

**Sagittal instability.** At the latest follow-up, the side-to-side difference in anterior translation at 30° was satisfactory (normal or nearly normal according to IKDC criteria, with < 5 mm) in 11 of 12 knees (92%) with injury to the ACL. The side-to-side difference in posterior translation with the knee flexed at 70° was satisfactory (normal or nearly normal according to IKDC criteria, with < 5 mm) in five of six knees (83%) with reconstruction of the PCL.

**Complications.** There were no intra-operative complications. Post-operative complications included an acute superficial wound infection which settled unremarkably with antibiotics in one patient. There was late loosening of a screw in two patients and this caused painful crepitus and medial joint opening of 5 mm and 4 mm, respectively. On removal of the screw, partial necrosis of the graft tendons under the washer was noticed.

## Discussion

Several forms of surgical treatment have been described for chronic medial instability of the knee, including proximal advancement or reconstruction of the MCL.<sup>10,13,14</sup>

Proximal advancement of the MCL cannot be performed in cases in which the ligament substance is of poor quality and in these a reconstructive procedure should be performed. Non-anatomical reconstruction of the MCL has been carried out using the medial head of gastrocnemius or pes anserinus. Bosworth<sup>9</sup> described anterior translation of the semitendinosus tendon and its implantation on the medial femoral condyle, which resulted in slight laxity during flexion in half of the cases. Slocum and Larson<sup>15</sup> transplanted the lower two-thirds of the pes anserinus from its attachment on the medial aspect of the tibia to the tibial tubercle and the lower portion of the patellar tendon. Subsequently, these non-anatomical reconstructions proved to be unsatisfactory.<sup>9,15</sup>

Anatomical reconstruction of the anterior component of the MCL with the semitendinosus and gracilis tendons was introduced by Yoshiya et al<sup>16</sup> in 2005. Although they reported normal or nearly normal results according to the IKDC score in all 24 cases, injury to the posteromedial corner was not considered in the study.

Sims and Jacobsen<sup>8</sup> reported that 99% of medial injuries requiring operation had an associated injury to the posterior oblique ligament, which was overlooked in many reports. Hughston and Eilers<sup>6</sup> described the posterior oblique ligament as a thickening of the medial capsular

ligament attached proximally to the adductor tubercle of the femur and distally to the tibia and the posterior aspect of the capsule. Of the three arms of the posterior oblique ligament, the central arm was the thickest and probably the most important, originating in the region of the adductor tubercle and coursing posteriorly and obliquely to insert at the posteromedial corner near the insertion of the direct head of the semimembranosus tendon. From this anatomical relationship between the central arm of the posterior oblique ligament and the direct head of the semimembranosus tendon, we reconstructed the posterior oblique ligament by anchoring the semitendinosus tendon at the femoral epicondyle and suturing the distal end to the direct head of the semimembranosus tendon.

The posterior oblique ligament has a key role in the medial stability of the knee, and it has been reported that treatment of medial compartment ligaments without repair of the posterior oblique ligament often fails to achieve static stability.<sup>5-7,17</sup> When we had performed reconstruction of the MCL without that of the posterior oblique ligament, the result was sometimes unsatisfactory. Using our simple technique which involved reconstruction of the posterior oblique ligament concomitantly, 22 knees (92%) showed medial joint opening of less than 2 mm. In addition, the mean Lysholm score (91.9) observed in our study was comparable with that reported by Millett et al<sup>18</sup> (94.5) with isolated reconstruction of the ACL combined with grade-1 or grade-2 injuries of the MCL.

There is an important technical consideration which should be noticed while performing this procedure. The width of the washer should be taken into account when fixating the semitendinosus tendon in to the isometric point. If the drill hole for the screw is made on the isometric point, the semitendinosus tendon is actually fixed distal to the isometric point at a distance equal to the radius of the washer.


The main advantage of our technique was in achieving stability by concomitant reconstruction of the MCL and posterior oblique ligament. A second advantage was that the tibial side of the reconstructed MCL did not need to be fixed and this reduced the operating time in the knees with multiple injuries to ligaments. Finally, only a single autogenous graft was used for the reconstruction of two different ligaments, which is beneficial when the use of allograft is prohibited or in cases in which the high cost of the graft is not covered by medical insurance.

The main limitation of our study was the small number of cases. However, medial instability is usually treated well by conservative methods even when combined with injury to the cruciate ligaments, thereby reducing the number of patients requiring surgery. Also, this procedure could only be performed on a knee with an intact tibial attachment of the semitendinosus and semimembranosus tendons. If there was a severe injury to the direct head of the

semimembranosus tendon or substance, the posterior oblique ligament reconstructed by our technique would not provide enough stability. However, most injuries develop at the capsular arm of the semimembranosus tendon.<sup>8</sup> Another limitation of the study was that it was retrospective and this should be addressed along with its biases.

In conclusion, anatomical reconstruction of the MCL and posterior oblique ligament concomitantly using autogenous semitendinosus tendon with the tibial attachment preserved provides good stability and satisfactory results for medial instability on the knee.

### Supplementary Material

 A table showing details of surgery, follow-up and clinical scores is available with the electronic version of this article on our website at [www.jbjs.org.uk](http://www.jbjs.org.uk)

No benefits in any form have been received or will be received from a commercial party related directly or indirectly to the subject of this article.

### References

1. Kannus P. Long-term results of conservatively treated medial collateral ligament injuries of the knee joint. *Clin Orthop* 1988;226:103-12.
2. Indelicato PA. Non-operative treatment of complete tears of the medial collateral ligament of the knee. *J Bone Joint Surg [Am]* 1983;65-A:323-9.
3. Larson RL. Combined instabilities of the knee. *Clin Orthop* 1980;147:68-75.
4. Robins AJ, Newman AP, Burks RT. Postoperative return of motion in anterior cruciate ligament and medial collateral ligament injuries: the effect of medial collateral ligament rupture locations. *Am J Sports Med* 1993;21:20-5.
5. Hughston JC. The importance of the posterior oblique ligament in repairs of acute tears of the medial ligaments in knees with and without associated rupture of the anterior cruciate ligament: results of long-term follow-up. *J Bone Joint Surg [Am]* 1994;76-A:1328-44.
6. Hughston JC, Eilers AF. The role of the posterior oblique ligament in repairs of acute medial (collateral) ligament tears of the knee. *J Bone Joint Surg [Am]* 1973;55-A:923-40.
7. Jacobsen KE, Chi FS. Evaluation and treatment of medial collateral ligament and medial-sided injuries of the knee. *Sports Med Arthrosc* 2006;14:58-66.
8. Sims WF, Jacobsen KE. The posteromedial corner of the knee: medial-sided injury patterns revisited. *Am J Sports Med* 2004;32:337-45.
9. Bosworth DM. Transplantation of the semitendinosus for repair of laceration of the medial collateral ligament of the knee. *J Bone Joint Surg [Am]* 1952;34-A:196-202.
10. Healy WL, Iorio R, Lemos DW. Medial reconstruction during total knee arthroplasty for severe valgus deformity. *Clin Orthop* 1998;356:161-9.
11. Lysholm J, Gillquist J. Evaluation of knee ligament surgery results with special emphasis on use of a scoring scale. *Am J Sports Med* 1982;10:150-4.
12. Daniel DM, Stone ML, Dobson BE, et al. Fate of the ACL-injured patient: a prospective outcome study. *Am J Sports Med* 1994;22:632-44.
13. Grana WA, Gimple K. Reconstruction of traumatic complete loss of the medial collateral ligament: a case report. *Clin Orthop* 1981;160:153-7.
14. Nicholas JA. The five-one reconstruction for anteromedial instability of the knee: indication, technique, and the results in fifty-two patients. *J Bone Joint Surg [Am]* 1973;55-A:899-922.
15. Slocum DB, Larson RL. Pes anserinus transplantation: a surgical procedure for control of rotatory instability of the knee. *J Bone Joint Surg [Am]* 1968;50-A:226-42.
16. Yoshiya S, Kuruda R, Mizuno K, Yamamoto T, Kurosaka M. Medial collateral ligament reconstruction using autogenous hamstring tendons: technique and results in initial cases. *Am J Sports Med* 2005;33:1380-5.
17. Haimes JL, Wrable RR, Grood ES, Noyes FR. Role of the medial structures in the intact and anterior cruciate ligament-deficient knee: limit of motion in the human knee. *Am J Sports Med* 1994;22:402-9.
18. Millett PJ, Pennock AT, Sterett WI, Steadman JR. Early ACL reconstruction in combined ACL-MCL injuries. *J Knee Surg* 2004;17:94-8.