



ELSEVIER

Clinical outcomes following conservative and surgical management of floating shoulder injuries: a systematic review

Alex R. Dombrowsky, BS, Sellers Boudreau, BS, Jon Quade, MD,
 Eugene W. Brabston, MD, Brent A. Ponce, MD, Amit M. Momaya, MD*

Department of Orthopaedic Surgery, University of Alabama at Birmingham, Birmingham, AL, USA

Background: Floating shoulder is an uncommon injury characterized by fractures of the clavicle and ipsilateral scapular neck. No consensus exists on management. The purpose of this study was to analyze the existing literature on treatment and clinical outcomes of floating shoulder injuries to provide a baseline understanding of current treatment strategies of this injury.

Methods: A systematic review was performed to identify published literature on outcomes and management of floating shoulder injuries. Searches were performed using PubMed, Embase, and SCOPUS.

Results: Seventeen studies were identified that included data for 371 shoulders. The mean reported age was 39.4 years (range, 16–82) and the mean follow-up was 49.4 months (range, 6–312). The major mechanism of injury was motor vehicle accident (51%) followed by fall from height (16%). Of the 371 shoulders, 215 (58%) were treated surgically, whereas 156 shoulders (42%) were managed nonoperatively. The most commonly reported outcome score was the Constant-Murley score (9 studies), followed by the Herscovici Floating Shoulder Injury score (5 studies). The mean Constant-Murley score was 80% of ideal maximum for both shoulders treated surgically and those treated nonoperatively.

Conclusion: Satisfactory outcomes can be expected following both surgical fixation and nonoperative management of floating shoulder injuries when appropriately individualized to the patient, as evidenced by clinical outcome scores. Floating shoulder injuries with significant displacement of the scapular neck may benefit from surgical fixation of both the clavicle and scapula fractures. In those with minimal or nondisplaced scapular neck fractures, good outcomes may be achieved when treated nonoperatively or with surgical fixation of the clavicle alone.

Level of evidence: Level IV; Systematic Review

© 2019 Journal of Shoulder and Elbow Surgery Board of Trustees. All rights reserved.

Keywords: Floating shoulder; trauma; clavicle fracture; scapular neck fracture; outcomes; management

Institutional Review Board approval was not required for this systematic review.

*Reprint requests: Amit M. Momaya, MD, Department of Orthopaedic Surgery, University of Alabama at Birmingham, 1313 13th St S, Office 208, Birmingham, AL 35205, USA.

E-mail address: amit.momaya@gmail.com (A.M. Momaya).

The floating shoulder injury is a rare, complex injury to the shoulder girdle caused by high-energy trauma. Herscovici¹⁰ first described the floating shoulder injury in 1992 as a midclavicular fracture combined with a fracture of the ipsilateral scapular neck. Goss⁷ further expanded the concept of the floating shoulder to include any double disruption of

the superior shoulder suspensory complex. This injury has been described as anatomically unstable as the weight of the arm and action of surrounding muscles pulls the glenohumeral joint distally and anteromedially, which leads to dysfunction and shoulder deformity.^{7,10} Williams et al²² further investigated the biomechanics of the superior shoulder suspensory complex and found that stability of the injured clavicle and scapular neck was dependent on whether associated injury of the acromioclavicular or coracoclavicular ligaments also occurred.

Although the importance of restoring the stability to the shoulder girdle is well understood, floating shoulder injuries are uncommon and the data on outcomes are limited. There is controversy in the literature on how to appropriately treat patients with floating shoulder injuries to optimize functional outcomes. Surgeons must decide whether to manage patients nonoperatively or to pursue surgical fixation of the clavicular fracture or both the clavicular and scapular fractures. Satisfactory outcomes have been reported in the orthopedic literature using all of these methods, yet there is a lack of consensus on how to manage these patients. The primary objective of this study was to synthesize the existing literature on clinical outcomes of floating shoulder injuries. The secondary objective was to evaluate the mechanism of injury, approaches in management, and treatment complications associated with such an injury. The purpose of this systematic review is to provide surgeons with an improved understanding of management and expected outcomes of these complex injuries. We hypothesize that reported outcomes will be similar between patients managed conservatively or with surgical treatment.

Methods

Eligibility criteria

This systematic review was conducted following the PRISMA (Preferred Reporting Items for Systematic Reviews and Meta-Analyses) checklist for systematic reviews. Studies were included if they reported clinical outcomes after floating shoulder injury. Only studies that included clinical outcome data with minimum 6-month follow-up were included. Case reports of <3 patients, reviews, scientific meeting abstracts, commentary, and studies published in a language other than English were excluded from the study.

Data sources and searches

MEDLINE, through PubMed, Embase, SCOPUS, and PROSPERO were searched for relevant publications in May 2018. The search term used for PROSPERO was “floating shoulder.” The search algorithm used in PubMed, Embase, and SCOPUS was “Floating shoulder” OR ((clavicle OR clavicular) AND (scapula OR scapular OR shoulder-blade OR scapula-neck OR scapular-neck OR glenoid-neck) AND (fracture OR trauma)) OR glenopolar angle.

Study selection and data extraction

The titles and abstracts of each article were reviewed by 2 investigators (A.D. and S.B.) to determine relevance to the study question. After excluding articles that were not relevant to the study, the full text of each article was reviewed and assessed for eligibility. Additionally, the references of each full-text article were reviewed to identify any studies not captured by the initial search. Study selection was performed independently by the 2 investigators, and any disputes were settled by consensus. Both investigators analyzed each included study and extracted data for analysis. Outcomes of interest included patient-reported outcome scores, range of motion or strength measurements, mechanism of injury, concomitant injury, indications for surgery, and management complication rates.

Results

The PROSPERO register reported no systematic reviews on floating shoulder injuries. The search of PubMed, Embase, and SCOPUS databases produced a total of 980 non-duplicate publications. After exclusion of nonrelevant titles, 159 abstracts were selected for review. Of these, 45 full-text articles were selected for formal review. No additional studies were identified from review of references. Following review of full-text articles, 17 studies met the inclusion criteria for further analysis (Fig. 1). One study reported on a duplicate patient cohort and was excluded. Two studies were Level II and 15 studies were Level IV.

Of the 17 included studies, 3 involved nonoperative management only of floating shoulder injuries, 6 involved surgical management only, and 8 involved a combination of both types of management. Of the studies that involved surgical management, 7 involved fixation of the clavicle fracture alone for all cases, 2 involved fixation of both the clavicle and scapula for all cases, and the remaining 8 studies involved some combination of fixation of clavicle only, fixation of scapula only, or fixation of both clavicle and scapula. Table I summarizes each of the included studies.

Patient demographics

The 17 studies that met inclusion criteria for review included data for 371 shoulders. The mean age was 39.3 years (range, 16-82). Of the studies that reported sex, there were 277 male and 81 female patients. The mean follow-up time was 47.5 months (range, 6-312 months).

Injury definition

There is significant variability in the definition of floating shoulder used to describe floating shoulder injuries among the included studies. Nine studies defined a floating shoulder injury as an ipsilateral fracture of the clavicle and scapular neck.^{6,9,11,14,18,20,21,23,24} Additionally, 2 studies

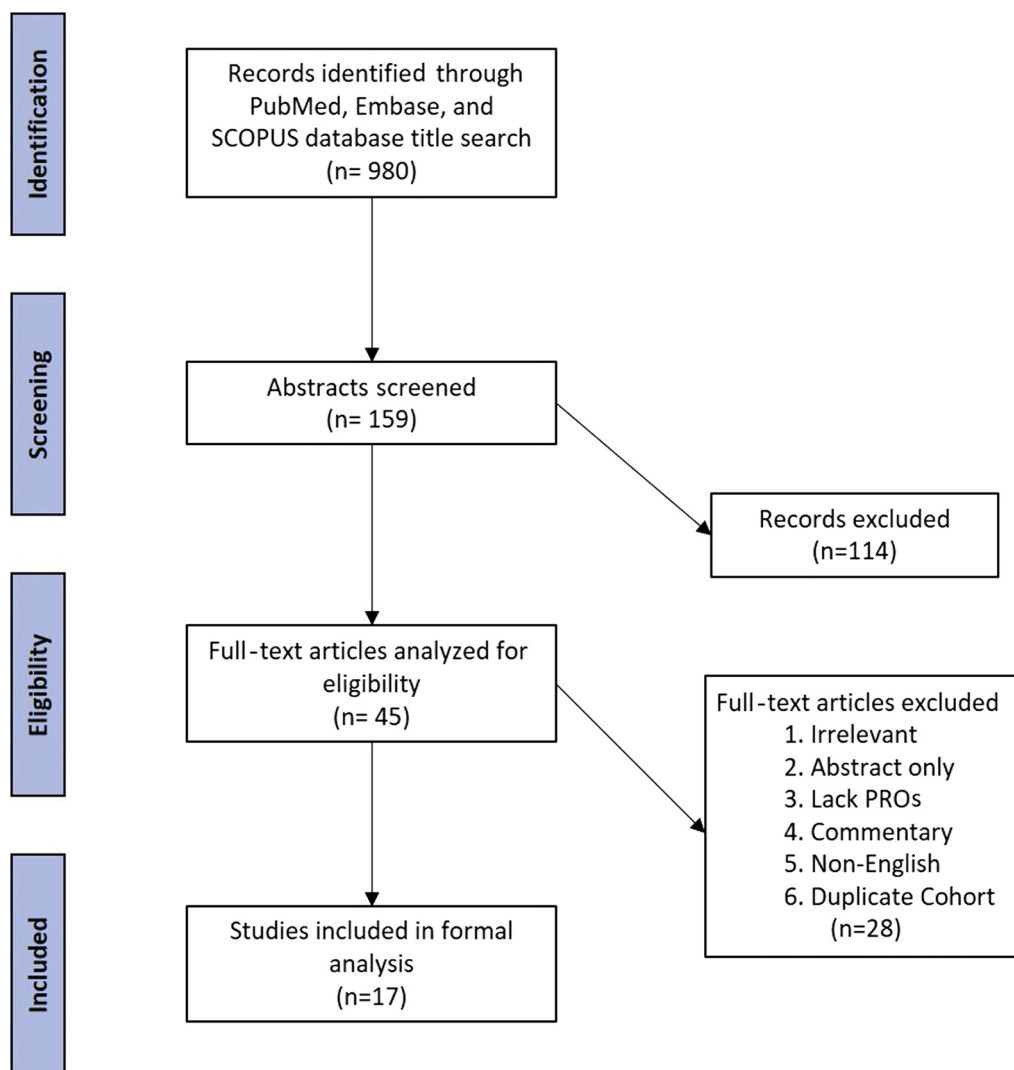


Figure 1 Literature selection algorithm. *PROs*, patient-reported outcomes.

specified that the clavicle and scapula fractures must be displaced.^{12,15} In addition to fractures of the scapular neck and ipsilateral clavicle, 3 studies included injury to the ipsilateral sternoclavicular or acromioclavicular complex as part of the definition.^{4,13,19} Three articles described the injury as a double disruption of the superior shoulder suspensory complex.^{3,16,17}

With regard to displacement of the scapular neck fracture, 3 studies stated that all scapular neck fractures were displaced and quantified the amount of displacement.^{6,13,15} Two studies reported that all displaced scapular neck fractures in the cohort were only minimally displaced.^{3,9} Three of the articles stated that none of the scapular neck fractures were displaced,^{11,17,20} and 2 of the studies did not mention displacement of the scapular neck.^{19,23} The remaining 7 articles mention that some of the scapular neck fractures are displaced, but do not disclose the amount of displacement or how the displaced fractures were distributed among the study groups.^{4,12,14,16,18,21,24}

Injury mechanism

The mechanism of injury was reported for 340 shoulders.^{3,4,6,9,13-21,23,24} Of these floating shoulder injuries, 174 (51%) were caused by motor vehicle accidents, 55 (16%) were caused by a fall from height, 44 (13%) were caused by motorcycle accidents, 32 (9%) were caused by bicycle accidents, 19 (6%) were due to pedestrian accidents, 2 (0.6%) injuries were caused by gunshot wounds and ATV accidents each, and 3 (0.9%) were due to other causes. Concomitant injuries were reported by 13 studies. There were 159 cases of rib fractures, 98 cases of head trauma, 87 cases of limb fractures, 83 cases of hemo-pneumothorax, 26 cases of spine fractures, 15 abdominal injuries, and 14 brachial plexus injuries. Additionally, there was 1 case each of bronchus rupture, heart contusion, Monteggia fracture, contusion cordis, and paraplegia. Of the 13 studies that reported on concomitant injuries, 9 studies reported rates of concomitant injury. Out of 141 floating shoulder injuries,

Table I Published studies reporting outcomes of floating shoulder injuries

First Author	Year	Journal	Level of evidence	Management method	No. of shoulders	Outcome reported	Follow-up, mo
Kim ¹²	2008	<i>J Trauma</i>	IV	NO (7), C (9)	16	Constant	32
Labler ¹³	2004	<i>J Trauma</i>	IV	NO (8), C (4), S+C (5)	17	Constant, ISS, SF-36	77.6
Lin ¹⁵	2015	<i>J Orthop Surg Res</i>	II	NO (13), C (13), S+C (13)	39	Constant, ISS, DASH	48
Hashiguchi ⁹	2003	<i>J Shoulder Elbow Surg</i>	IV	C (5)	5	UCLA	57.4
Zhou ²⁴	2017	<i>Biomedical Research (India)</i>	IV	NO (12), C (29), S+C (15)	56	Constant, Herscovici	17.1
Ramos ¹⁸	1997	<i>J Trauma</i>	IV	NO (16)	16	Herscovici	90
Edwards ³	2002	<i>Orthopedics</i>	IV	NO (20)	20	Constant, Rowe, Herscovici, ISS, SF-36	28
Samy ²⁰	2017	<i>Acta Orthopaedica Belgica</i>	IV	C (13)	13	UCLA	24.3
van Noort ²¹	2001	<i>J Bone Joint Surg Br</i>	IV	NO (28), C (7)	35	Constant	35
Egol ⁴	2001	<i>J Bone Joint Surg Am</i>	IV	NO (12), S+C (7)	19	SF-36, DASH, ASES	46.7
Izadpanah ¹¹	2012	<i>J Trauma Acute Care Surg</i>	IV	C (16)	16	Constant, ASES	35.8
Pailhes ¹⁷	2013	<i>Int J Shoulder Surg</i>	IV	NO (24), C (10), S(3), S+C (3)	40	Constant, SST, SF-12, DASH, OSS	135
Gilde ⁶	2015	<i>J Orthop Traumatol</i>	IV	C (13)	13	Herscovici	16
Leung ¹⁴	1993	<i>J Bone Joint Surg Am</i>	IV	S+C (15)	15	Rowe, ISS	25
Yadav ²³	2013	<i>Bone Joint J</i>	II	NO (13), C (12)	25	Herscovici	48
Oh ¹⁶	2002	<i>Int Orthop</i>	IV	NO (3), C (5), S+C (5)	13	Rowe	20
Rikli ¹⁹	1995	<i>J Orthop Trauma</i>	IV	C (12), S+C (1)	13	Constant	72

NO, nonoperative; C, clavicle only; S+C, scapula and clavicle; S, scapula only; ISS, Injury Severity Score; SF-36, Short Form-36; DASH, Disabilities of the Arm and Shoulder; UCLA, University of California-Los Angeles; ASES, American Shoulder and Elbow Surgeons; SST, Simple Shoulder Test; SF-12, Short Form-12; OSS, Oxford Shoulder Score.

133 (94.3%) had at least 1 additional injury. Furthermore, 5 studies gave detailed information on concomitant injury for each patient in the cohort. Out of 67 patients with floating shoulder injuries, the mean number of concomitant injuries was 3.1 injuries per patient.

Management

Among the 215 (58%) shoulders surgically treated, 151 (70%) involved fixation of the clavicle alone, 61 (28%) were treated by fixation of both the scapula and clavicle, and 3 (2%) were treated by fixation of the scapula only. The surgical techniques and indications for surgical fixation varied greatly among studies. Only 1 study compared 2 different surgical techniques, open reduction with plate fixation vs. intramedullary nailing of the clavicle.¹¹ They found that both techniques had functional outcomes and equal stabilization of the glenoid neck; however, in wedge (type B) and

multifragmentary (type C) clavicle fractures, intramedullary nailing of the clavicle resulted in secondary clavicle shortening of approximately 5 mm. Additionally, 156 shoulders (42%) were treated nonoperatively. The nonoperative protocol, when reported, varied greatly among the studies.

Outcome measures

A total of 13 different outcome measures were reported by the included studies. The outcome score most commonly reported was the Constant-Murley score followed by the Herscovici Floating Shoulder Injury Efficacy Scoring System. The mean Constant-Murley score obtained was 80.3% of the ideal maximum. The overall outcome scores are summarized in Table II. Outcome scores stratified by management technique are shown in Table III. Further stratification of surgically managed injuries by operative technique is shown in Table IV.

Table II Functional outcome measures after floating shoulder injury

Outcome measure	No. of studies	No. of shoulders	Mean score	Percent ideal
Constant-Murley	9	252	80.3	80
Rowe	3	48	88.9	89
Herscovici	5	130	13.2	83
Injury Severity Score	4	91	20.7	41
Simple Shoulder Test	1	40	10.5	88
Short Form-12	1	40	55	55
36-Item Short Form Health Survey	3	56	548.2	69
University of California-Los Angeles rating scale	2	18	32.8	94
Disabilities of the Arm, Shoulder, and Hand score	3	98	21.5	79
Oxford Shoulder Score	1	40	14	29
American Shoulder and Elbow Surgeon Score	2	35	82.7	83

The glenopolar angle (GPA) was reported by 8 studies^{11-13,15,17,20,23,24}. Both the preoperative and follow-up GPAs were available for 106 shoulders. Only the preoperative GPA was available for 73 shoulders and only the follow-up GPA was available for 65 shoulders. The mean preoperative GPA was 24° and the mean follow-up GPA was 28.9°. The mean GPA was 22.7° in patients managed nonoperatively and 29.7° in those managed surgically.

Objective strength or range of motion testing was performed in 4 studies.^{4,14,17,18} In the study by Egol et al,⁴ the mean forward elevation at follow-up in the nonoperative group (12 shoulders) and surgically managed group (7 shoulders) was 176° and 153°, respectively. Additionally, external rotation and internal rotation strength were reported as 35% weaker and 22% weaker in the surgical group and the nonoperative group, respectively. In the study by Pailhes et al,¹⁷ the mean forward elevation at follow-up in the nonoperative group (24 shoulders) and surgically managed group (16 shoulders) was 144° and 155°, respectively, and the external rotation at follow-up was 46° and 53°, respectively. Of the 15 shoulders reported by Leung et al¹⁴ (all treated with surgical fixation of both the

clavicle and scapula), 8 patients had between 150° and 170° of forward elevation and 7 had 120°-150° of range of motion. Additionally, 9 shoulders had 80° of external rotation whereas 6 had 60° of external rotation. Ramos et al¹⁸ reported on 16 nonoperatively managed shoulders, with 4 shoulders having >120° of elevation, 3 with 90°-120°, 2 with 45°-90°, and 1 with <45°. In addition, 4 shoulders had grade 5 muscle strength, 3 shoulders had grade 4 strength, 2 shoulders had grade 3 strength, and 1 shoulder had grade 2 or less.

Complications

Complications data were reported for 280 shoulders. Of the 116 nonoperatively treated shoulders with reported complications, there were 7 cases of delayed fracture healing, 6 cases of caudal dislocation of the glenoid, 4 cases of clavicular nonunion, 2 cases of a symptomatic clavicular bump, and 6 cases of asymmetry. In the 164 shoulders that were treated surgically with available complication data, there were 12 cases of hardware failure, 9 cases of scapular malunion, 6 cases of caudal dislocation of glenoid, 6 wound

Table III Comparison of outcomes of floating shoulder injury treated conservatively vs. surgically

Outcome measure	Conservative				Surgical			
	No. of studies	No. of shoulders	Mean score	Percentage ideal	No. of studies	No. of shoulders	Mean score	Percentage ideal
Constant	7	112	80.3	80	8	140	80.3	80
Rowe	2	23	92.2	92	2	25	85.8	86
Herscovici	4	61	13.2	83	3	69	13.3	83
ISS	3	41	22.7	45	3	50	19.0	38
SST	1	24	10.8	90	1	16	10.3	86
SF-12	1	24	55.2	55	1	16	54.8	55
SF-36	2	20	540.8	68	1	9	566.5	68
UCLA	—	—	—	—	2	18	32.8	94
DASH	3	49	22.3	78	2	42	16.0	84
OSS	1	24	15.0	31	1	16	15.9	33
ASES	1	12	80.2	80	1	16	82.0	82

ISS, Injury Severity Score; SST, Simple Shoulder Test; SF-12, Short Form-12; SF-36, Short Form-36; UCLA, University of California-Los Angeles; DASH, Disabilities of the Arm and Shoulder; OSS, Oxford Shoulder Score; ASES, American Shoulder and Elbow Surgeons.

Table IV Comparison of surgical fixation of clavicle and scapula vs. clavicle alone

Outcome measure	Clavicle Only				Clavicle + Scapula			
	No. of studies	No. of shoulders	Mean score	Percentage ideal	No. of studies	No. of shoulders	Mean score	Percentage ideal
Constant	6	81	76.9	77	3	30	81.6	82
Rowe	1	5	88.0	88	2	20	85.3	85
Herscovici	3	54	13.3	83	1	15	13.0	81
ISS	2	20	15.7	31	3	30	21.3	43
SF-36	1	7	561.6	70	2	9	570.3	71
UCLA	2	18	32.8	94	—	—	—	—
DASH	1	13	26.5	73	2	20	17.8	82
ASES	1	16	82.0	82	1	7	88.7	89

ISS, Injury Severity Score; SF-36, Short-Form 36; UCLA, University of California-Los Angeles; DASH, Disabilities of the Arm and Shoulder; ASES, American Shoulder and Elbow Surgeons.

infections, 5 cases of asymmetry, 3 nerve injuries, 2 cases of delayed fracture healing, 1 pneumothorax that occurred during the operation, and 1 nonunion of the clavicle.

Discussion

Because of the rare nature of floating shoulder injuries, reported outcomes are limited to small case series. This review aims to offer a summary of the existing reported outcomes on floating shoulder injuries in a form that can be used by clinicians to help guide management decisions.

Scapular neck displacement

In a biomechanical study by Williams et al,²² it was found that in the absence of any other injury, an ipsilateral fracture of the clavicle does not inherently result in an unstable scapular neck fracture. They noted that an additional injury of either the acromioclavicular ligament and coracoacromial ligament or the coracoacromial ligament and coracoclavicular ligament is necessary to produce a true floating shoulder. In the absence of an acromion fracture, distal clavicle fracture, or disruption of the acromioclavicular joint, ligamentous injury can be difficult to interpret from radiographs. However, displacement of the scapular neck fracture may serve as an indirect sign of a truly unstable floating shoulder injury.

In a study by Lin et al,¹⁵ all patients had >20 mm of displacement of the scapular neck fracture and those that underwent fixation of both fractures were found to have significantly better outcome scores than those treated either with fixation of only the clavicle or nonoperative management. Although Labler et al¹³ noted no significant difference in outcome scores between patients treated surgically or nonoperatively, none of the patients in the nonoperative group had displacement >20 mm. Those in the operative group with greater displacement (>25 mm) underwent fixation of both scapula and clavicle fractures.

Gilde et al⁶ recommended only clavicle fixation be used for minimally displaced floating shoulder injuries. Additionally, van Noort et al^{6,21} found that regardless of whether patients were treated conservatively or underwent fixation of clavicle only, those with persistent caudal dislocation of the scapular neck had lower mean outcome scores. Similarly, Oh et al¹⁶ identified that patients with scapular neck fractures displaced >1 cm had poor functional results compared with those with minimally displaced fractures. Although some authors have used the amount of 20-25 mm of displacement to guide treatment decisions, this study was unable to identify a cut-off for the amount of displacement that warrants surgical fixation of the scapular neck fracture.

Surgical fixation vs. conservative treatment

There have been 2 randomized trials in recent years. In a study of 39 shoulders, Lin et al¹⁵ compared fixation of the clavicle and scapula, fixation of the clavicle alone, and conservative treatment using a sling for 4 weeks and found that shoulders managed with fixation of both the clavicle and scapula had significantly better Constant score, Disabilities of the Arm and Shoulder (DASH) score, and GPA at follow-up compared to shoulders managed conservatively. Similarly, in a randomized trial by Yadav et al,²³ surgical fixation of the clavicle alone was compared with conservative management with a “figure-8” bandage and triangular sling. Although there was no significant difference in the time to union of the clavicle or scapula fracture between the 2 groups, the clavicle fixation group had a significantly higher Herscovici score 2 years after injury (14.9) compared with the conservatively managed group (13.1). Patients treated surgically were able to come out of the sling sooner than conservatively managed patients, which allowed for earlier rehabilitation and potentially better outcomes.

Some of the retrospective studies included in the review found better results with surgical fixation of floating

shoulder injuries. Both Kim et al¹² and Oh et al¹⁶ found higher patient outcome scores in shoulders managed surgically compared with those managed nonoperatively. Similarly, Zhou et al²⁴ showed that the Herscovici and Constant outcome scores were significantly higher in patients managed surgically compared with a nonoperatively managed group. The authors postulated that surgical fixation restores the continuity of the superior suspensory shoulder complex and functionality of the shoulder, allowing for earlier return to exercise and improved functional outcomes.

Other authors have espoused nonoperative treatment. Ramos et al¹⁸ reported on outcomes of floating shoulder injuries that were treated nonoperatively with a Velpau or Watson Jones bandage followed by rehabilitation 1 month after the injury. Of the 13 shoulders, 11 had excellent outcomes, 1 had good outcomes, and 1 had fair outcomes, with an overall mean Herscovici score of 14.6. However, the patients in this cohort had a much lower rate of concomitant injuries (56%), which may indicate that patients had lower-energy injuries and were more likely to have favorable outcomes. In a similar fashion, Edwards et al³ evaluated 20 patients treated nonoperatively with a sling or shoulder immobilizer followed by physical therapy as soon as associated injuries allowed. In this cohort, 17 patients had excellent results and 3 had good results based on the Herscovici score, with similar results seen according to the Rowe score; however, the scapular fractures in most of the patients in this study were minimally displaced (<5 mm). Although these 2 studies recommend nonoperative management of these injuries, both cohorts contained less severe injuries with minimal scapular neck displacement.

Despite the previous evidence, some studies have failed to show a difference. Pailhes et al¹⁷ and Labler et al¹³ found no significant difference in outcome between patients managed surgically and those managed nonoperatively. However, in the study by Labler et al, none of the patients treated operatively had scapular displacement >20 mm and overall had less severe injuries than those in the surgically treated group. Similarly, in the study by Pailhes et al, patients with minimal displacement were assigned to the nonoperative group and those with displacement >1 cm were treated surgically. Egol et al⁴ found no significant differences in outcomes if treated surgically or nonoperatively but did demonstrate better forward flexion and weaker internal rotation in surgically managed shoulders and better strength in conservatively managed injuries to the nondominant arm. Although the authors note that all scapular neck fractures are displaced, they fail to mention the amount of displacement. Additionally, van Noort et al²¹ found that shoulders managed conservatively had a higher mean Constant score than those managed surgically (76 and 71, respectively). However, in patients with caudally displaced fracture of the scapular neck, the mean Constant score was 20 points higher in patients managed surgically.

Although there is evidence in the literature to support both conservative and surgical management of floating

shoulder injuries, on careful review it appears that patient selection plays a critical role in the outcomes of different treatment modalities. In the studies that recommend nonoperative treatment, scapular neck fractures were minimally displaced and patients had overall less severe injuries. In 2 of the studies that claim no difference between nonoperative and surgical management, there is apparent selection bias, with patients having more displaced scapular neck fractures being managed surgically and those with minimal displacement being treated nonoperatively. In the other 2 studies claiming no difference, one found that those with displacement perform better with surgical management and the other did not disclose the amount of displacement of scapular neck fractures, making it challenging to compare with other studies. Furthermore, in the 2 randomized controlled trials, surgical management was shown to lead to better outcomes than nonoperative management. Based on these findings, we recommend that nonoperative management be reserved for floating injuries characterized by minimal to no displacement.

Fixation of the scapula and clavicle vs. fixation of the clavicle alone

With regard to surgical management, debate exists over whether it is necessary to fix both the clavicle and scapular neck fracture. Several authors suggest that fixation of only the clavicle allows for indirect stabilization of the scapular fracture. In 2 reports by Samy et al²⁰ and Hashiguchi et al⁹ that looked at patients treated with fixation of only the clavicle, all patients had good to excellent outcomes; however, in both studies all scapular neck fractures were minimally to nondisplaced. In a study by Rikli et al¹⁹ that evaluated 12 shoulders with fixation of only the clavicle and 1 shoulder with fixation of the clavicle and scapular fracture, the authors found a mean Constant score of 96.1 and noted that scapular fractures were sufficiently stable. However, the authors did not discuss the displacement of the scapular neck fracture and do recommend surgical fixation of displaced intra-articular scapular fractures. More recently, Gilde et al⁶ reported outcomes for 13 patients treated with clavicular fixation only and found a mean Herscovici score of 12.9, and 12 of the 13 patients in the cohort were able to return to work. However, the mean Herscovici score was higher in patients with <20 mm of glenoid medialization (12.0 vs. 13.5, respectively). With regard to fixation technique for the clavicle, one study compared titanium elastic nailing to open reduction internal fixation and did not find any significant differences. However, the authors did note poorer outcomes in patients with a preoperative GPA <30° and recommended fixation of the scapular fracture in these patients. Although some authors who support fixation of the clavicle alone state that fixation of the clavicle secondarily reduces the scapular neck fractures, in the setting of severe ligamentous injury

this is not always the case. It is reasonable that if reduction of the clavicle results in reduction of the scapular neck fracture, then the scapular neck fracture may be managed nonoperatively.

Although fixation of the clavicle alone has been shown to result in good functional outcomes, severely displaced scapular fractures may require surgical fixation. Although the authors did not make a direct comparison of fixation of the clavicle alone vs. fixation of both the clavicular and scapular fracture, Labler et al¹³ recommended scapular fixation if the fracture is displaced more than 25 mm or if the GPA is reduced to $<30^\circ$. The authors suggest that this may serve as an indirect indication of ruptured ligaments. In the randomized study by Lin et al,¹⁵ shoulders managed by fixation of both the clavicle and scapular neck fractures resulted in better Constant and DASH scores, as well as significantly shorter union time of the scapular neck than both fixation of the clavicle alone and conservative management. The authors stress that correction of the GPA to a “normal” range of 30° - 45° was only achieved by fixation of the clavicle and scapula.

Surgical indications

The lack of validated guidelines for surgical management of floating shoulder injuries leads to a heterogeneous assortment of indications used by the studies in this review. Of the 17 included studies, 8 reported the indication used to determine if patients would receive surgical management. Kim et al¹² used the same indication for primary clavicle fracture to decide on surgical intervention. Labler et al¹³ reported that the degree of scapular fracture displacement was used to determine if the patient would receive fixation of the scapula in addition to clavicular fixation. Van Noort et al²¹ found that surgical fixation of the clavicle was undertaken if there was significant displacement of both the clavicle and scapula. Similarly, Oh et al¹⁶ repaired the scapula if it remained unreduced following fixation of the clavicle. In addition to displacement criteria described by other authors, Gilde et al⁶ also pursued clavicular fixation in clavicular shortening and associated neurologic injury. Egol et al⁶ reported that patients with intra-articular glenoid fractures underwent surgery, but some of the patients received surgery because of surgeon preference. Finally, Zhou et al²⁴ established extensively detailed criteria for which patients would receive surgical treatment. It is also important to note that several authors mentioned that surgery was deferred as a result of patient condition and associated injuries. Similarly, some authors excluded patients from their cohort because of the severity of associated injuries and therefore inability to undergo surgery. The variety of indications for which patients received surgical fixation further illustrates the needs for further work and established guidelines for treatment of floating shoulder injuries.

GPA and correlation with outcomes

The GPA is used to assess the rotational malalignment of the glenoid neck and has been proposed as a measure of outcomes in floating shoulder injuries. Lin et al¹⁵ demonstrated that increased postoperative GPA was associated with increased Constant score and decreased DASH score at the 2-year follow-up. Similarly, Kim et al¹² demonstrated a positive correlation between the postoperative GPA and Constant score and found that patients with postoperative GPA $>30^\circ$ had higher Constant scores at follow-up.

The GPA has also been proposed as a tool for predicting outcomes following floating shoulder injuries. Izadapanah et al¹¹ found that patients with a preoperative GPA $<30^\circ$ had poorer outcomes in patients managed nonoperatively. Therefore, they recommend fixation of the scapula to restore the GPA in patients with preoperative GPA $<30^\circ$. Additionally, Yadav et al²³ found a negative correlation in the Herscovici score and the difference in preoperative GPA between the affected and unaffected arms; however, the correlation was not significant. GPA may not be a reliable indicator of final outcomes because it is a 2-dimensional measure that may not reflect the true angulation of the glenoid neck and that small variability in the angle of X-ray beam or patient positioning may lead to unreliable measurement.

Complications

Considering the traumatic nature in which floating shoulder injuries occur, a high rate of complications is not surprising. In patients managed nonoperatively, 21.5% had a complication secondary to the injury. Additionally, 27% of surgically managed shoulders developed a complication. The rates of complications identified in this review are similar to those reported for isolated clavicular fractures. Previous studies on complications after surgical repair of clavicular fractures have reported complication rates ranging from 14.5%-35%.^{1,2,5,8}

Limitations

There are several limitations to this study. First, the quality of this study is limited by the quality of the studies included in the review. Although some of the studies included were of a high level of evidence, the majority are retrospective case series with small numbers of patients secondary to the frequency of this injury pattern. Additionally, the variability in reported outcome measures makes meaningful comparison between studies challenging. To address this, we summarized the findings as a “percentage of the ideal maximum score.” Furthermore, because of the presence of multiple confounding variables among the included studies such as patient selection criteria, definition of floating shoulder, and data reporting among others, there was not enough homogeneous data to conduct a meta-analysis to detect statistically significant differences between different

treatment methods. Finally, selection bias may have been present in several studies in which concomitant injuries and the health status of the patient may have played into whether the patient received surgical or nonoperative treatment.

Conclusion

Floating shoulder injuries are uncommon injuries, with significant debate regarding management strategies. Overall outcomes are satisfactory despite the high-energy mechanisms leading to such injuries. Both nonoperative and surgical management appear to provide satisfactory outcomes when appropriately individualized to the patient. Surgical fixation of both the clavicle and scapula neck fracture results in better outcomes in severely displaced scapular neck fractures. Although the exact amount of displacement is still unknown, 20–25 mm appears to represent significant displacement. In the case of minimally displaced fractures, both nonoperative and surgical fixation of the clavicle alone appear to provide good outcomes. There is high-level evidence that fixation of the clavicle results in better outcomes; however, when patient condition precludes surgical management, nonoperative treatment of minimally displaced fractures also results in satisfactory outcomes. Further large-volume, multicenter, randomized studies are needed to help determine the optimal treatment strategy for patients with floating shoulder injuries.

Disclaimer

Brent Ponce is a consultant for Tornier and receives royalties from Wright Medical Group, Inc.

Jon Quade is a paid consultant for Smith and Nephew.

The other authors, their immediate families, and any research foundations with which they are affiliated have not received any financial payments or other benefits from any commercial entity related to the subject of this article.

References

- Asadollahi S, Hau RC, Page RS, Richardson M, Edwards ER. Complications associated with operative fixation of acute midshaft clavicle fractures. *Injury* 2016;47:1248-52. <https://doi.org/10.1016/j.injury.2016.02.005>
- Bostman O, Manninen M, Pihlajamaki H. Complications of plate fixation in fresh displaced midclavicular fractures. *J Trauma* 1997;43:778-83.
- Edwards SG, Wood GW 3rd, Whittle AP. Factors associated with Short Form-36 outcomes in nonoperative treatment for ipsilateral fractures of the clavicle and scapula. *Orthopedics* 2002;25:733-8.
- Egol KA, Connor PM, Karunakar MA, Sims SH, Bosse MJ, Kellam JF. The floating shoulder: clinical and functional results. *J Bone Joint Surg Am* 2001;83:1188-94.
- Fridberg M, Ban I, Issa Z, Krashenninikoff M, Troelsen A. Locking plate osteosynthesis of clavicle fractures: complication and reoperation rates in one hundred and five consecutive cases. *Int Orthop* 2013; 37:689-92. <https://doi.org/10.1007/s00264-013-1793-9>
- Gilde AK, Hoffmann MF, Sietsema DL, Jones CB. Functional outcomes of operative fixation of clavicle fractures in patients with floating shoulder girdle injuries. *J Orthop Traumatol* 2015;16:221-7. <https://doi.org/10.1007/s10195-015-0349-8>
- Goss TP. Double disruptions of the superior shoulder suspensory complex. *J Orthop Trauma* 1993;7:99-106.
- Grassi FA, Tajana MS, D'Angelo F. Management of midclavicular fractures: comparison between nonoperative treatment and open intramedullary fixation in 80 patients. *J Trauma* 2001;50:1096-100.
- Hashiguchi H, Ito H. Clinical outcome of the treatment of floating shoulder by osteosynthesis for clavicular fracture alone. *J Shoulder Elbow Surg* 2003;12:589-91. [https://doi.org/10.1016/s1058-2746\(03\)00179-4](https://doi.org/10.1016/s1058-2746(03)00179-4)
- Herscovici D Jr, Fiennes AG, Allgower M, Ruedi TP. The floating shoulder: ipsilateral clavicle and scapular neck fractures. *J Bone Joint Surg Br* 1992;74:362-4.
- Izadpanah K, Jaeger M, Maier D, Kubosch D, Hammer TO, Sudkamp NP. The floating shoulder—clinical and radiological results after intramedullary stabilization of the clavicle in cases with minor displacement of the scapular neck fracture. *J Trauma Acute Care Surg* 2012;72:E8-13.
- Kim KC, Rhee KJ, Shin HD, Yang JY. Can the glenopolar angle be used to predict outcome and treatment of the floating shoulder? *J Trauma* 2008;64:174-8. <https://doi.org/10.1097/01.ta.0000240982.99842.b9>
- Labler L, Platz A, Weishaupt D, Trentz O. Clinical and functional results after floating shoulder injuries. *J Trauma* 2004;57:595-602. <https://doi.org/10.1097/01.ta.0000105883.79994.ab>
- Leung KS, Lam TP. Open reduction and internal fixation of ipsilateral fractures of the scapular neck and clavicle. *J Bone Joint Surg Am* 1993;75:1015-8.
- Lin TL, Li YF, Hsu CJ, Hung CH, Lin CC, Fong YC, et al. Clinical outcome and radiographic change of ipsilateral scapular neck and clavicular shaft fracture: comparison of operation and conservative treatment. *J Orthop Surg Res* 2015;10:9. <https://doi.org/10.1186/s13018-014-0141-0>
- Oh W, Jeon IH, Kyung S, Park C, Kim T, Ihn C. The treatment of double disruption of the superior shoulder suspensory complex. *Int Orthop* 2002;26:145-9. <https://doi.org/10.1007/s00264-001-0325-1>
- Pailhes RG, Bonnevalle N, Laffosse J, Tricoire J, Cavaignac E, Chiron P. Floating shoulders: clinical and radiographic analysis at a mean follow-up of 11 years. *Int J Shoulder Surg* 2013;7:59-64. <https://doi.org/10.4103/0973-6042.114230>
- Ramos L, Mencia R, Alonso A, Ferrandez L. Conservative treatment of ipsilateral fractures of the scapula and clavicle. *J Trauma* 1997;42: 239-42.
- Rikli D, Regazzoni P, Renner N. The unstable shoulder girdle: early functional treatment utilizing open reduction and internal fixation. *J Orthop Trauma* 1995;9:93-7.
- Samy MA, Darwish AE. Fixation of clavicle alone in floating shoulder injury: functional and radiological outcome. *Acta Orthop Belg* 2017; 83:292-6.
- van Noort A, te Slaa RL, Marti RK, van der Werken C. The floating shoulder. A multicentre study. *J Bone Joint Surg Br* 2001;83:795-8.
- Williams GR Jr, Naranja J, Klimkiewicz J, Karduna A, Iannotti JP, Ramsey M. The floating shoulder: a biomechanical basis for classification and management. *J Bone Joint Surg Am* 2001;83:1182-7.
- Yadav V, Khare GN, Singh S, Kumaraswamy V, Sharma N, Rai AK, et al. A prospective study comparing conservative with operative treatment in patients with a “floating shoulder” including assessment of the prognostic value of the glenopolar angle. *Bone Joint J* 2013;95-B:815-9. <https://doi.org/10.1302/0301-620x.95b6.31060>
- Zhou Q, Chen B, Zho Y, Chen H, Wang Z, Liu J. Comparisons of shoulder function after treatment of floating shoulder injuries with different methods. *Biomed Res* 2017;28:2320-6.