



■ ASPECTS OF CURRENT MANAGEMENT

The floating shoulder

B. D. Owens,
T. P. Goss

*From Keller Army
Hospital, West Point,
New York, USA*

The floating shoulder is defined as ipsilateral fractures of the midshaft of the clavicle and the neck of the glenoid. This rare injury can be difficult to manage without a thorough understanding of the complex anatomy of the shoulder girdle. Surgical intervention needs to be considered for all of these injuries. While acceptable results can be expected with non-operative management of minimally-displaced fractures, displacement at one or both sites is best managed with surgical reduction and fixation.

The 'floating shoulder' is a rare injury consisting of ipsilateral fractures of the clavicle and glenoid neck. It was first described by Ganz and Noesberger in 1975.¹ Subsequently, Goss² expanded on their definition by describing it as a 'double disruption' of the superior shoulder suspensory complex. An understanding of the anatomy and biomechanics of the superior shoulder suspensory complex is essential to successful treatment. We review the current state of knowledge of the diagnosis, management and outcome of this injury.

Anatomy and biomechanics

The superior shoulder suspensory complex is, essentially, a bone and soft-tissue ring secured to the trunk by superior and inferior bony struts (Fig. 1) from which the upper extremity is suspended. The ring is composed of the glenoid process, coracoid process, coracoclavicular ligament, distal clavicle, acromioclavicular joint, and acromial process. The superior strut is the middle third of the clavicle, while the inferior strut is the junction of the most lateral portion of the scapular body and the most medial portion of the glenoid neck. The complex can be subdivided into three units: 1) the clavicular-acromioclavicular joint-acromial strut; 2) the three-process-scapular body junction; and 3) the clavicular-coracoclavicular ligamentous-coracoid (C-4) linkage (Fig. 2). Secondary support is provided by the coracoacromial ligament.

The superior shoulder suspensory complex is extremely important biomechanically. Each of its components has its own individual functions, it serves as a point of attachment for a variety of musculotendinous and ligamentous

structures, it allows limited, but significant movement to occur through the coracoclavicular ligament and the acromioclavicular articulation, and it maintains a normal, stable relationship between the upper extremity and the axial skeleton. It should be appreciated that the clavicle is the only bony connection between the upper extremity and the axial skeleton. The scapula is 'hung' or suspended from the clavicle by the coracoclavicular ligaments and the acromioclavicular joint.

The double disruption concept allows one to understand a variety of troublesome injuries of the shoulder, which have previously been described in isolation, but which may be united by a single biomechanical theory. It also has a predictive value for rarely encountered injuries.² When the complex is disrupted in two places (a double disruption), the integrity of the superior shoulder suspensory complex is breached and a potentially unstable anatomical situation is created. If significant displacement occurs at either or both sites, there may be problems with healing, such as delayed union, malunion, and nonunion, as well as adverse long-term functional difficulties, such as subacromial impingement, weakness and discomfort due to muscle fatigue, neurovascular compromise from a drooping shoulder, and degenerative joint disease, depending on the nature of the particular injury.³

The floating shoulder is one such double disruption. Williams et al⁴ conducted a cadaver study to determine the stability afforded by specific structures. Using a model with ipsilateral glenoid neck and clavicular fractures, they found that instability of the glenoid segment occurred only if the coracoacromial and

■ B. D. Owens, MD,
Orthopaedic Surgeon
Keller Army Hospital, West
Point, New York 10996, USA.

■ T. P. Goss, MD, Professor of
Orthopaedic Surgery
University of Massachusetts
Medical School, 55 Lake
Avenue North, Worcester,
Massachusetts 01655, USA.

Correspondence should be sent
to Dr B. D. Owens; e-mail:
b.owens@us.army.mil

©2006 British Editorial Society
of Bone and Joint Surgery
doi:10.1302/0301-620X.88B11.
17997 \$2.00

J Bone Joint Surg [Br]
2006;88-B:1419-24.

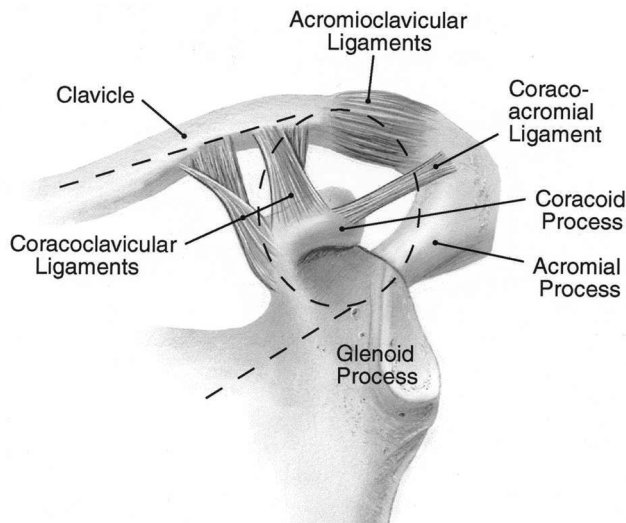


Fig. 1a

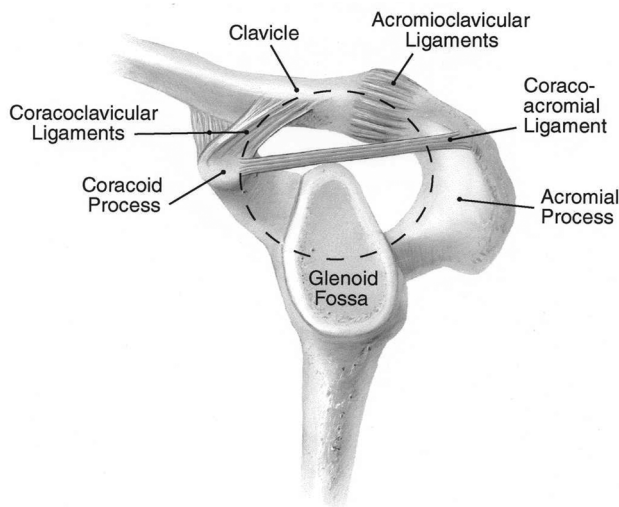


Fig. 1b

Diagram of the superior shoulder suspensory complex showing a) an anteroposterior view of the bony soft-tissue ring and the superior and inferior bony struts and b) a lateral view of the bony soft-tissue ring (from Goss TP. Fractures of the scapula. In: Rockwood CA, Matsen FA, Wirth MA, Lippitt SB, eds. *The shoulder*. Third ed. Philadelphia: Saunders, 2004:413 (reproduced with permission)).

acromioclavicular ligaments were divided. They concluded that the floating shoulder only becomes unstable when there is an associated disruption of these ligaments. The study by Williams et al⁴ is the only cadaver study of floating shoulder injuries and the interpretation of its results is controversial.

Diagnosis

A high index of suspicion for complex injury patterns is necessary when assessing patients with injuries of the shoulder girdle. Ipsilateral midshaft clavicle and glenoid neck

fractures can usually be diagnosed radiologically with routine shoulder views (a true anteroposterior (AP) of the shoulder with the arm in neutral rotation, a true axillary view of the glenohumeral joint, a true lateral scapular view, and if necessary weight-bearing films). Routine CT scans and three-dimensional reconstructions can help to define the exact nature of the bony injury. Both plain films and scans should be examined for changes suggestive of ligamentous disruption. McAdams et al,⁵ found that CT scans were no better than plain films in the evaluation of glenoid neck fractures but did help in the identification of associated injuries to the superior shoulder suspensory complex. Associated injuries to adjacent and distant bony and soft-tissue structures are often present and may affect the outcome accordingly.^{6,7} These injuries are often the result of high-energy trauma, and concomitant ipsilateral upper extremity, shoulder girdle and thoracic injuries are common. It is often these injuries and their recovery that influence the overall outcome from the floating shoulder injury.

Surgical indications

A floating shoulder represents a double disruption of the superior shoulder suspensory complex. In isolation, each fracture is generally minimally-displaced and can be managed non-operatively. In combination, however, each disruption can make the other unstable, for example, the glenoid neck fracture may increase the displacement of the clavicular fracture site and *vice versa*. The resultant instability will be greater if there is additional disruption of the clavicular-acromioclavicular joint-acromial strut or coracoacromial ligament, or if the C-4 linkage is violated (Fig. 3).

Hardegger, Simpson and Weber⁸ felt that these injuries represented a "functional imbalance" owing to the "altered glenohumeral-acromial relationships". By changing the relationships between anatomic structures, muscular forces are altered, resulting in functional difficulty. Hardegger et al⁸ and Butters⁹ recommended surgery in these cases. Reduction and stabilisation of the clavicular fracture by screw/plate fixation is advisable if the displacement is unacceptable. It reduces the risk of nonunion, alleviates tension on the brachial plexus, restores normal anatomical relationships, and ensures the restoration of normal shoulder function.^{10,11} The fracture of the glenoid neck will often reduce and stabilise as a result. However, if significant displacement persists, it should be reduced and fixed.^{12,13} Additional injuries of the clavicular-acromioclavicular joint-acromial strut may also require operative treatment, whereas associated injuries of the coracoacromial ligament and the C-4 linkage will usually heal satisfactorily if the fracture sites of the glenoid neck and clavicle are treated appropriately.

The amount of displacement that is acceptable at the fracture sites of the glenoid neck and clavicle is controversial. Fractures of the clavicle have traditionally been treated non-operatively, unless their displacement is severe.¹⁴ Recent reports, however, have suggested that displacement

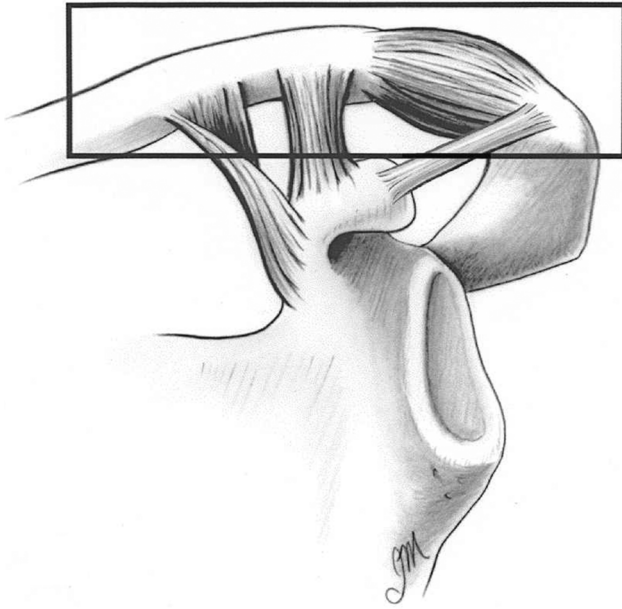


Fig. 2a

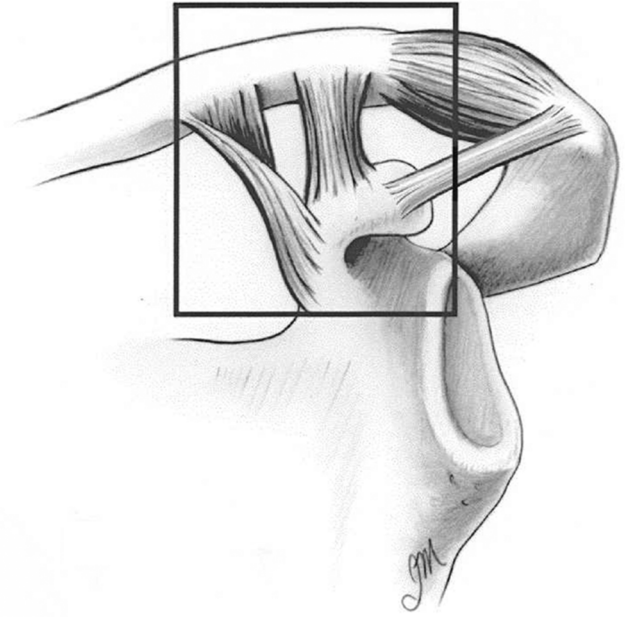


Fig. 2b

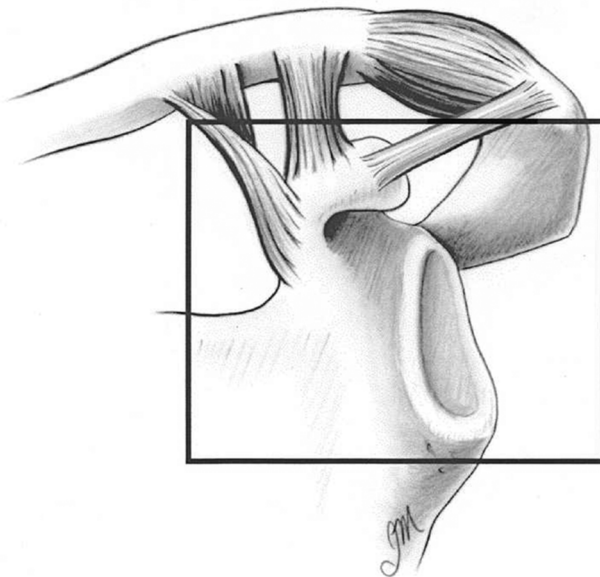


Fig. 2c

The three components of the superior shoulder suspensory complex showing a) the clavicular-acromioclavicular joint-acromial strut, b) the clavicular-coracoclavicular ligamentous-coracoid (C-4) linkage and c) the three process-scapular body junction (from **Goss TP**. Fractures of the scapula. In: Rockwood CA, Matsen FA, Wirth MA, Lippitt SB, eds. *The shoulder*. Third ed. Philadelphia: Saunders, 2004:413 (reproduced with permission)).

previously thought acceptable can result in nonunion or malunion and a poor outcome.¹⁵⁻¹⁹ Wick et al¹⁸ found that shortening of 2 cm or more of a middle-third fracture of the clavicle is a risk factor for nonunion. McKee et al¹⁶ reported a series of 15 patients with middle third clavicular malunions treated successfully by surgery. These injuries had united in a shortened position (mean 2.9 cm) resulting in pain, weakness, and neurological symptoms.¹⁶ Hill, McGuire and Crosby²⁰ found that an initial fracture shortening of 2 cm or more was the only significant risk factor for nonunion in a series of 52 middle-third fractures of the

clavicle. Based upon this recent data, operative fixation has been recommended for middle-third fractures that are shortened by 2 cm or more. Middle third fractures in which the fragments either lack cortical apposition and/or are comminuted may also have a poor outcome. The precise amount of displacement and comminution needed has not been determined. Nordqvist, Peterssen and Redlund-Johnell²¹ reported the long-term outcome of 225 conservatively-treated middle-third fractures of the clavicle and found an increased rate of malunion, nonunion, and poorer functional results in displaced fractures and comminuted

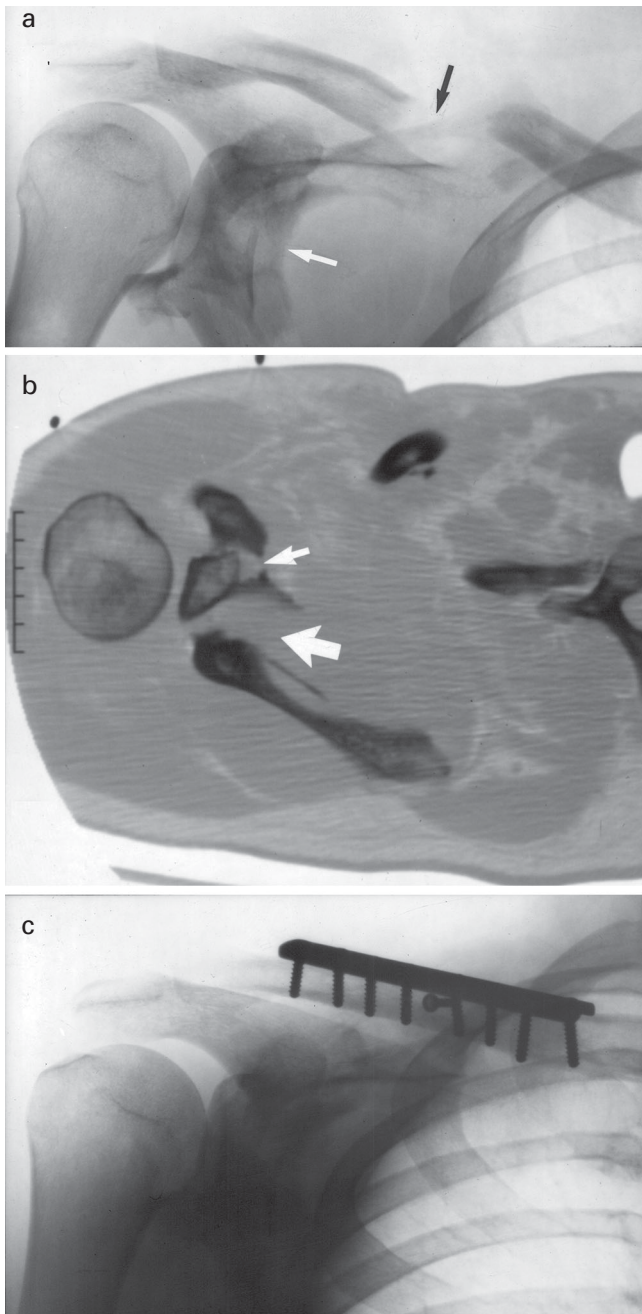


Fig. 3

Radiographs and CT scan showing a double disruption of the superior shoulder suspensory complex resulting in a floating shoulder. a) a pre-operative anteroposterior view showing a fracture of the glenoid neck with medial translation (white arrow) and a severely-displaced fracture of the middle-third of the clavicle (black arrow), b) a pre-operative axial CT image showing the fracture of the superior shoulder suspensory complex to be complete (large white arrow), with the glenoid fragment and the entire superior shoulder suspensory complex rendered particularly unstable by an associated fracture of the coracoid process (small white arrow), and c) a post-operative anteroposterior radiograph showing anatomical reduction and stabilisation of the fracture of the clavicle. The fracture of the glenoid neck was managed non-operatively, although a strong case could have been made for internal fixation in light of its persistent medial displacement (the glenoid fragment remained unstable due to the fractured coracoid process; a double disruption of the superior shoulder suspensory complex was still present) (from Goss TP. Fractures of the scapula: diagnosis and treatment. In: Iannotti JP, Williams GR Jr eds. *Disorders of the shoulder: diagnosis and management*. Philadelphia: Lippincott Williams & Wilkins, 1999:624 (reproduced with permission)).

fractures, compared with those that maintained cortical apposition. In a prospective analysis of 581 conservatively-treated middle third fractures, Robinson et al¹⁷ noted an increased risk of nonunion in those that either lacked cortical apposition or were comminuted. Zlowodzki et al¹⁹ performed a meta-analysis of studies of middle-third fractures of the clavicle and concluded that both displacement (relative risk (RR) = 2.3) and comminution (RR = 1.4) resulted in an increased risk of nonunion. Based upon this data, surgery should be considered for middle-third fractures of the clavicle that lack any cortical apposition and/or are severely comminuted. In a floating shoulder, the further destabilising effect of a fracture of the glenoid neck makes operative fixation imperative.

Other indications for operative fixation include open fractures requiring surgical irrigation and debridement, fractures compromising the overlying skin (an impending open fracture), and middle-third fractures in patients with multiple injuries in order to facilitate their care and rehabilitation.²²

Fractures of the glenoid neck can be classified in two ways. The first describes the position of the fracture in relation to the coracoid process.²³ Fractures medial to the coracoid process are surgical neck fractures (the most common injury pattern), while fractures lateral to the coracoid process are anatomical neck fractures. The latter are highly unstable, as there is no attachment of the glenoid fragment to the clavicular-acromioclavicular joint-acromial strut via the C-4 linkage, and often require surgical management.^{8,24}

The second method is based upon the degree of displacement at the fracture site.²³ Type I fractures according to the system of Goss²³ are insignificantly displaced and constitute more than 90% of cases. Their management is non-operative, and a good to excellent functional result can be expected. Type II fractures are significantly displaced, as defined by translational displacement of the glenoid fragment by 1 cm or more and/or angulatory displacement of the fragment of 40° or more in either the coronal or sagittal plane.²³ These injuries, whether involving the surgical or anatomical neck, should at least be considered for open reduction and stabilisation.

Surgical technique

Operations on the floating shoulder require wide access to the entire shoulder girdle. The patient is placed in the lateral decubitus position or in the 'deck chair' position. Care must be taken to allow adequate exposure of the scapula and clavicle. The shoulder girdle and whole upper limb are prepped and draped. Alternatively, if the surgeon prefers, a staged procedure can be performed using separate positions, sterile preparations, and exposures.

The order of fixation is debatable and remains at the discretion of the surgeon. Initial fixation of the clavicle may allow indirect reduction of the glenoid segment and obviate the need for a posterior procedure. If significant displacement persists, however, the fracture of the glenoid must also

Table I. Published results of floating shoulder injuries

| | Number of floating shoulders | Treatment | | Outcome |
|----------------------------------|------------------------------|--------------|--------------------------|---|
| | | Conservative | Fixation of the clavicle | |
| Herscovici et al ¹⁰ | 9 | 2 | 7 | 1 good, 1 poor, 7 excellent |
| Leung and Lam ²⁷ | 15 | | | Mean Rowe = 84 |
| Rikli et al ²⁸ | 12 | | 11 | Mean Constant = 96% age-matched norms |
| Ramos et al ³³ | 13 | 13 | 1 | 11 excellent, 1 good, 1 fair (Herscovici score ¹⁰) |
| Edwards et al ³² | 20 | 20 | | Mean Rowe = 95 Mean Constant = 96 |
| Low and Lam ³⁴ | 4 | | 4 | Rowe 70 to 100 |
| van Noort et al ³⁰ | 35 | 28 | | Mean Constant = 76 Mean Constant = 71 |
| Oh et al ³⁵ | 11 | 3 | | Mean Rowe = 77 Mean Rowe = 88 Mean Rowe = 90 |
| Hagino et al ³⁶ | 1 | | 1 | "acceptable" |
| Hashiguchi and Ito ²⁹ | 5 | | 5 | Mean UCLA = 34.2/35 |
| Labler et al ⁷ | 17 | 8 | 6 | Mean Constant = 90 Mean Constant = 66 (includes 2 patients with brachial plexus palsies) Mean Constant = 93 |
| Egol et al ³¹ | 19 | 12 | | Mean American Society of Elbow and Shoulder surgery (ASES) score = 80.2 Mean ASES = 88.7 |

be addressed.²³ Conversely, fixation of the displaced glenoid segment may be deemed more important and can be carried out first, followed by open reduction and internal fixation of the fracture of the clavicle if necessary.

The clavicle is approached through an incision directly over its subcutaneous border. Care must be taken to identify and protect the adjacent neurovascular structures. The fracture site is exposed subperiosteally both proximally and distally then reduced and stabilised using a standard plate and screws. Intramedullary devices, precontoured plates, and locking plates may be preferred in certain situations, such as severe comminution, osteoporotic bone, or surgeon preference.

The glenoid neck is approached posteriorly. The posterior deltoid is either split in the line of its fibres or detached at its origin and retracted distally. The interval between infraspinatus and teres minor is developed to expose the posteroinferior glenoid neck and lateral border of the scapula. A superior approach can be added to control the free glenoid fragment. Once a satisfactory reduction has been achieved, temporary fixation can be achieved by passing K-wires through the glenoid fragment into adjacent bony structures (for example, through the glenoid fragment and into the scapular body, or through the acromial process into the glenoid fragment). Definitive fixation is generally achieved by means of a contoured 3.5 mm reconstruction plate applied along the lateral border of the scapula and the posterior aspect of the glenoid process. Additional fixation can be provided by K-wires or lag screws. The K-wires providing temporary fixation can be retained or used for the placement of 3.5 mm cannulated lag screws.^{25,26} In some cases, comminution of the scapular body and spine may be

so severe, or the size of the glenoid fragment so small, as to preclude plate fixation. Under these circumstances, it may only be possible to fix the reduced glenoid fragment to the adjacent intact bony structures, such as the acromial process or the distal clavicle with K-wires or lagged screws.

Published results

Leung and Lam²⁷ described 15 patients with a mean follow-up of 25 months, in which 14 fractures healed with a good or excellent functional result. Herscovici et al¹⁰ described nine patients with ipsilateral fractures of the clavicle and glenoid neck who were followed up for a mean of 48.5 months. Seven were treated with plate fixation of the fracture of the clavicle and achieved an excellent result. Two were treated conservatively and had a decreased range of movement as well as drooping of the involved shoulder. The authors strongly recommended open reduction and internal fixation of the clavicle to prevent malunion of the glenoid neck.

Rikli, Regazzoni and Renner²⁸ expanded this concept, stating that a fracture of the glenoid neck with either an associated fracture of the clavicle or a disruption of the acromioclavicular joint or sternoclavicular (SC) joint results in an "unstable shoulder girdle". They reviewed 12 patients in whom the clavicular injury was surgically stabilised and reported mostly excellent results.

Hashiguchi and Ito²⁹ reported excellent results in five patients with ipsilateral fractures of the clavicle and glenoid neck, for whom only fixation of the clavicle was performed.

Van Noort et al³⁰ reported a multicentre study of 35 patients with ipsilateral fractures of the clavicle and glenoid neck treated both operatively and non-operatively, with

mixed results in both groups. They reported a mean Constant score of 76 (30 to 100) in the conservatively-treated group and a mean score of 71 (43 to 100) in the surgically-treated group. However, they included three patients in the surgically-treated group who had failed conservative management and required surgery for clavicular nonunion (1) or malunion (2).

Egol et al³¹ described 19 patients, some of whom were treated surgically based on surgeon's preference and some conservatively and reported good results with each approach.

Edwards, Whittle and Wood³² reported excellent results with conservative treatment in 20 consecutive patients with ipsilateral fractures of the clavicle and scapula. However, in five patients, the fracture of the scapula did not involve the glenoid neck and only five glenoid fractures were displaced more than 5 mm. Ramos et al³³ described 13 patients who were treated non-operatively. Results were classified according to the criteria of Herscovici et al¹⁰ and 11 were excellent, one good and one fair.

It is difficult to interpret the published results (Table I).^{7,10,29-36} The studies consist of small numbers of patients treated over a long period of time. They report the results obtained by many surgeons using a variety of techniques. There was also significant variability in the degree of complexity of the shoulder injuries as well as in the general condition of these multiply-injured patients. Finally, these studies use a variety of different outcome measures, many of which are unvalidated.

With all of this in mind, it seems reasonable to conclude that surgical intervention should at least be considered for all floating shoulder injuries. Acceptable results can be expected for patients with minimally-displaced fractures treated non-operatively. Significant displacement at one or both fracture sites can result in a poor functional outcome which can be improved with surgical intervention.

Operative fixation of the clavicle alone can indirectly reduce the displaced fracture of the glenoid neck satisfactorily. However, open reduction and internal fixation of the second site must be performed if significant displacement persists.

In future, further thought must be given to the evaluation of associated ligament disruptions, and larger, controlled, multicentre trials will need to be undertaken.

References

1. Ganz R, Noesberger B. Treatment of scapular fractures. *Hefte Unfallheilkd* 1975;126:59-62 (in German).
2. Goss TP. Double disruptions of the superior shoulder complex. *J Orthop Trauma* 1993;7:99-106.
3. Goss TP. Scapular fractures and dislocation: diagnosis and treatment. *J Am Acad Orthop Surg* 1995;3:22-33.
4. Williams GR Jr, Naranja J, Klimkiewicz J, et al. The floating shoulder: a biomechanical basis for classification and management. *J Bone Joint Surg [Am]* 2001;83-A:1182-7.

5. McAdams TR, Blevins FT, Martin TP, De Coster TA. The role of plain films and computed tomography in the evaluation of scapular neck fractures. *J Orthop Trauma* 2002;16:7-11.
6. Goss TP. Fractures of the scapula: diagnosis and treatment. In: Iannotti JP, Williams GR, eds. *Disorders of the shoulder: diagnosis and management*. Philadelphia: Lippincott Williams & Wilkins, 1999:597-637.
7. Labler L, Platz A, Weishaupt D, Trentz O. Clinical and functional results after floating shoulder injuries. *J Trauma* 2004;57:595-602.
8. Hardegger FH, Simpson LA, Weber BG. The operative treatment of scapular fractures. *J Bone Joint Surg [Br]* 1984;66-B:725-31.
9. Butters KP. The scapula. In: Rockwood CA, Matsen FA, eds. *The shoulder*. Philadelphia: WB Saunders, 1990:335-66.
10. Herscovici D Jr, Fiennes AG, Allgower M, Ruedi TP. The floating shoulder: ipsilateral clavicle and scapular neck fractures. *J Bone Joint Surg [Br]* 1992;74-B:362-4.
11. Kumar VP, Satku K. Fractures of the clavicle and scapular neck. *J Bone Joint Surg [Br]* 1993;75-B:509.
12. Herscovici F. Open reduction and internal fixation of ipsilateral fractures of the scapular neck and clavicle (letter). *J Bone Joint Surg [Am]* 1994;76-A:1112.
13. Leung K, Lam T. Correspondence. *J Bone Joint Surg [Am]* 1994;76-A:1112-13.
14. Denard PJ, Koval KJ, Cantu RV, Weinstein JN. Management of midshaft clavicle fractures in adults. *Am J Orthop* 2005;34:527-36.
15. McKee MD, Pedersen EM, Jones C, et al. Deficits following nonoperative treatment of displaced clavicular fractures. *J Bone Joint Surg [Am]* 2006;88-A:35-40.
16. McKee MD, Wild LM, Schemitsch EH. Midshaft malunions of the clavicle. *J Bone Joint Surg [Am]* 2003;85-A:790-7.
17. Robinson CM, Court-Brown CM, McQueen MM, Wakefield AE. Estimating the risk of nonunion following nonoperative treatment of a clavicular fracture. *J Bone Joint Surg [Am]* 2004;86-A:1359-65.
18. Wick M, Muller EJ, Kollig E, Muhr G. Midshaft fractures of the clavicle with a shortening of more than 2 cm predispose to nonunion. *Arch Orthop Trauma Surg* 2001;121:207-11.
19. Zlowodzki M, Zelle BA, Cole PA, et al. Treatment of acute midshaft clavicle fractures: systematic review of 2144 fractures. *J Orthop Trauma* 2005;19:504-7.
20. Hill JM, McGuire MH, Crosby LA. Closed treatment of displaced middle-third fractures of the clavicle gives poor results. *J Bone Joint Surg [Br]* 1997;79-B:537-9.
21. Nordqvist A, Petersson CJ, Redlund-Johnell I. Mid-clavicle fractures in adults: end result study after conservative treatment. *J Orthop Trauma* 1998;12:572-6.
22. Basamania CJ, Craig EV, Rockwood CA Jr. Fractures of the clavicle. In: Rockwood CA, Matsen FA, Wirth MA, Lippitt SB, eds. *The shoulder*. Vol. 1. Third ed. Philadelphia: Saunders, 2004:455-519.
23. Goss TP. Fractures of the glenoid neck. *J Shoulder Elbow Surg* 1994;3:42-52.
24. Arts V, Louette L. Scapula neck fractures: an update of the concept of floating shoulder. *Injury* 1999;30:146-8.
25. Goss TP. Glenoid fractures: open reduction and internal fixation. In: Wiss DA, ed. *Master techniques in orthopaedic surgery: fractures*. Philadelphia: Lippincott-Raven, 1998:3-17.
26. Owens BD, Goss TP. Surgical approaches for glenoid fractures. *Tech Shoulder Elbow Surg* 2004;5:103-15.
27. Leung KS, Lam TP. Open reduction and internal fixation of ipsilateral fractures of the scapular neck and clavicle. *J Bone Joint Surg [Am]* 1993;75-A:1015-18.
28. Rikli B, Regazzoni P, Renner N. The unstable shoulder girdle: early functional treatment utilizing open reduction and internal fixation. *J Orthop Trauma* 1995;9:93-7.
29. Hashiguchi H, Ito H. Clinical outcome of the treatment of floating shoulder by osteosynthesis for clavicle fracture alone. *J Shoulder Elbow Surg* 2003;12:589-91.
30. van Noort A, te Slaa RL, Marti RK, van der Werken C. The floating shoulder: a multicentre study. *J Bone Joint Surg [Br]* 2001;83-B:795-8.
31. Egol KA, Connor PM, Karunakar MA, et al. The floating shoulder: clinical and functional results. *J Bone Joint Surg [Am]* 2001;83-A:1188-94.
32. Edwards SG, Whittle AP, Wood GW. Nonoperative treatment of ipsilateral fractures of the scapula and clavicle. *J Bone Joint Surg [Am]* 2000;82-A:774-80.
33. Ramos L, Mencia R, Alonso A, Ferrandez L. Conservative treatment of ipsilateral fractures of the scapula and clavicle. *J Trauma* 1997;42:239-42.
34. Low CK, Lam AW. Results of fixation of clavicle alone in managing floating shoulder. *Singapore Med J* 2000;41:452-3.
35. Oh CW, Jeon IH, Kyung HS, et al. The treatment of double disruption of the superior shoulder suspensory complex. *Int Orthop* 2002;26:145-9.
36. Hagino T, Ono T, Hamada Y. Unusual double clavicle fracture complicated by ipsilateral scapular neck fracture. *J Orthop Sci* 2002;7:417-19.