



Primary Repair of the Medial Collateral Ligament with a Double Row Suture Technique and Suture Tape Augmentation for Acute Tibial-Sided Injuries

Thomas Golden, M.D., Alex M. B. Friedman, D.O., Reza Jazayeri, M.D., Brent Sanderson, D.O., and Ezra Levy, D.O.

Abstract: The management of medial collateral ligament (MCL) injuries has evolved during the past 30 years. Most heal reliably with conservative management. The treatment of MCL sprains with concomitant other ligamentous injuries continues to be controversial. Surgical management of chronic laxity of the medial structures can be quite difficult, and therefore **anatomic repair of the medial support structures in the acute setting is preferred when indicated**. Complete avulsion of the superficial and deep MCL from the tibia with disruption of the meniscal coronary ligament have a poor prognosis with non-operative treatment and may be optimally managed with acute surgical repair for improved valgus stability. A recent review demonstrated that there is a role for primary MCL repair for select patients. This technique addresses complete avulsions from the tibia, using multiple anchors for anatomic reattachment of the deep and superficial MCL, SutureBridge construct to enhance footprint compression, and suture tape to augment the MCL repair. Advantages of this technique include utilization of suture tape augmentation to allow for early range of motion, maintenance of the native MCL to preserve proprioception, and repair in the acute setting for faster recovery.

The management of medial collateral ligament (MCL) injuries has evolved during the past 30 years. Most heal reliably with conservative management.¹⁻³ The treatment of MCL sprains with concomitant other ligamentous injuries continues to be controversial. Surgical management of chronic laxity of the medial structures can be quite difficult; therefore, anatomic repair of the medial support structures in the acute setting is preferred when indicated.

Complete avulsion of the superficial and deep MCL **from the tibia** with disruption of the meniscal coronary

ligament have a poor prognosis with nonoperative treatment and may be optimally managed with acute surgical repair for improved valgus stability. A review demonstrated that there is a role for primary MCL repair for select patients.⁴ In addition, several techniques have been previously described to **address primary MCL repair with suture tape augmentation**.⁵⁻⁸ A biomechanical cadaveric study showed that suture tape augmentation may increase the strength of the MCL repair construct.⁹ This technique addresses these complete avulsions from the tibia, using multiple anchors for anatomic reattachment of the **deep and superficial MCL** as well as a **SutureBridge construct** (Arthrex, Naples, FL) to enhance footprint compression. In addition, suture tape was used to augment the MCL repair.

Surgical Technique

The patient is placed in the supine position with the operative leg prepped and draped in the usual fashion for knee arthroscopy. An examination of the patient's knee under anesthesia is important to perform to assess ligamentous laxity at both 0° and 30° while the patient is adequately relaxed.

Next, a diagnostic arthroscopy should be performed to evaluate and address intra-articular pathology. This includes a careful inspection of the medial

From the Orthopedic Surgery Residency Program, Community Memorial Health System, Ventura, California, U.S.A.

The authors report the following potential conflicts of interest or sources of funding: T.G. is on the Arthroscopy Association of North America Fellowship Committee and Communications and Technology Committee. Full ICMJE author disclosure forms are available for this article online, as [supplementary material](#).

Received September 7, 2018; accepted November 28, 2018.

Address correspondence to Thomas Golden, M.D., 147 N. Brent Street, Ventura, California 93003. E-mail: thomasgolden@mac.com

© 2019 by the Arthroscopy Association of North America. Published by Elsevier. This is an open access article under the CC BY-NC-ND license (<http://creativecommons.org/licenses/by-nc-nd/4.0/>).

2212-6287/181111

<https://doi.org/10.1016/j.eats.2018.11.018>

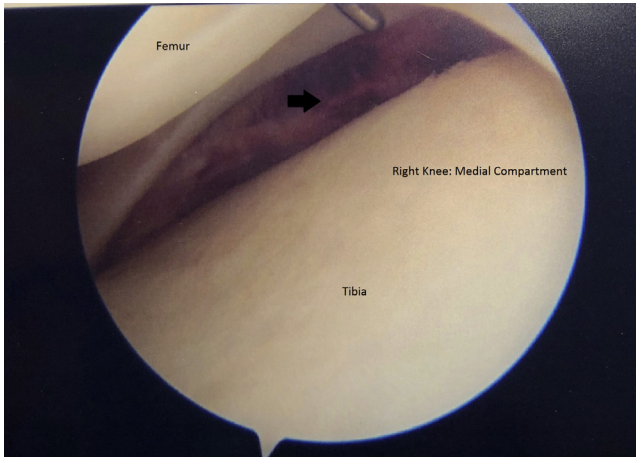


Fig 1. Arthroscopic view of the medial compartment of the right knee, demonstrating gapping between the medial meniscus and the tibia, with hemorrhage seen just inferior to the meniscus.

compartment of the knee, which may show a “drive-through” sign, indicating medial laxity. For tibial-sided injuries, when a valgus stress is applied to the knee, the medial meniscus remains reduced to the femur, and the meniscus lifts off the tibia, creating a gap between the medial meniscus and the tibial plateau. Hemorrhage inferior to the medial meniscus may also be seen in tibial-sided tears (Fig 1). Arthroscopic inspection of the posteromedial side of the knee may show evidence of injury to the posterior oblique ligament (POL) and/or the posteromedial capsule, which should be addressed during the subsequent open repair.

Attention can now be directed to the open MCL repair as demonstrated in Video 1. An incision is made from the medial femoral epicondyle to the anteromedial aspect of the proximal tibia, approximately 6 cm below the joint line. The sartorial fascia is then incised, and the muscle is reflected posteriorly protecting the saphenous nerve and exposing the MCL. Retraction of the pes anserinus tendons can be performed to further expose extent of the distal MCL insertion. The MCL will likely be attenuated, and, depending on the timing of surgery after the injury, it may be scarred to its tibial insertion. The superficial MCL should be carefully released at its distal insertion with a scalpel or periosteal elevator and carried proximally to the level of the joint line. This will expose the injured deep MCL.

Once adequate exposure is obtained, primary repair of the deep and superficial MCL can be performed. The tibial footprint of the superficial and deep MCL should be lightly decorticated, often with a rongeur. A Kracków suture technique using No. 2 FiberWire (Arthrex) is placed in the distal aspect of the MCL to aid in tissue handling and for later repair. Next, 2 double-loaded FiberTak soft anchors (Arthrex) with No. 2 FiberWire are placed approximately 1 cm distal to the joint line for reattachment of the deep MCL (Fig 2A).¹⁰ These 4 sutures are then placed in a horizontal mattress fashion through the deep and superficial MCL tissue. With the knee flexed at 30° and, applying a varus stress, they are tied with alternating half hitches, securing the deep MCL to the proximal tibia.

Moving to the femoral attachment of the MCL, a 4.75-mm PEEK SwiveLock suture anchor (Arthrex)

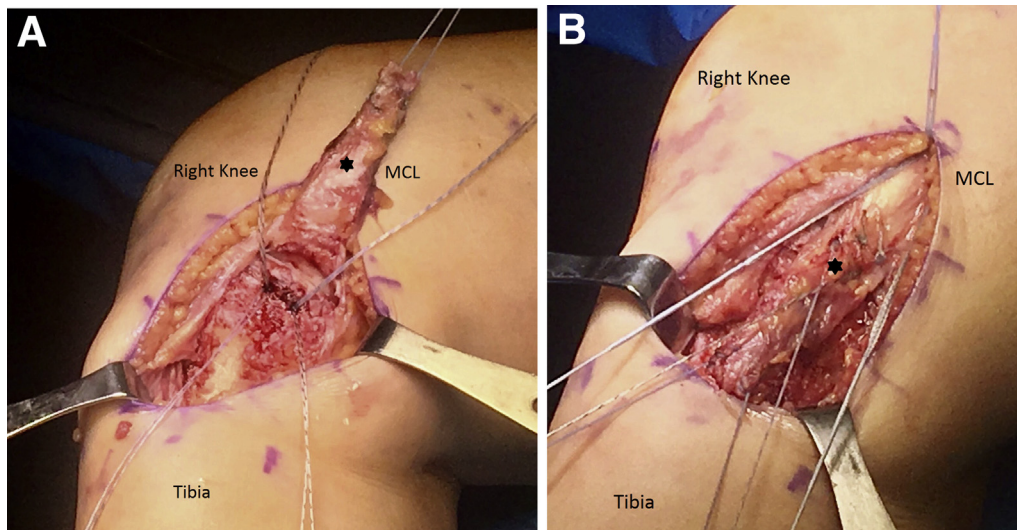
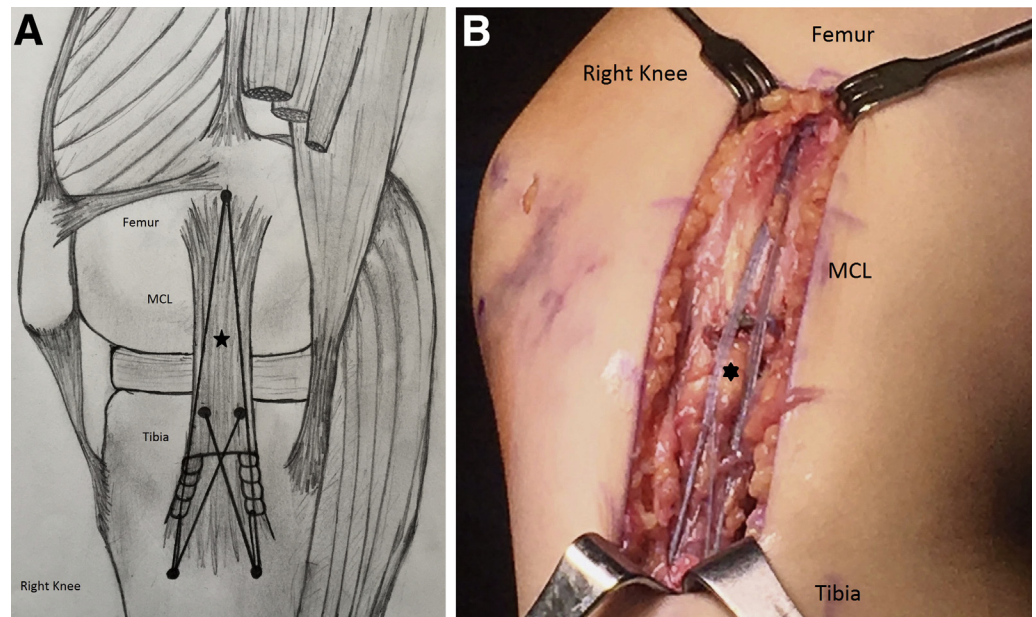


Fig 2. (A) Medial side of the right knee, demonstrating the 2 double-loaded FiberTak soft anchors 1 cm distal to the joint line. Also, observe the No. 2 FiberWire Krackow suture in the distal MCL, which has been retracted outside the wound to expose its tibial footprint. (B) Medial view of the right knee, demonstrating the 3 sutures to be placed in the 2 distal SwiveLocks. Note that only 2 strands from the FiberTak anchors (1 strand from each anchor) are brought to the distal SwiveLocks. The other strands are cut. (MCL, medial collateral ligament.)

Fig 3. (A) Medial view of the right knee of the MCL repair, SutureBridge, and suture tape augmentation construct. Note that the suture tape begins at 1 SwiveLock proximally, and inserts into 2 SwiveLocks on the tibia. (B) An intra-operative photo of the final MCL repair, SutureBridge, and suture tape augmentation construct (medial view of the right knee). (MCL, medial collateral ligament.)



loaded with FiberTape (Arthrex) is placed at the anatomic origin of the MCL just posterior and proximal to the medial epicondyle.¹⁰ These FiberTapes will be used for the suture tape augmentation (Internal Brace, Arthrex). Next, 2 4.75-mm PEEK SwiveLock suture anchors are placed at the distal insertion of the MCL, approximately 1 cm apart, just off the posterior crest of the tibia and 6 cm distal to the joint line.¹¹ Three sutures are placed in each SwiveLock anchor. These include 1 suture from the deep MCL mattress suture repair, 1 suture from the Kracków stitch in the distal aspect of the superficial MCL, and 1 limb of the FiberTape for the suture tape augmentation construct (Fig 2B). With the knee flexed to 30° and a varus stress

applied, the 6 sutures were then fixed under proper tension using the 2 SwiveLock anchors. In this process, the 2 FiberWire sutures from the deep MCL repair are crossed as in a SutureBridge pattern, allowing compression of the superficial MCL tissue on its broad tibial insertion (Fig 3 A and B). Posterior to the MCL repair, the posterior oblique ligament and capsule are inspected and plicated as indicated using figure-8 nonabsorbable sutures. The knee is then tested for range of motion and valgus stability at 0° and 30°. The sartorial fascia is then repaired using interrupted absorbable sutures, and the wound is then closed in the usual layered fashion. The pearls and pitfalls of this technique are described in Table 1.

Table 1. Surgical Pearls and Pitfalls of the MCL Repair Technique

Pearls
A thorough physical examination and an MRI scan will assist in identifying the location of MCL tears and multiligamentous injuries.
The Kracków suture placed in the distal MCL will aid in tissue handling and avoid iatrogenic damage when manipulating the MCL.
Ensure the knee is flexed at 30° with a varus stress applied when tensioning the sutures.
Placing the patient in a hinged knee brace from 0° to 90° and allowing him or her to partial weight bear immediately after surgery can help prevent stiffness and quadriceps atrophy.
Pitfalls
Overtensioning the FiberTape can lead to overconstraining the knee.
Not repairing a concomitant POL tear can lead to residual instability and valgus laxity; this should be repaired at the time of MCL repair.

MCL, medial collateral ligament; MRI, magnetic resonance imaging; POL, posterior oblique ligament.

Postoperative Course

Given the concern for knee stiffness and quadriceps atrophy, the patient is placed in a hinged knee brace set from 0° to 90° to allow for light, active range of motion.

Table 2. Advantages and Disadvantages of the Described MCL Repair Technique

Advantages
Can be performed in the acute setting.
The native MCL is retained, preserving proprioception.
The deep and superficial MCL are repaired in a layered and anatomic fashion.
ACL reconstruction can be performed at the time of MCL repair.
Suture tape augmentation protects the repair, allowing for early ROM to help prevent stiffness.
Disadvantages
This technique cannot be performed with chronic MCL tears.
Long-term outcomes using this technique have not been established.

ACL, anterior cruciate ligament; MCL, medial collateral ligament; ROM, range of motion.

Patients can be partial weight bearing with crutches for the first 2 weeks and encouraged to perform quadriceps strengthening in the brace. Following this, we allow full weight bearing in the brace set at 0° to 120°. At 6 weeks, the brace is discontinued and formal rehabilitation is progressed.

Discussion

This technique uses an anatomic repair of the MCL that incorporates a **SutureBridge construct with suture tape augmentation to protect the repair**. This repair can be used for acute, **tibial-sided MCL tears** to provide more predictable results both in isolated MCL and multiligament injuries. In combined anterior cruciate ligament (ACL) and MCL injuries, repairing the MCL at the time of ACL reconstruction or repair can decrease the overall recovery time because patients do not need to wait for their MCL to heal before their ACL surgery.¹² Other advantages of primary repair with suture tape augmentation are early mobilization to help prevent muscle atrophy and stiffness, more predictable results with prevention of residual valgus instability, and retaining native tissue to help maintain proprioception (Table 2).

One risk of this technique is overconstraining the knee by overtensioning the suture tape augmentation, which could lead to residual stiffness following the repair. This can be prevented, however, by tensioning the construct at 30° of flexion with a gentle varus force applied. One limitation of this technique is it should not be done for chronic MCL tears, and should ideally be performed in the acute setting. In addition, more long-term studies are needed to better assess the long-term outcomes and efficacy of primary MCL repair using this SutureBridge and suture tape augmentation construct.

References

1. Woo SL-Y, Vogrin TM, Abramowitch SD. Healing and repair of ligament injuries in the knee. *J Am Acad Orthop Surg* 2000;8:364-372.
2. Miyamoto RG, Bosco JA, Sherman OH. Treatment of medial collateral ligament injuries. *J Am Acad Orthop Surg* 2009;17:152-161.
3. Tandogan NR, Kayaalp A. Surgical treatment of medial knee ligament injuries: Current indications and techniques. *EFORT Open Rev* 2016;1:27-33.
4. DeLong JM, Waterman BR. Surgical repair of medial collateral ligament and posteromedial corner injuries of the knee: A systematic review. *Arthroscopy* 2015;31:2249-2255.
5. Mackay GM, Blyth MJ, Anthony I, Hopper GP, Ribbans WJ. A review of ligament augmentation with the Internal Brace: The surgical principle is described for the lateral ankle ligament and ACL repair in particular, and a comprehensive review of other surgical applications and techniques is presented. *Surg Technol Int* 2015;26:239-255.
6. Lubowitz JH, MacKay G, Gilmer B. Knee medial collateral ligament and posteromedial corner anatomic repair with internal bracing. *Arthrosc Tech* 2014;3:e505-e508.
7. List JP, DiFelice GS. Primary repair of the medial collateral ligament with internal bracing. *Arthrosc Tech* 2017;6:e933-e937.
8. Trofa DP, Sonnenfeld JJ, Song DJ, Lynch TS. Distal knee medial collateral ligament repair with suture augmentation. *Arthrosc Tech* 2018;7:e921-e926.
9. Gilmer BB, Crall T, DeLong J, Kubo T, Mackay G, Jani SS. Biomechanical analysis of internal bracing for treatment of medial knee injuries. *Orthopedics* 2016;39:e532-e537.
10. LaPrade MD, Kennedy MI, Wijdicks CA, LaPrade RF. Anatomy and biomechanics of the medial side of the knee and their surgical implications. *Sports Med Arthrosc Rev* 2015;23:63-70.
11. LaPrade RF, Engebretsen AH, Ly TV, Johansen S, Wentorf FA, Engebretsen L. The anatomy of the medial part of the knee. *J Bone Joint Surg Am* 2007;89:2000-2010.
12. Bollier M, Smith P. Anterior cruciate ligament and medial collateral ligament injuries. *J Knee Surg* 2014;27:359-368.