

# THE OPEN PALM TECHNIQUE IN DUPUYTREN'S CONTRACTURE

By CHARLES R. McCASH, Ch.M., F.R.C.S.E.  
*Roehampton Plastic Surgery Centre, London*

IN 1833 Baron Dupuytren laid down the essential principles in the operative treatment of the disease which bears his name. These were as follows :—

1. Transverse incisions in the skin creases.
2. Division of the fascial bands responsible for the contracture.
3. Splinting of the fingers in extension for four weeks after the operation.
4. Wounds left open and allowed to heal by granulation.

Looking back on this method in the light of present-day knowledge it is apparent that Dupuytren's results must have been adversely affected by the fact that he was operating only upon very advanced cases, that he did not attempt to excise the diseased fascia, and that he did not appreciate the importance of early active movements in maintaining the circulation in the hand. In spite of these handicaps he must have achieved quite a measure of success.

To-day we have the advantages of the "bloodless field," safe anæsthesia for an indefinite period, antibiotics, and a better understanding of wound healing and skin tension. In spite of all this, post-operative complications still remain the commonest cause of failure or of a prolonged and painful convalescence.

In Dupuytren's contracture the shortening and puckering of the palm skin is often the first sign of the disease and is evident long before invasion of the tendon sheaths has led to a flexion contracture. When such skin has been dissected up it is found to have lost its normal elasticity and its vitality is therefore impaired. If it is split up into flaps it is liable to develop areas of marginal necrosis, especially if it is stretched by pressure from a hæmatoma, swollen with œdema, or pulled upon by active movements. Skin sloughs developing in this way are very susceptible to infection with its sequelæ of pain, muscle spasm, finger œdema, and joint stiffness.

In plastic surgery the generally recognised method of treating a flexion contracture due to scar contracture of the soft tissues over a major joint is first to carry out a thorough excision of the deep fibrosis along with the scarred skin, and only then, when the joint can be fully extended without tension, to proceed to cover the skin defect with either a free graft or a flap. If the dissection has exposed bare tendon or bone then full-thickness flap cover is preferred. The limb is then fixed with the joint extended for a long enough period to allow of sound healing before active movements are begun.

Dupuytren's disease is essentially a flexion contracture and one might think that the same principles of technique could be equally well applied in palmar fasciectomy. Unfortunately free grafts on the palm of the hand, even of full thickness as advocated by Kanavel *et al.* (1929), are not as satisfactory as those applied to the flexor aspect of the knee or elbow. In the first place, it is difficult in the palm to prevent serous effusion or hæmatoma and also in Dupuytren's contracture the graft is sutured to skin which is reduced in vitality by disease and by the dissection. If the graft does not take 100 per cent. the areas of necrosis

readily become infected. Then again to give the graft sufficient time to consolidate means that hand movements must be restricted for longer than a week. This in turn slows down the blood and lymph circulation and increases the tendency to static œdema. The other objection to a free graft in the palm is that it is not suitable where the dissection has exposed the flexor tendons by the removal of the tendon sheaths.

Recognizing these facts the surgeon has several alternative methods of repairing the skin shortage :—

1. Plan the incisions to close with " Z " plasties.
2. Transpose a flap from the dorsum.
3. When it is necessary to amputate a finger, use its filleted skin as a flap.
4. Simply close the palm incision with the fingers flexed and trust that finger extension can be restored by exercises after the wound has healed.

Each of these techniques has its place in suitable cases and can give good results, but yet another, the " open palm," can also give a high percentage of success with greater freedom from complications and less discomfort during convalescence.

#### PRINCIPLES OF THE OPEN PALM TECHNIQUE

1. By making the incisions as Dupuytren did in the transverse skin creases, each area of skin which is dissected up has a double blood supply and therefore is more resistant to infection and heals better.

2. By advancing the undermined skin bridge flaps proximally and distally with the fingers extended, the whole of the skin shortage is accepted by the main incision in the distal palmar crease which remains wide open. The other incisions close easily without tension and the central defect gives perfect drainage so that no hæmatoma can occur.

3. After a week's complete rest of the hand in a pressure dressing the patient must start to use the hand actively, and each night wear a splint which keeps the metacarpal-phalangeal joints extended.

4. By laying down a simple routine during convalescence the patient is able to treat himself at home without physiotherapy and the period of hospitalisation is reduced to only a few days. All that is necessary is for him to attend the " hand clinic " at weekly intervals.

**Operative Technique of " Open Palm."**—*Anæsthesia.*—General or brachial block.

*Hæmostasis.*—Pneumatic cuff and Esmarch bandage. After removal bleeding is arrested by pressure—no ligatures.

*Incisions.*—See Figure 1, A.

*Dissection.*—Only the diseased fascia, recognised by its tension and lack of normal lustre, is removed. Distally the dissection is not carried further than the proximal interphalangeal joints. It has been found that to go further than this point at the primary operation is liable to hamper the full use of the hand during convalescence as well as to increase the danger of digital nerve damage. In most cases the patients are quite satisfied with the improvement in function they have gained, but in those who insist on a completely straight finger, the intricate dissection which is required can be carried out at a later date under " digital block " anæsthesia.

*Skin Closure.*—With the fingers extended on the “lead hand” splint the actual skin shortage is apparent and is often much more than one would expect. The proximal and distal incisions are then sutured.

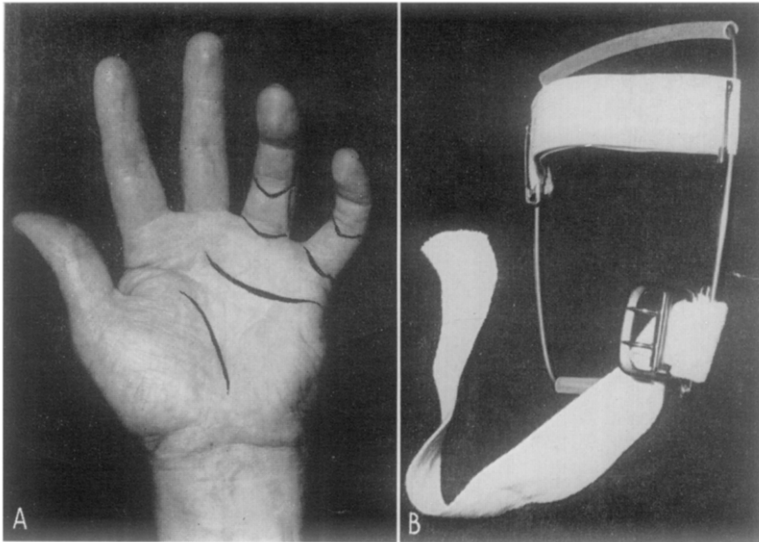
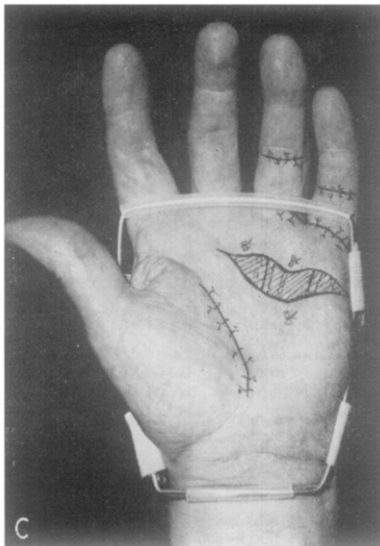


FIG. 1

A, *Incisions.* Note the convexity of the distal incisions. When the fingers are extended they will lie in the lines of the normal creases. B, *Night Splint.* Oblong frame of 2 mm. S.S. wire and polythene tubing which unites the cut ends of the wire. Elastic webbing, 1 in. wide, across dorsum of hand. Webbing strap and buckle across dorsum of wrist. C, The night splint allows ample room for a light dressing to cover the palm wound.



*The Skin Defect.*—The main incision in the distal palmar crease is now wide open with tendons and nerves exposed in its base. If its skin edges do not lie flatly and so leave spaces beneath, they are loosely tacked down with nylon mattress sutures (Fig. 1, C).

*The Dressing.*—The tourniquet is released and after bleeding has stopped the open wound is covered with one layer of tulle gras and a pad of polyvinyl

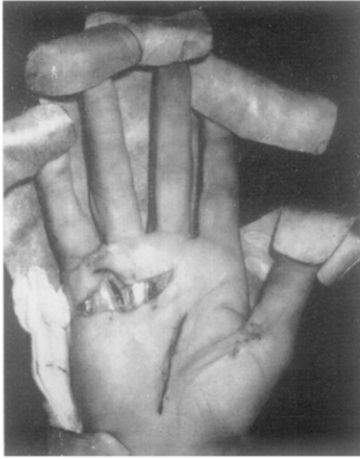

FIG. 2

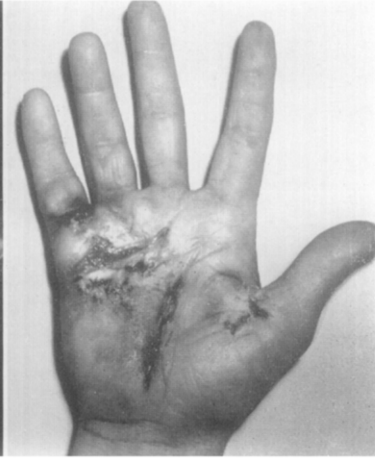

FIG. 3

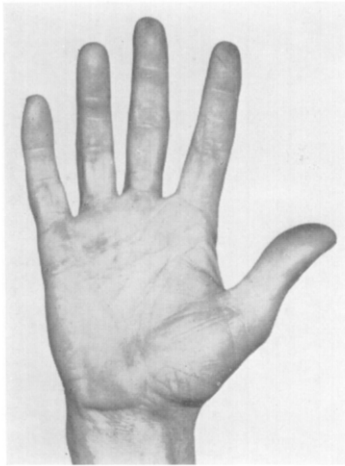


FIG. 4

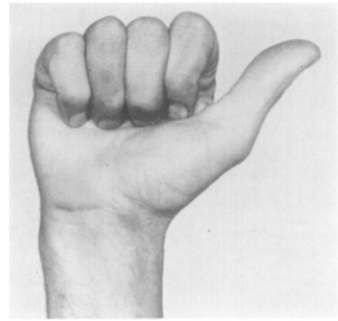


FIG. 5

Fig. 2.—Case 1. To illustrate natural healing of the "open palm" defect. Hand at operation.

Fig. 3.—Case 1. The same, fourteen days after operation.

Fig. 4.—Case 1. The same, five weeks after operation.

Fig. 5.—Case 1. The same as last.

sponge. Over this a firm pressure dressing to the entire hand is applied with a volar plaster of Paris slab pressed well against the palm as it sets.

*After Care.*—The arm is elevated in a sling. No antibiotics are given unless there is pyrexia. The patient goes home on the third day to attend as an out-patient on the seventh day.

*First Dressing.*—One week after the operation the hand is taken down completely. The base of the open wound is now covered with a thin layer of

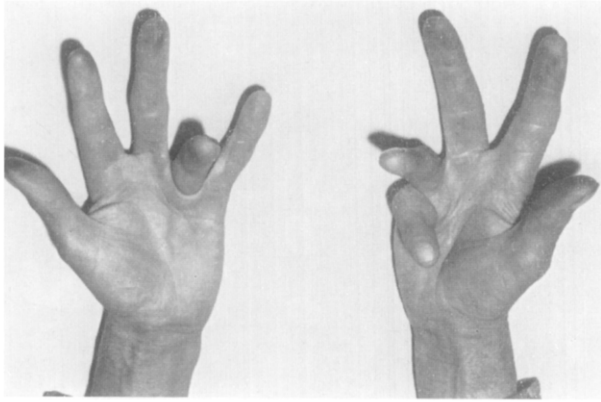


FIG. 6

Case 2. Bilateral contracture before operations. Both hands treated by "open palm" method.

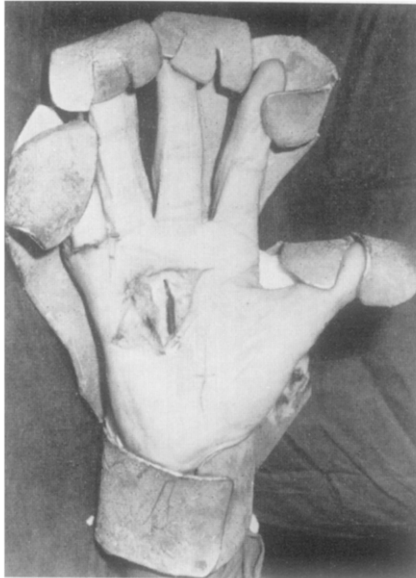

FIG. 7

Case 2. Right hand at operation.

granulations and the fingers can be moved actively without pain. A light non-adherent dressing is applied, sufficient to exclude dust infection but not to interfere with finger movements. The patient is instructed to use the hand for

every light duty that he can do—writing, typing, piano-playing, and very soon car driving. He is fitted with the extension splint (*see* Fig. 1, B and C) which goes over his dressing and which must be worn at night only.

*Subsequent Dressings.*—These are at weekly intervals. The open wound

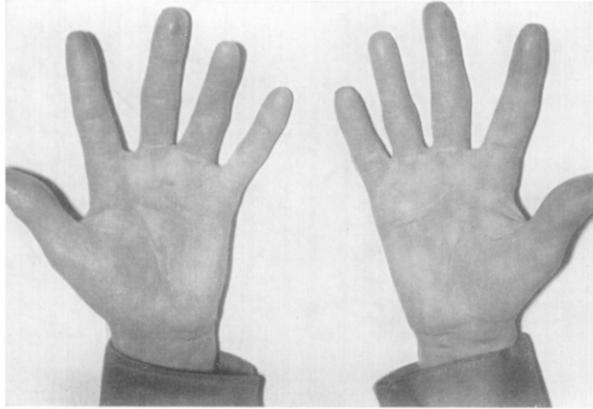


FIG. 8

Case 2. Right hand six months after operation. Left hand three months after operation.

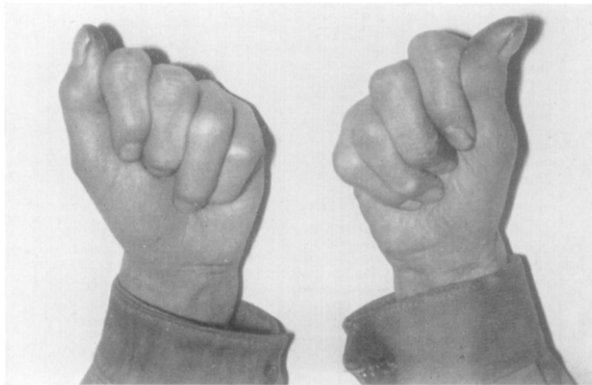


FIG. 9

Case 2. The same as last.

which heals by marginal epithelialisation is soon reduced to a narrow fissure and finally closed in from two to five weeks. The night splinting is kept up until the wound is completely healed. The rapidity with which the defect closes can be seen in Case 1 (Figs. 2, 3, 4, and 5).

*Illustrative Cases.*—Figures 6 to 9, 10 to 13, and 14 to 17 illustrate stages in the “open palm” technique.

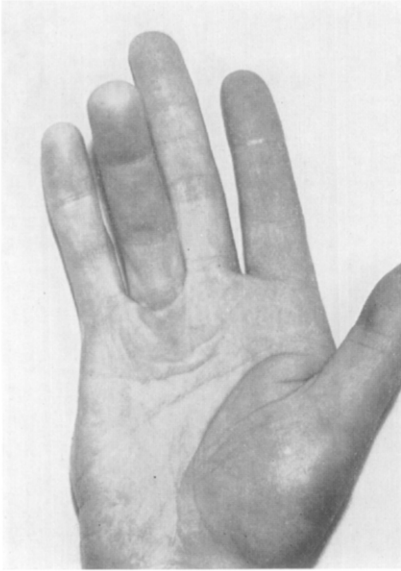


FIG. 10  
Case 3. Before operation.

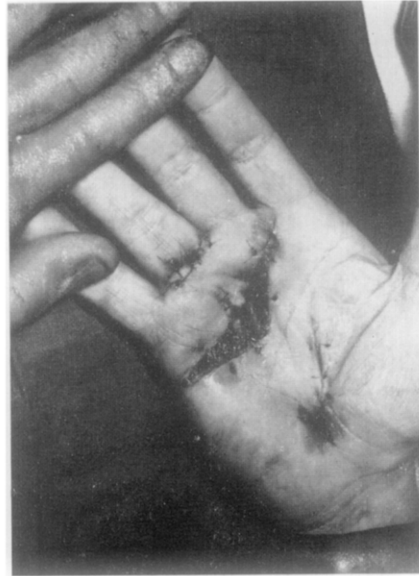

FIG. 11  
Case 3. The same, at operation.

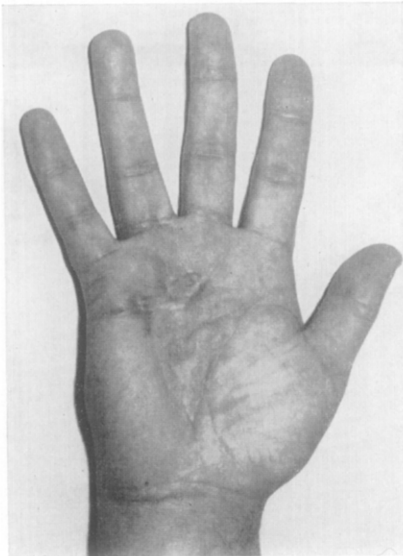


FIG. 12  
Case 3. The same, two months after operation.

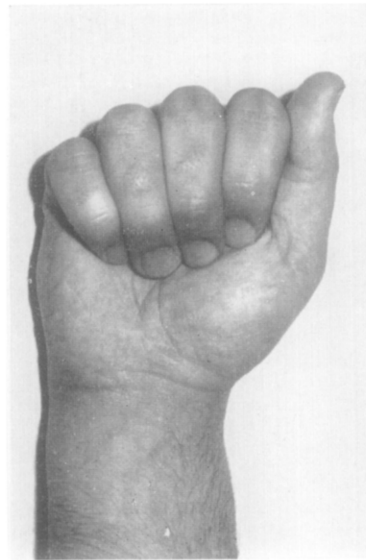


FIG. 13  
Case 3. The same as last.

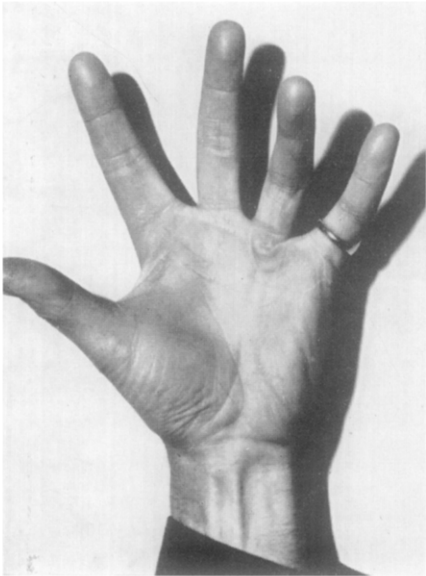


FIG. 14

Case 4. Before operation.

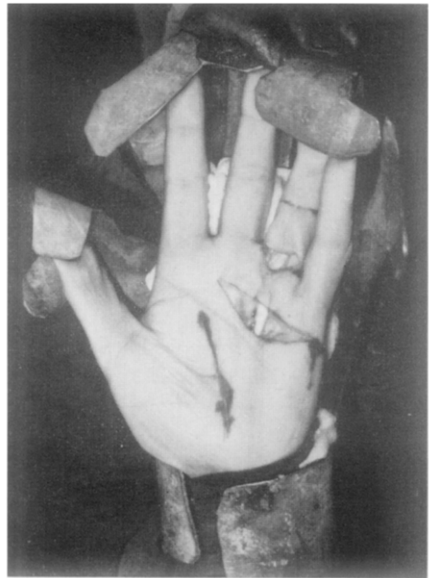

FIG. 15

Case 4. The same, at operation.

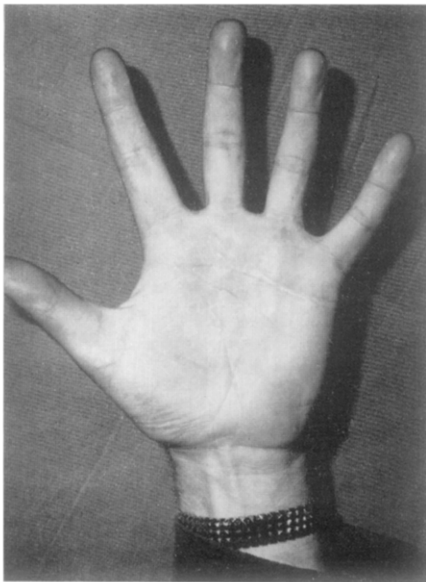


FIG. 16

Case 4. The same, eight months after operation.

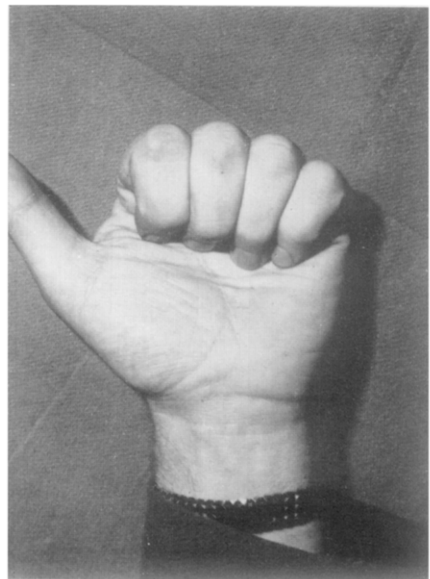


FIG. 17

Case 4. The same as last.

## DISCUSSION AND RESULTS

The "open palm" technique is presented as yet another way of overcoming the skin shortage in the operation of palmar fasciectomy. It fulfils the original principles laid down by Baron Dupuytren, modified, however, by the advances in technique which orthopædic and plastic surgeons have contributed to surgery of the hand.

This method is quite unsuitable for elderly patients with advanced secondary joint contractures and also in those who are unwilling or unable to co-operate in their own after-care.

It has been noticeable that in the past five years more patients are being referred by their doctors for treatment at an earlier stage of the disease while it is still confined to the palm. Whether or not this is a tribute to improved results, it does mean that they are of a younger age group, to whom a quick return of function is of more importance than in the elderly.

The open wound appears to cause very little discomfort while it is healing and the necessity of wearing a light dressing over it is a small price to pay for the greater freedom from stiffness and muscle spasm.

The main criticisms which have been levelled at this method by other surgeons who have not tried it are, first, that the open palm wounds are liable to infection and, secondly, that they are likely to leave severe scarring. This has not been my experience. Apart from two failures, only a very few cases have developed mild local infection, which rapidly subsided with Furacin dressings. A serous discharge from the wound is normally seen and this may well account for the remarkable freedom from œdema which is a feature of convalescence. As regards disfigurement by scarring, this is apparent only in the early stages and by the end of a year or less is no more noticeable than after fasciectomy by other techniques.

It has also been suggested that the wound must close by circumferential contracture. It is to prevent this that I insist on the patient continuing to wear a night splint until the wound is healed, and even if contracture does play a part in the healing process, it does not pull down the fingers, so is of no consequence.

Mr O. T. Mansfield, F.R.C.S., of Birmingham, in a personal communication reports that he has been employing a very similar method to my own for some years. The chief difference in his technique is that, by making up the skin shortage in the contracted fingers by "Z" plasties or free grafts, the open defect in the palm is not so wide. This he maintains makes for quicker healing, but, on the other hand, is not entirely free from the risk of hæmatoma.

In the past three years I have carried out sixty-three fasciectomies and forty-three have been "open palm" cases. In this series of forty-three there have been no hæmatomas. Good functional results have been obtained in all but two cases. Of these two failures, one was a man aged 76 and the other, though younger, was a patient who failed to co-operate in the after treatment. Five of the patients have had both hands operated on successively with equally satisfactory results.

## SUMMARY

Some degree of skin contracture in the palm is present in probably 90 per cent. of cases of Dupuytren's contracture. It is the flexion deformity of the

metacarpal-phalangeal joints which causes the greatest disablement and the primary object of the fasciectomy should be to release them. Such release cannot be complete unless there is sufficient palm skin to permit of their full extension. This can be ensured only by the addition of either a full-thickness skin flap or by a free graft, or by natural regeneration of the skin as in the "open palm" method. The "open palm" wound has certain advantages over skin grafts. It acts as an open drain to the palm preventing hæmatoma in the early post-operative phase and œdema during the later stage when active movements begin. It affords complete relaxation of the palm skin in the "extended" position and all the patient has to do is to restore the ability to flex his fingers. This he can do at home without physiotherapy.

#### REFERENCES

- DUPUYTREN, BARON (1833). *Lancet*, 2, 222.  
KANAVEL, A. B., KOCH, S. L., and MASON, M. (1929). *Surg. Gynec. Obstet.*, 48, 145.

Submitted for publication, August 1963.