



# Weave Technique for Reconstruction of Medial Collateral Ligament and Posterior Oblique Ligament: An Anatomic Approach Using Semitendinosus Tendon

Amit Joshi, M.S. (Ortho.), Nagmani Singh, M.S. (Ortho.), Sushil Thapa, M.S. (Ortho.), and Ishor Pradhan, M.S. (Ortho.)

**Abstract:** Medial collateral ligament (MCL) is the most commonly injured ligament in knee. The majority of MCL tears can be managed conservatively, and reconstruction or augmentation is required in few selected cases. **Anatomic MCL and posterior oblique ligament reconstruction have good functional outcome**, but it requires 2 tunnels each in the tibia and femur, which may be a limitation in cases in which multiligament reconstruction is required. Several studies report the use of semitendinosus tendon with intact tibial attachment for MCL reconstruction. **Since the attachment of semitendinosus is anterior to MCL footprint, it is non-anatomic and anisometric**, which may lead to increased laxity of the reconstructed ligament in due course of time. To prevent the laxity in long term, the reconstruction has to be isometric and anatomic. We, hereby, are reporting our unique technique of MCL and posterior oblique ligament reconstruction using intact semitendinosus at tibial attachment and re-routing to the MCL which makes the reconstruction anatomic and isometric. A supplemental video demonstration of the technique is attached with this article.

The medial collateral ligament (MCL) is the most commonly injured ligament of the knee. The majority of MCL tears can be managed conservatively, and reconstruction may be indicated in valgoid knee, grade III injuries, and multiligament injuries.<sup>1</sup> LaPrade and Wijdicks<sup>2</sup> mention that the anatomic reconstruction results in better stability after the MCL reconstruction.<sup>2</sup> However, the need of 2 tunnels each in tibia and femur has limited its use, especially in cases of multiple ligament reconstruction, and also the tibial fixation of the grafts remains a weak link. We, too, have experienced difficulty in fixing the graft on the tibial footprint of superficial

MCL, as the bone in this area is very hard, and fixation with a soft interference screw has led to complications such as graft cut out and difficulty in insertion, since these screws are designed to be used in cancellous bone.

Among several techniques mentioned in literature, the **use of semitendinosus tendon (SemiT) to reconstruct superficial medial collateral ligament (sMCL) and posterior oblique ligament (POL) is easy, as it does not require fixation in the tibia.**<sup>3,4</sup> However, anterior attachment of SemiT in relation to sMCL leads to **non-anatomic and anisometric reconstruction, which has been reported to have poorer outcome.**<sup>5</sup>

This led us to modify the technique described by Kim et al.<sup>3</sup> by **weaving the SemiT to tibial remnant of sMCL and reproducing anatomic MCL and POL reconstruction as mentioned by LaPrade and Wijdicks<sup>2</sup> but with only 2 fixation screws in 2 tunnels.** The aim of this paper is to sequentially explain our technique of anatomic sMCL and POL reconstruction using SemiT tendon with intact tibial attachment (**Video 1**).

## Surgical Technique

The patient is placed in the supine position, and a tourniquet is applied to the upper thigh. General or regional anesthesia is administered based on preference of patient and anesthetist. The operative knee is

From the Shree Birendra Hospital, Kathmandu (A.J.); B&B Hospital, Gwarko, Lalitpur (A.J., N.S., I.P.); and Bharatpur Hospital, Chitwan (S.T.) Nepal.

The authors report that they have no conflicts of interest in the authorship and publication of this article. Full ICMJE author disclosure forms are available for this article online, as [supplementary material](#).

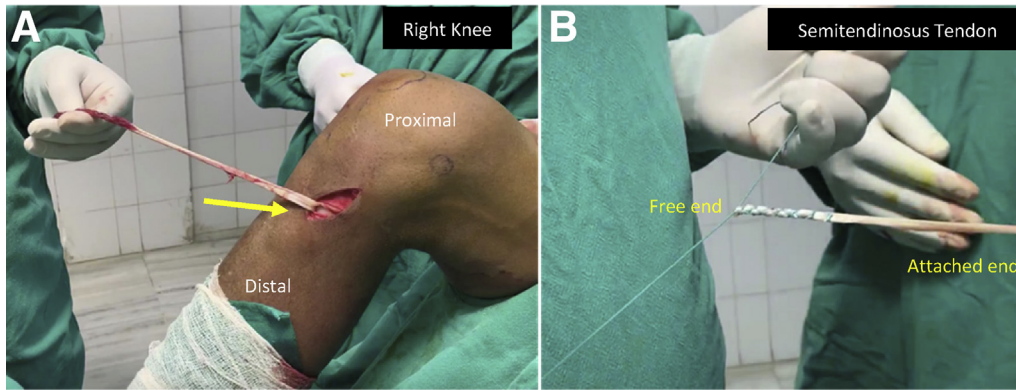
Received May 30, 2019; accepted July 18, 2019.

Address correspondence to Prof. Amit Joshi, M.S. (Ortho.), Shree Birendra Hospital, Kathmandu 44600, Nepal. E-mail: [dramitjoshi7@gmail.com](mailto:dramitjoshi7@gmail.com)

© 2019 by the Arthroscopy Association of North America. Published by Elsevier. This is an open access article under the CC BY-NC-ND license (<http://creativecommons.org/licenses/by-nc-nd/4.0/>).

2212-6287/19702

<https://doi.org/10.1016/j.eats.2019.07.018>



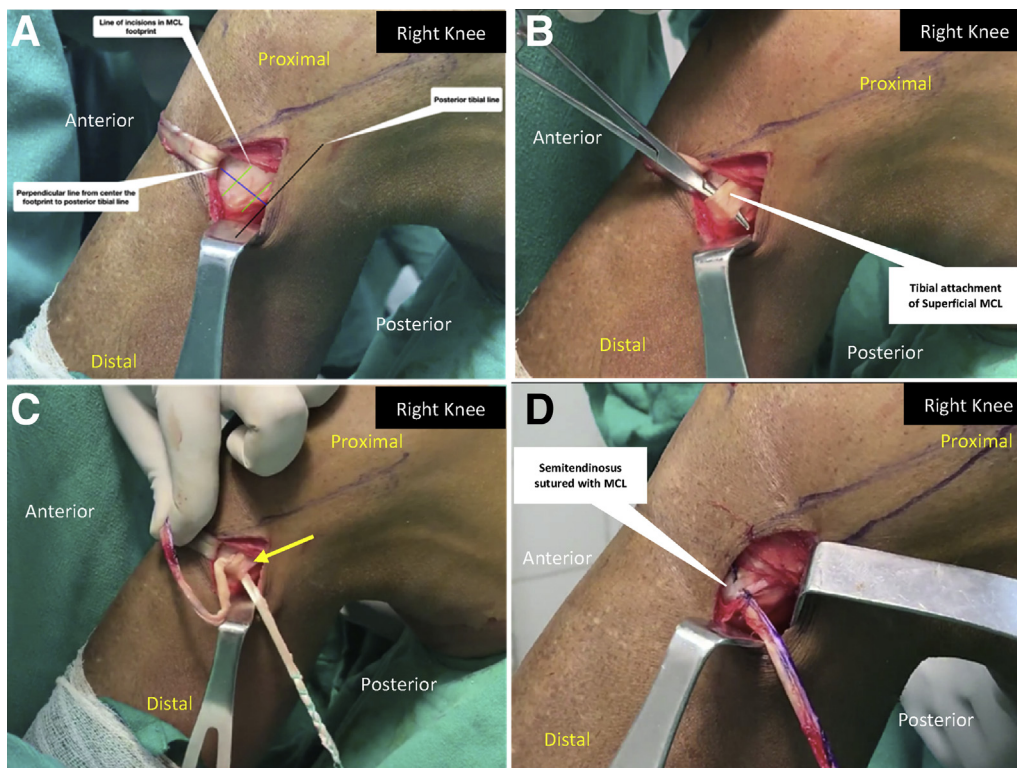
**Fig 1.** (A) A right knee is shown. The **semitendinosus tendon is harvested using an open-ended tendon stripper**, leaving the tibial attachment of tendon intact (arrow). (B) The harvested free end of the semitendinosus tendon is prepared and sutured using finger trap technique with ETHIBOND No. 2.

painted and draped. Patient is positioned with hip and knee flexed to 90° and held with lateral side post and foot support.

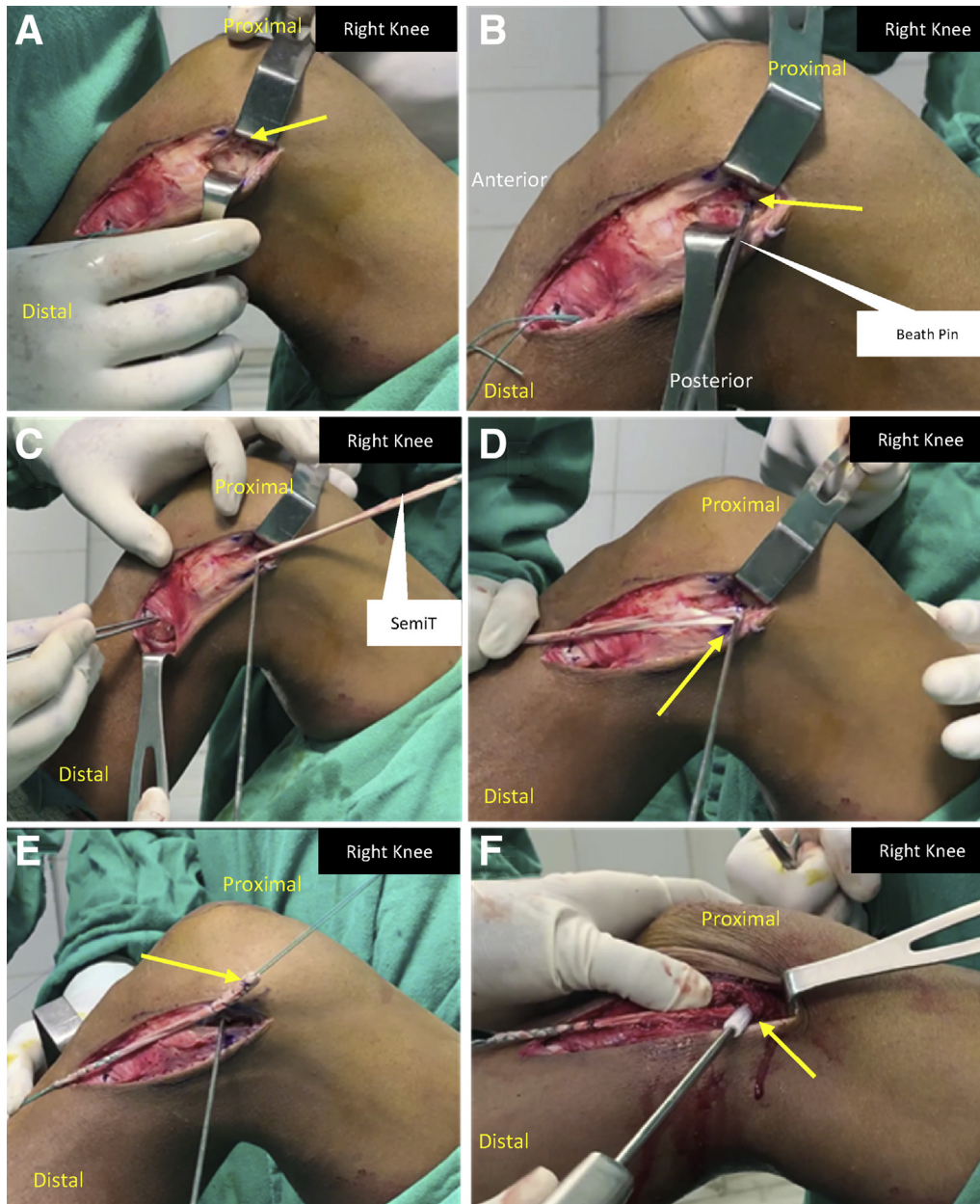
### Diagnostic Arthroscopy

A detailed diagnostic arthroscopy is performed with a 4-mm, 30° arthroscope through the anterolateral portal. Associated injuries are identified and

adequately managed by making additional portals. The abnormal medial joint line opening is confirmed by applying valgus stress to the knee and drive-through sign. The joint opening is measured and confirmed on an image taken with image intensifier. The tip of the probe is used to estimate the preoperative joint opening through an anteromedial portal and applying the valgus stress.



**Fig 2.** A right knee is shown. (A) Landmarks for **vertical incision at sMCL tibial footprint** (Black line: a line drawn along the posterior border of tibia; Blue line: a line drawn perpendicular to the black line from the center of the SemiT footprint; Green lines: 2 parallel lines drawn 1 cm apart perpendicular to the blue line with posterior green line being drawn along the posterior edge of tibia). (B) **A 1-cm long incision is given on 2 parallel green lines and sMCL is elevated by passing a curved mosquito forceps to create a subperiosteal tunnel.** (C) The graft is passed through the subperiosteal tunnel from anterior to posterior. (Arrow: sMCL with graft passed underneath through the subperiosteal tunnel). (D) **The graft following passage through the tunnel is sutured to the sMCL at superior edge of the tunnel.** (SemiT, semitendinosus tendon; sMCL, superficial medial collateral ligament.)



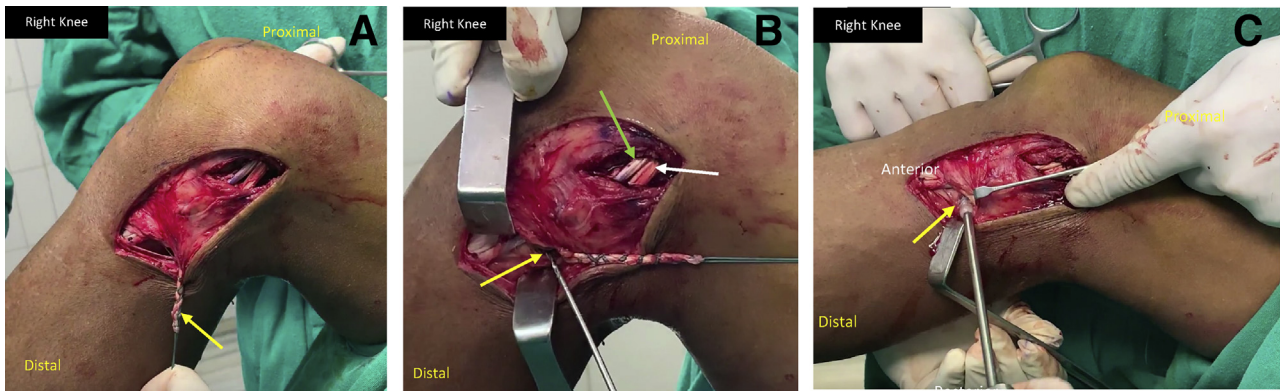
**Fig 3.** A right knee is shown. (A) Incision is extended after weaving the hamstring to sMCL and medial epicondyle is identified and exposed as shown by arrow. (B) A Beath pin is passed from the point 3.2 mm proximal and 4.8 mm distal to the medial epicondyle (arrow) on the medial side which exits on anterolateral cortex of the distal femur. (C) Following insertion of the Beath pin, previously weaved hamstring graft is passed underneath the sartorial fascia and brought out at the femoral footprint. (D) The graft is looped around the Beath pin and marked with a marker at the looping site. Then, the range of motion is performed to check for significant movement of marked point with respect to Beath pin to confirm isometry. (Arrow shows the SemiT graft looped around the Beath pin.) (E) After confirming the isometry, tubularization of the looped graft is preformed to the preferred length, which is to be inserted in the femoral tunnel. (Arrow shows the tubularized end, which is sutured with 2-0 polyglactin suture.) (F) After the drilling of femoral tunnel to the desired diameter, the tubularized graft is inserted into the femoral tunnel and fixed with a biodegradable interference screw of one size bigger diameter than the drilled femoral tunnel. (Arrow shows fixation of inserted graft with interference screw.) (SemiT, semitendinosus tendon; sMCL, superficial medial collateral ligament.).

### Steps

The MCL weave technique of MCL and POL reconstruction is performed in 4 definitive steps; SemiT harvest, graft weaving, fixation in femur, and POL reconstruction. The details of these steps are described to follow.

#### Step 1: SemiT Harvest and Preparation

The course of the hamstring tendon and medial femoral epicondyle are marked. An oblique incision centered over the hamstring tendons, slightly posterior to the midpoint between tibial tuberosity and posterior



**Fig 4.** A right knee is shown. (A) Following the fixation of the graft at the femoral site, the free end of the graft is brought back through the same tissue plane, underneath the sartorial fascia, which was used to pull the graft to femoral insertion site. (Arrow shows the pulled back free end of the hamstring graft.) (B) Tibial attachment of posterior oblique ligament (POL) is identified (yellow arrow), and a Beath pin is drilled, aiming toward the Gerdy tubercle. Then, the tunnel is drilled to a required diameter with a reamer up to 6 mm diameter. (Green arrow: reconstructed sMCL; white arrow: reconstructed POL.) (C) A right knee is shown. The graft end used to reconstruct the POL is pulled through the drilled tibial tunnel at anatomic location of POL, and fixed with a 7-mm biodegradable interference screw. (Arrow: interference screw fixation of the graft into tibial tunnel.) (sMCL, superficial medial collateral ligament.)

border of tibia, is given. The SemiT and gracilis tendon is identified by finger palpation once sartorial fascia is reached. A horizontal incision is given on sartorial fascia between these 2 tendons, and semitendinosus is isolated and freed from interconnection bands and vincula.

Once the SemiT is free (as judged by smooth tendon excursion), an open-ended stripper (Smith & Nephew, Andover, MA) is used to harvest it with intact tibial attachment (Fig 1A), and the muscles fibers attached to the free end are removed and cleaned. The graft end is sutured with finger trap technique using No. 5 ETHIBOND (Ethicon, Somerville, NJ) (Fig 1B).

### Step 2: Graft Weaving

After clearing the footprint of SemiT, 2 vertical incisions are made about 8 to 10 mm apart and 1 to 1.5 cm long in the footprint of MCL, centering over the line drawn perpendicular to the posterior tibial line drawn from the center of semitendinosus footprint (Fig 2A). Subperiosteal elevation of the MCL insertion is performed with a curved mosquito forceps passed through anterior incision to posterior to create a soft-tissue tunnel, and a shuttle suture is held in loop with the tip of the mosquito forceps (Fig 2B). Then the shuttle suture is used to deliver the SemiT underneath the MCL insertion through the tunnel (Fig 2C) and weaved to it with 2-0 polyglactin suture (Fig 2D).

### Step 3: Fixation in Femur

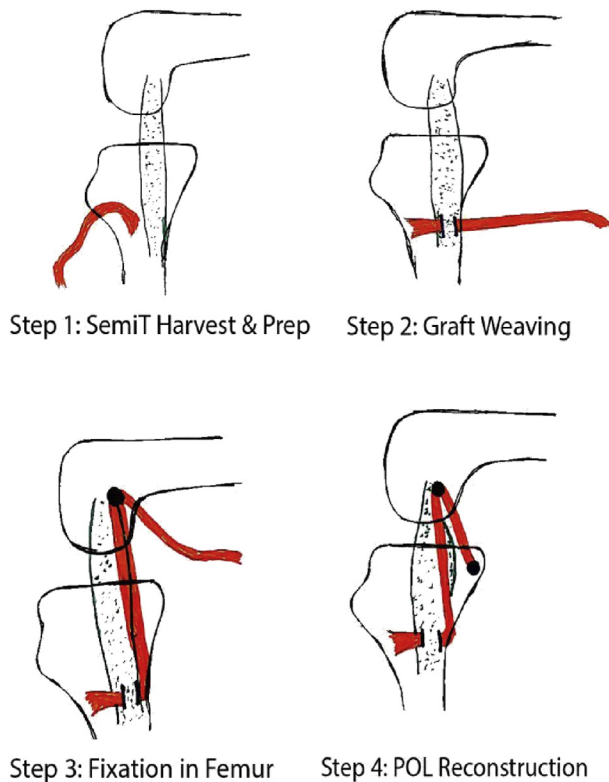
Following weaving, the incision of graft harvest is extended in a curvilinear fashion up to the medial epicondyle, and the epicondyle is exposed (Fig 3A). A point that is 3.2 mm proximal and 4.8 mm posterior to the medial epicondyle is marked. A Beath pin (Smith &

Nephew) is passed proximally and anterolaterally from this point to exit from the anterolateral cortex (Fig 3B). The direction of Beath pin can be adjusted depending on the tunnels in the femur in case of multiligament reconstruction, to avoid tunnel convergence. Using a shuttle suture, the weaved SemiT is passed underneath the sartorial fascia, exiting near the Beath pin insertion site (Fig 3C). Then the SemiT graft is looped around the Beath pin, and marked at the loop. The isometry is confirmed by performing knee range of motion (ROM) and checking the displacement of the marked point (Fig 3D). If the mark remains unmoved during the ROM, the isometric point is confirmed for femoral tunnel placement. In case there is excessive movement of the mark is seen, the insertion of the Beath pin has to be changed since it is anisometric. At this point, help of image intensifier can be taken to locate the epicondyle and the isometric point.

Once the isometric point is confirmed, then the graft is looped around itself and whipstitched, for about 2.5 cm (Fig 3E) to tabularize it. The size of the tabularized graft is measured with an anterior cruciate ligament (ACL) sizer. A femoral tunnel is created over the Beath pin, based on the size of tabularized graft, by drilling up to 30 mm in femur. Then a suture is shuttled, and the thread in which the graft is looped, is pulled through the tunnel. The graft is fixed in the tunnel using a biodegradable screw (BIORCI; Smith & Nephew), which is one size bigger than the tunnel diameter at 30° of knee flexion and varus stress (Fig 3F).

### Step 4: POL Reconstruction

After completing Step 3, the free end of the graft is re-shuttled underneath the sartorial fascia towards the tibia (Fig 4A). The attachment site of POL was identified



**Fig 5.** A right knee is drawn. Diagrammatic representation of surgical steps of our technique has been demonstrated in the figures. Red color represents the sequential course of SemiT in our technique. (POL, posterior oblique ligament; SemiT, semitendinosus tendon.)

at the posteromedial tibia, which is just anterior to the direct arm attachment of the semimembranosus tendon. A Beath pin is inserted just anterior to the direct fibers (from posterior to anterior) exiting near the

Gerdy tubercle (Fig 4B). A 6-mm cannulated reamer is used to make a tunnel over the Beath pin. The length of the tunnel is determined by the remaining length of the SemiT graft. Graft fixation is done with a 7-mm biodegradable screw (BIORCL, Smith & Nephew) in 30° of knee flexion (Fig 4C). The aforementioned technique has been depicted in schematic view (Fig 5; Step 1-4).

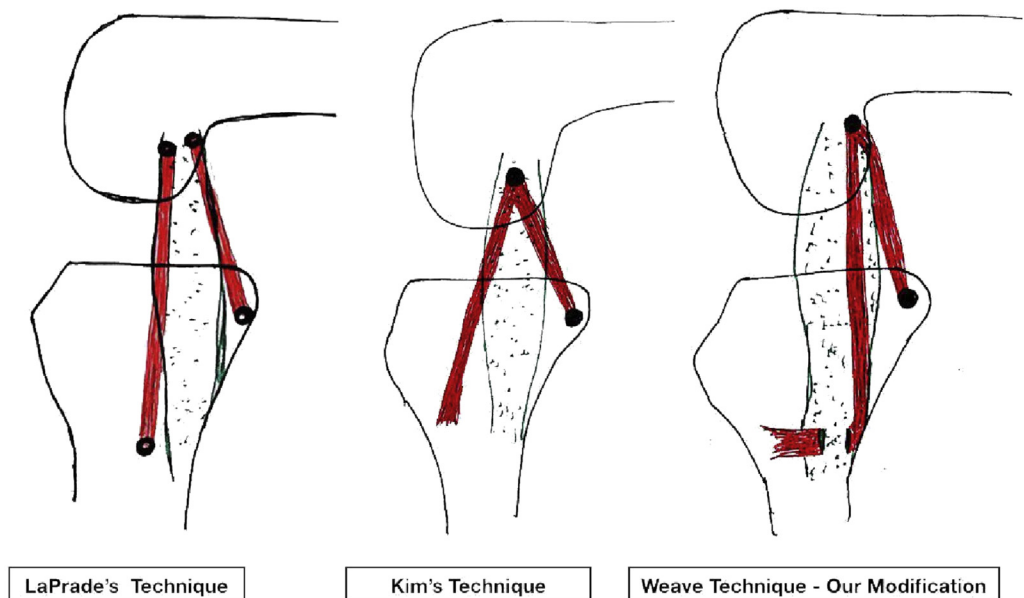
### Postoperative Protocol and Rehabilitation

The wound is inspected on second, 4th, 9th and 14th postoperative day. Sutures are removed on 14th postoperative day. A hinged knee brace is used for 4 weeks postsurgery. Isometric exercises of knee are started as soon as pain is tolerable. Cryotherapy is provided with ice packs for 3 weeks. Knee ROM is started immediately based on pain tolerance. 90° of knee ROM is achieved within 2 weeks and increased to 120° at 4 weeks. The full range is achieved by 6 weeks postsurgery. Hinged knee brace is applied during the knee ROM exercises. Toe-touch walking with crutches is allowed for the first 4 weeks postsurgery and gradually progressed to achieve full weight-bearing walking without crutches next 2 weeks. Strengthening exercises are continued up to 6 months postsurgery. Sports-specific exercises are started at 6 months, and return to sports is allowed after 9 months of surgery. The aforementioned protocol is modified and individualized based on other injured associated structures in the knee.

### Discussion

The indications of MCL reconstruction surgery are expanding and evolving. In a study by Bollier and Smith,<sup>6</sup> it is mentioned that both MCL and ACL healing is inappropriate if MCL is managed conservatively after

**Fig 6.** A right knee is drawn. Comparison of LaPrade's, Kim's, and our Weave technique is shown in schematic view. Red lines demonstrate the graft orientation in various surgical techniques.



**Table 1.** Pearls and Pitfalls of This Technique

Pearls	Pitfalls
<ul style="list-style-type: none"> <li>• Autologous SemiT graft is used, which avoids problems associated with allografts.</li> <li>• Tibial attachment of SemiT is left intact and hence does not require fixation on tibial side.</li> <li>• Tibial-side fixation with implants not needed for sMCL</li> <li>• Weaving of SemiT through soft-tissue tunnel at sMCL footprint at tibia recreates native sMCL attachment.</li> <li>• Graft is placed underneath the sartorial fascia.</li> <li>• Graft is fixed at femoral attachment as recommended for anatomic reconstruction of sMCL and isometricity is also ensured.</li> <li>• POL is also reconstructed with same autograft at its anatomic insertion point at tibia.</li> <li>• This technique can also be performed with separate mini-incisions at femur and tibia.</li> </ul>	<ul style="list-style-type: none"> <li>• Minimum of 20 mm of SemiT length is required.</li> <li>• In female patients, SemiT is very thin and may be considered weak to be used for reconstruction.</li> <li>• Although sMCL is attached at anatomical location on both the tibia and femur, the POL at femur is not at precise anatomical location.</li> <li>• Deep MCL is not reconstructed.</li> <li>• Procedure cannot be performed in cases of MCL avulsion from its tibial attachment.</li> </ul>

MCL, medial collateral ligament; POL, posterior oblique ligament; SemiT, semitendinosus tendon; sMCL, superficial medial collateral ligament.

ACL reconstruction. They recommended simultaneous reconstruction of ACL and MCL in case of chronic injury to both the ligaments. Zhang et al.<sup>7</sup> reported that the simultaneous ACL and MCL reconstruction had better outcomes, and they recommended simultaneous ACL and MCL reconstruction rather than the nonoperative management for MCL. In a systematic review of 10 studies with 275 knees, Varelas et al.<sup>8</sup> mentioned that only 17% required isolated MCL reconstruction compared to 83% requiring combination of surgeries along with MCL reconstruction. Thus, an MCL tear has to be addressed in the treatment plan for multiligament injuries. Due to an increase in high-velocity injuries, the incidence of multiligament injury will increase in future. Similarly, increasing trend of MCL reconstruction even in grade II MCL injuries associated with ACL tears will increase the number of MCL reconstructions in future. We need a technique that is simple with fewer complications yet anatomical to provide adequate stability. Our technique meets the aforementioned requirements of posteromedial reconstruction surgeries.

In their research, Kim et al.<sup>3</sup> mentioned good-to-excellent outcomes, with 92% of their patients having less than 3 mm of valgus opening, at an average follow-up of 52 months. Although Lind et al.<sup>9</sup> and Stannard et al.<sup>10</sup> also reported good subjective outcomes with their similar techniques, only 50% of Lind's, and 32% of

Stannard's patients had valgus opening less than 3 mm at an average follow up of 40 months. This may be attributed to the fact that the fixation of the graft anteriorly at the SemiT insertion was non-anatomic, anisometric, which led to significantly greater change in graft length and resulted in clinical laxity overtime, as mentioned by Feeley et al.<sup>5</sup>

In contrast, LaPrade and Wijdicks<sup>2</sup> performed anatomic reconstruction with 2 separate grafts for ACL and POL and found that 100% of their patient had less than 3 mm opening at an average follow-up of 18 months. However, the major drawback of anatomic reconstruction of the posteromedial corner, described by LaPrade, is that it requires 3 separate grafts and 2 tunnels each in femur and tibia, which may be a limitation in multiligament settings, as there is high chance of tunnel convergence. Apart from the aforementioned limitation, we have experienced a frequent graft amputation at tibial fixation site of sMCL even with a biodegradable screw, which one size smaller than the tibial tunnel diameter. Moreover, LaPrade's technique requires 4 fixation implants (2 in femur and 2 in tibia), which may lead to more implant-related complications and increased overall cost of the surgery.

In our technique, we have tried to replicate tibial attachment anatomy by weaving the SemiT graft to the tibial remnant of MCL, and femoral anatomy by fixing

**Table 2.** Advantages and Disadvantages of the Weave Technique

Advantages	Disadvantages
<ul style="list-style-type: none"> <li>• Only 1 tunnel in tibia and 1 in femur to reproduce both sMCL and POL.</li> <li>• Anatomic reconstruction of sMCL on both tibia and femur.</li> <li>• Less number of implants required and implant related complications.</li> <li>• Cost-effective.</li> </ul>	<ul style="list-style-type: none"> <li>• Size of the SemiT may be inadequate in some cases.</li> <li>• POL anatomy (on femoral side) is not reproduced.</li> </ul>

POL, posterior oblique ligament; SemiT, semitendinosus tendon; sMCL, superficial medial collateral ligament.

the graft at anatomic location of sMCL attachment, as described by LaPrade and Wijdicks.<sup>2</sup> We presume that the outcome should be comparable with the anatomic reconstruction mentioned by LaPrade Wijdicks.<sup>2</sup> Early outcomes with our technique are encouraging, and we are conducting a prospective cohort study on this technique. A comparison between LaPrade's, Kim's, and our technique is diagrammatically represented in Figure 6.

Although our technique is simple and reproducible, it has some pitfalls and disadvantages. The advantages and disadvantages and pearls and pitfalls of this technique are summarized in Tables 1 and 2, respectively.

## References

1. Wijdicks CA, Griffith CJ, Johansen S, Engebretsen L, LaPrade RF. Injuries to the medial collateral ligament and associated medial structures of the knee. *J Bone Joint Surg Am* 2010;92:1266-1280.
2. LaPrade RF, Wijdicks CA. Surgical technique: Development of an anatomic medial knee reconstruction. *Clin Orthop Relat Res* 2012;470:806-814.
3. Kim S-J, Lee D-H, Kim T-E, Choi N-H. Concomitant reconstruction of the medial collateral and posterior oblique ligaments for medial instability of the knee. *J Bone Joint Surg Br* 2008;90:1323-1327.
4. Madonna V, Screpis D, Condello V, et al. A novel technique for combined medial collateral ligament and posterior oblique ligament reconstruction: Technical note. *Knee Surg Sports Traumatol Arthrosc* 2015;23:2814-2819.
5. Feeley BT, Muller MS, Allen AA, Granchi CC, Pearle AD. Isometry of medial collateral ligament reconstruction. *Knee Surg Sports Traumatol Arthrosc* 2009;17:1078-1082.
6. Bollier M, Smith PA. Anterior cruciate ligament and medial collateral ligament injuries. *J Knee Surg* 2014;27:359-368.
7. Zhang H, Sun Y, Han X, et al. Simultaneous reconstruction of the anterior cruciate ligament and medial collateral ligament in patients with chronic ACL-MCL lesions: A minimum 2-year follow-up study. *Am J Sports Med* 2014;42:1675-1681.
8. Varelas AN, Erickson BJ, Cvetanovich GL, Bach BR. Medial collateral ligament reconstruction in patients with medial knee instability: A systematic review. *Orthop J Sports Med* 2017;5. 2325967117703920.
9. Lind M, Jakobsen BW, Lund B, Hansen MS, Abdallah O, Christiansen SE. Anatomical reconstruction of the medial collateral ligament and posteromedial corner of the knee in patients with chronic medial collateral ligament instability. *Am J Sports Med* 2009;37:1116-1122.
10. Stannard JP, Black BS, Azbell C, Volgas DA. Posteromedial corner injury in knee dislocations. *J Knee Surg* 2012;25:429-434.